This is a digital copy of a book that was preserved for generations on library shelves before it was carefully scanned by Google as part of a project to make the world's books discoverable online.

It has survived long enough for the copyright to expire and the book to enter the public domain. A public domain book is one that was never subject to copyright or whose legal copyright term has expired. Whether a book is in the public domain may vary country to country. Public domain books are our gateways to the past, representing a wealth of history, culture and knowledge that's often difficult to discover.

Marks, notations and other marginalia present in the original volume will appear in this file - a reminder of this book's long journey from the publisher to a library and finally to you.

Usage guidelines

Google is proud to partner with libraries to digitize public domain materials and make them widely accessible. Public domain books belong to the public and we are merely their custodians. Nevertheless, this work is expensive, so in order to keep providing this resource, we have taken steps to prevent abuse by commercial parties, including placing technical restrictions on automated querying.

We also ask that you:

+ *Make non-commercial use of the files* We designed Google Book Search for use by individuals, and we request that you use these files for personal, non-commercial purposes.
+ *Refrain from automated querying* Do not send automated queries of any sort to Google's system: If you are conducting research on machine translation, optical character recognition or other areas where access to a large amount of text is helpful, please contact us. We encourage the use of public domain materials for these purposes and may be able to help.
+ *Maintain attribution* The Google "watermark" you see on each file is essential for informing people about this project and helping them find additional materials through Google Book Search. Please do not remove it.
+ *Keep it legal* Whatever your use, remember that you are responsible for ensuring that what you are doing is legal. Do not assume that just because we believe a book is in the public domain for users in the United States, that the work is also in the public domain for users in other countries. Whether a book is still in copyright varies from country to country, and we can't offer guidance on whether any specific use of any specific book is allowed. Please do not assume that a book's appearance in Google Book Search means it can be used in any manner anywhere in the world. Copyright infringement liability can be quite severe.

About Google Book Search

Google's mission is to organize the world's information and to make it universally accessible and useful. Google Book Search helps readers discover the world's books while helping authors and publishers reach new audiences. You can search through the full text of this book on the web at `http://books.google.com/`

LANE MEDICAL LIBRARY STANFORD
J57 .T454 1873 STOR
A practical guide for making post-mortem
24503413100

LANE

MEDICAL LIBRARY

LEVI COOPER LANE FUND

LIBRARY
OF
COOPER MEDICAL COLLEGE
DATE Sept 1904
NO. 5614 CLASS 14
~~GIFT OF~~
Purchase

NS,

OR

Artistic

PHIA :
STREET.

LANE

MEDICAL LIBRARY

LEVI COOPER LANE FUND

LIBRARY

OF

COOPER MEDICAL COLLEGE

DATE Sept 1904

NO. 5614 CLASS 14

GIFT OF

Purchase

A

PRACTICAL GUIDE

FOR MAKING

POST-MORTEM EXAMINATIONS,

AND FOR THE STUDY OF

MORBID ANATOMY,

WITH

DIRECTIONS FOR EMBALMING THE DEAD, AND FOR THE PRESERVATION OF SPECIMENS OF MORBID ANATOMY.

BY

A. R. THOMAS, M. D.

Professor of Anatomy in the Hahnemann Medical College of Philadelphia; Lecturer on Artistic Anatomy in the Pennsylvania Academy of Fine Arts, and Philadelphia School of Design; Member of the American Institute of Homœopathy; General Editor of American Journal of Homœopathic Materia Medica, Etc., Etc.

FOR SALE BY

BOERICKE & TAFEL,

NEW YORK: No. 145 GRAND STREET. | PHILADELPHIA: No. 635 ARCH STREET.

1873.

7.

Entered according to Act of Congress, in the year 1873, by

A. R. THOMAS, M. D.,

In the Office of the Librarian of Congress at Washington.

LANE LIBRARY

JAMES E. KRYDER,
PRINTER,
32 SOUTH SEVENTH STREET,
PHILADELPHIA.

U57
T454
1873

PREFACE.

THE following work has been prepared with a view of supplying a want, the existence of which has long been felt by the author, both in his private practice and public teaching. No pretension is made of offering a complete work on Morbid Anatomy, the object having been, merely to present the practitioner and student with a practical guide for making post-mortem examinations, to give them hints as to what they are to look for in such cases, and, finally, to aid them in recognizing the various morbid appearances as they are exposed to view.

The work is divided into four parts. Parts I, II and III, corresponding to the three great divisions of the body—the Head, Chest and Abdomen. Part IV, is devoted to miscellaneous subjects, and contains chapters on the Bones; Joints; Tumors; Effects of Poisons; Medico-Legal Autopsies; On Embalming the Dead; and On the Preservation of Morbid Specimen.

A few illustrative cases have been introduced, and occasional reference made to morbid specimens in the Museum of the Hahnemann College.

The following works have been consulted in the preparation of the book, and as few references have been made, this general credit is felt to be due the several sources of information: Rokitansky's, Craigie's, Jones

and Sievecking's, and Green's Pathological Anatomy; Rindfleish's Pathological Histology; Paget's Surgical Histology; Raue's Pathology; Murchison, on the Liver; Hope, on the Heart; Brinton, on the Stomach; Stewart, on the Kidney; Gross' Surgery; Christison on Poisons; Casper and Taylor's Medical Jurisprudence.

Acknowledgment should here be made of the valuable assistance rendered by Drs. W. H. Bigler and John N. Mitchell, in carrying the work through the press; and of the kindness of Mr. J. H. Gemrig, in the loan of the electrotype plates which embellish the preliminary chapter.

Conscious that the work is not without defects, it is still presented to the profession, with the hope that it may be found to answer the purpose for which it was designed.

A. R. THOMAS,
937 *Spruce Street.*

MARCH, 1873.

CONTENTS.

PAGE.

PREFACE, ...

INTRODUCTION, ... 17

PRELIMINARY CHAPTER.

Instruments and General Directions. . . 21

PART I.

THE HEAD AND SPINE.

CHAPTER I.

THE OPERATION.

On the Head and Spine, ... 27

CHAPTER II.

PATHOLOGICAL CONDITIONS.

SECTION I.—OF THE SKULL, ... 34

Fracture; Caries; Thinning; Increased Thickness, 35

SECTION II.—THE MEMBRANES OF THE BRAIN.

1. *The Dura Mater*, ... 36

Inflammation; Thickening; Fibrinous Clots, . 37

Tubercular Deposits; Tumors, . . . 38

2. *Arachnoid and Pia Mater.*

Pacchionian Bodies; Inflammation; Serous Effusions; Sanguineous Effusions, ... 38

SECTION III.—OF THE BRAIN.

What to notice; Inflammation; Softening; Abscess; Hardening; Hypertrophy; Atrophy; Tumors of

the Brain; Adenoid Tumors; Scrofulous Tumors; Adipose Tumors; Cholesteroma; Cartilaginous Tumors; Calcareous Deposits; Encysted Tumors; Blood Cysts; Cancer; Melanosis; Syphilitic Tumors; Obstruction of Arteries; Degeneration and Calcification of Arteries, ... 47

SECTION IV.—OF THE SPINAL CORD.

1. *The Membranes.*
Inflammation; Tubercular Deposits; Serous Effusion, 60

2. *Spinal Marrow.*
Inflammation; Softening; Hardening; Atrophy; Morbid Growths, ... 62

PART II.

THE NECK AND CHEST.

CHAPTER I.

OPERATION ON THE NECK AND CHEST.

CHAPTER II.

PATHOLOGICAL CONDITIONS OF THE ORGANS.

SECTION I.—OF THE TONGUE.
Cancer; Syphilitic Ulcer; Tumors; Ranula; Hypertrophy, ... 68

SECTION II.—OF THE LARYNX AND TRACHEA.
Inflammation; Ulceration; Œdema; Necrosis of Cartilages; Abscess; Tumors; False Membranes, 69

SECTION III.—OF THE PHARYNX AND ŒSOPHAGUS.
Inflammation; Ulceration; Stricture; Dilatation; Tumors, ... 72

SECTION IV.—OF THE PERICARDIUM.
Inflammation; Adhesions; Effusions; Morbid Growths, 73

SECTION V.—OF THE HEART.

1. *Inflammatory Affection.*
   Pericarditis; Endocarditis, . . . 76
2. *Valvular Affection.*
   Thickening; Calcification; Atrophy, . . 77
3. *Changes Affecting Size.*
   Hypertrophy; Dilatation; Atrophy, . . 79
4. *Morbid Condition of the Walls.*
   Fatty Degeneration, ... 82
5. *Morbid Growths.*
   Tumors; Cancer; Melanosis; Hydatids; Ossification of Coronary Arteries; Abscess; Malformations; Aneurism; Rupture, ... 84
6. *Displacements.*
   Ectopia Cordis; Transposition, . . . 87
7. *Contents of Cavities.*
   Heart Clots, ... 88

SECTION VI.—THE AORTA AND ARTERIES GENERALLY.

Inflammation; Fatty Degeneration; Ossification; Aneurism; Rupture, ... 98

SECTION VII.—OF THE PLEURA.

Inflammation; Plastic Effusion; Adhesions; Serous Effusion; Sero-Purulent Effusions; Pneumothorax, 103

SECTION VIII.—OF THE LUNGS AND BRONCHIAL TUBES.

Pneumonia; Congestion; Red Hepatization; Gray Hepatization; Suppuration and Abscess; Metastatic Abscess; Gangrene; Pulmonary Hæmorrhage; Pulmonary Apoplexy; Emphysema, . . 106

Tubercular Disease of the Lungs, . . . 117

Post-mortem Appearances in, ... 118

Morbid Growths.
Cancer; Melanosis; Hydatids, . . . 120

The Bronchial Tubes.
Bronchitis; Narrowing of; Dilatation of, . 123

The Mediastinum.
Inflammation; Abscess; Tumors, . . 126

PART III.

THE ABDOMEN AND PELVIS.

CHAPTER I.

THE OPERATION, ... 127

CHAPTER II.

PATHOLOGICAL CONDITIONS OF THE PERITONEUM AND ALIMENTARY TRACT.

SECTION I.—OF THE PERITONEUM.

Congestion; Inflammation; Fibrinous Exudations; Suppuration; Gangrene; Ascites; Morbid Growths, 133

SECTION II.—OF THE STOMACH.

Post-mortem Changes; Gastritis; Effects of Poisons; Gastric Ulcer; Hæmorrhagic Erosion; Softening; Cirrhosis; Atrophy; Dilatation; Morbid Growths, 137

SECTION III.—THE INTESTINES.

Malformations; Inflammation; Ulceration; Dilatation; Contraction; Displacements; Incarceration; Volvulus; Intussusception; Rupture; Ulcer and Fissure of the Anus; Fistulæ; Hæmorrhoids; Morbid Growths; Parasites, ... 149

SECTION IV.—THE PANCREAS.

Anomalies; Hypertrophy and Atrophy; Inflammation; Fatty Degeneration; Dilatation of Ducts; Cancer, ... 160

SECTION V.—THE SPLEEN.

Congenital Anomalies; Hypertrophy and Atrophy; Displacements; Rupture; Inflammation; Thickening of Capsule; Degeneration; Morbid Growths, 162

SECTION VI.—OF THE LIVER.

Normal state of; Congestion; Hæmorrhagic Effusion; Perihepatitis; Scar-like Marks; Hepatitis; Secondary, Pyæmic or Metastatic Abscess; Degenerations

of the Liver; Waxy, Lardaceous or Amyloid Liver; Atrophy; Simple Atrophy; Acute or Yellow Atrophy; Chronic Atrophy; Cirrhosis, or Hob-nail Liver; Hypertrophy; Morbid Growths; Parasites, ... 165

Affections of the Gall-Bladder and Ducts.

Inflammation; Dilatation; Morbid Growths; Biliary Calculi, ... 189

CHAPTER II.

The Urinary Apparatus.

Section I.—The Kidneys.

Congenital Anomalies; Congestion; Hæmorrhage; Nephritis; Pyelitis; Abscesses; Inflammation of Capsule; Morbus Brightii; Fatty Degeneration; Dislocated Kidney; Morbid Growths; Parasites, 193

The Ureters.

Dilatation; Inflammation; Morbid Growths, . 205

The Suprarenal Capsules.

Inflammation and Degeneration; Hæmorrhage; Morbid Growths, ... 207

Section II.—The Urinary Bladder.

Malformations; Dilatation; Hypertrophy; Contraction; Inflammation; Morbid Growths; Parasites, 208

Of the Urethra.

Malformations; Inflammation; Dilatation and Contraction; Stricture; Rupture; Morbid Growths; Urinary Calculi, ... 208

CHAPTER III.

The Male Generative Organs.

Section I.—The Penis.

Congenital Anomalies; Hypertrophy and Atrophy; Fracture; Paraphymosis; Balanitis; Herpes; Chancres; Morbid Growths, ... 215

Section II.—Of the Scrotum.

Hypertrophy; Inflammatory Œdema; Morbid Growths, ... 218

SECTION III.—OF THE TESTICLES.

Congenital Anomalies; Hypertrophy and Atrophy; Inflammation; Hydrocele; Hæmotocele; Varicocele; Morbid Growths, . . . 219

SECTION IV.—THE SEMINAL VESICLES AND PROSTATE.

Congenital Anomalies; Inflammation; Tubercular Deposits, ... 226

The Prostate Gland.

Anomalies; Hypertrophy and Atrophy; Inflammation; Abscess; Morbid Growths, . . 226

CHAPTER IV.

THE FEMALE GENERATIVE ORGANS.

SECTION I.—THE PUDENDA AND VAGINA.

1. *The Pudenda.*

Congenital Anomalies; Hypertrophy; Inflammation; Morbid Growths, ... 230

2. *The Vagina.*

Anomalies; Occlusion; Dilatation; Laceration and Rupture; Inflammation; Morbid Growths, . 230

SECTION II.—THE UTERUS.

Anomalies; Hypertrophy and Atrophy; Hydrometra; Malpositions; Hæmorrhages; Peri- or Retro-Uterine Hæmotocele; Inflammation; Ulceration; Morbid Growths, . . . 235

Morbid Conditions following Parturition.

Rupture; Puerperal Inflammation, . . 241

Extra-Uterine Pregnancy, ... 244

SECTION III.—THE OVARIES AND FALLOPIAN TUBES.

1. *The Ovaries.*

Malformations; Inflammation; Abscess; Morbid Growths, ... 247

2. *The Fallopian Tubes.*

Anomalies; Inflammation; Morbid Growths, . 251

SECTION IV.—THE MAMMÆ.

Anomalies; Hypertrophy; Atrophy; Inflammation and Abscess; Morbid Growths, . . 252

The Male Mammæ, ... 257

PART IV.

MISCELLANEOUS SUBJECTS.

CHAPTER I.

OF THE PERIOSTEUM AND BONES.

SECTION I.—OF THE PERIOSTEUM.

Inflammation; Ulceration; Malignant Disease, 258

SECTION II.—OF THE BONES.

Inflammation and Abscess; Caries; Necrosis; Rachitis; Mollities Ossium; Morbid Growths, . 259

The Medulla, ... 267

CHAPTER II.

DISEASES OF THE JOINTS.

Malformations; Morbid Condition of Synovial Membranes; Morbid Condition of Bursæ; Morbid Condition of Cartilage; Ulceration of Cartilage; Chronic Rheumatic Arthritis; Scrofulous Arthritis, 268

Diseases of the Spinal Column, . . . 272

CHAPTER III.

OF TUMORS.

1. *Benign or Non-Malignant Tumors*, . . 274
2. *Malignant Tumors*, ... 286

CHAPTER IV.

POST-MORTEM APPEARANCES IN DEATH FROM UNNATURAL CAUSES.

1. *Death from Poisoning*, ... 294
2. *Death from Suffocation*, ... 300
3. *Death from Hanging or Strangling*, . . . 301
4. *Death from Drowning*, ... 302

CHAPTER V.

MEDICO-LEGAL QUESTIONS.

1. *Method of Conducting a Medico-Legal Autopsy*, . 304
2. *Questions Relating to New-Born Children*, . 307
3. *Supposed Period of Death*, . . . 312
4. *The Probable Cause of Death*, . . . 317

CHAPTER VI.

ON EMBALMING THE DEAD, ... 320

CHAPTER VII.

PRESERVATION OF SPECIMENS OF MORBID ANATOMY, 326

INTRODUCTION

BEFORE entering upon the study of any subject, it is of moment that the student be thoroughly convinced of the importance of the knowledge which he is about seeking to acquire, since his zeal in its pursuit will, in most cases, be in proportion to this conviction. We will, therefore, before entering upon the subject proper of this book, present in few words, some considerations on the *importance of a study of morbid anatomy as revealed by post-mortem examinations.*

The necessity of a study of anatomy and physiology by a medical student, is now so universally recognized, that an attempt to prove its importance would seem deserving only of ridicule; but the ignorance of many practitioners on the subject of morbid anatomy, shows that this study has yet to vindicate its claim as a necessary branch of a medical education.

From a purely theoretical standpoint, the educated physician—one whose motto is *Esse, non videri*—after combating a disease in vain, should not feel content to remain in ignorance of its real nature, so far as discoverable by anatomical changes, capable of being recognized after death, even had he no prospect of adding thereby one jot to his practical acquaintance with disease or to his power to combat it; yet his scientific conscience (if we may be allowed the expression) ought not to rest satisfied until, in all doubtful cases, his *ante-mortem* diagnosis be confirmed or overthrown, and his conception of the case completed in all its details by a *post-mortem* examination.

Besides this purely individual scientific interest, there are weightier practical reasons for an acquaintance with this branch of medical science by the physician as practitioner.

Among the almost innumerable questions upon medical, theological, and miscellaneous subjects which the American public feels at liberty to propound to its medical advisers, none are of more frequent occurrence and none are more justifiable than the two: "What is the matter with the patient?" and "Will he, or can he, recover?" and to none is an answer more imperatively demanded. The public very naturally, and with reason, requires on the part of a physician the ability to make a diagnosis and a prognosis. It will not be satisfied with being told that the name of the disease is of no importance, that the doctor only wants to hear the symptoms; that he does not cure *diseases*, but removes the symptoms of disease, &c. Only an exceedingly well-trained public will accept these truisms as an equivalent for diagnostic skill. Hence, it is the physician's interest, as well as his duty, as we shall see, to seek, in all cases, to make a diagnosis, no matter how difficult the task may prove to be. The question how far his treatment will be modified by his diagnosis is a question of therapeutics, and does not belong here; but certain it is, that a mere combatal of the symptoms as isolated phenomena cannot be regarded as fulfilling the whole duty of a conscientious physician.

The ability to make a diagnosis, and consequently prognosis, depends upon a knowledge of pathology, with a knowledge of symptoms as signs of pathological states and changes; and as such they must be critically examined and their true import discovered, if possible. Thus treated, we arrive, by various processes of reasoning, at a diagnosis, under which the symptoms fall into their natural order of importance, and we run but little risk of contending with remote subjective symptoms (of great importance in differen-

tial therapeutics) to the neglect of more important, though perhaps less prominent ones.

Besides this, we are, in a measure, prepared to foretell the probable course of a disease, and can, therefore, in many cases, adopt anticipatory measures, while in all we will be guarded against the error, so often committed, of ascribing to the remedy used the so-called "*aggravations*," which are often only natural symptoms of the unchecked and, perhaps, entirely uninfluenced morbid process. Such knowledge serves thus, by purifying our experience, to guard us against self-deception, and to prevent us from misleading others by reports of cures of diseases existing only by virtue of a false diagnosis.

A knowledge of pathology, furthermore, places in our hands a thread which can guide us through the labyrinth of our vast materia medica, and which enables us, from the myriad of symptoms, to eliminate the non-important ones. It shows us the "bearings" of the medicines and their various specific ranges, thus materially facilitating the choice of a remedy.

Again, medical science is virtually based upon pathology, and we see, therefore, how important, nay, how absolutely necessary, to the progress of the former is the study of the latter. The practice of medicine as an art can never be advanced knowingly by those who neglect its cultivation as a science. While each one may practice the art according to his own convictions, true medical science stands above all the belittling, bigoted prejudices of the schools. Here, every one claiming the name of an educated physician can and ought to work.

The wild vagaries of former ages, when philosophy set up purely theoretical views, under which observed phenomena were compelled to arrange themselves, have warned the present age to be guided solely by sober and exact observations and investigations; and it needs no proof that, in the

advancement of our knowledge of disease, these are best accomplished by frequent post-mortem examinations, which thus become a necessary adjunct to a proper study of pathology.

In all cases of interest, therefore, the physician should feel it a duty which he owes to himself and the profession at large, to seek permission to make a post-mortem examination; but in order that the fullest benefit may be derived from the same, he must know how to look for what he is in search of, and how to recognize it when found.

To furnish this knowledge is the object of the following pages, to which we herewith introduce the reader.

PRELIMINARY CHAPTER.

INSTRUMENTS AND GENERAL DIRECTIONS.

The Post-mortem Case, as prepared by the instrument makers, will be found to contain, usually, the following instruments:

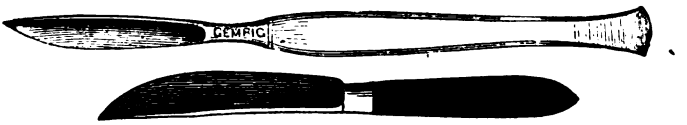

1. A set of ordinary dissecting scalpels, four or five in number, and of graduated sizes, including one heavy cartilage knife.

2. A brain knife with a long blade, for slicing the brain.



3. Chisels, of one or both the accompanying forms, for use in opening the head or spine.

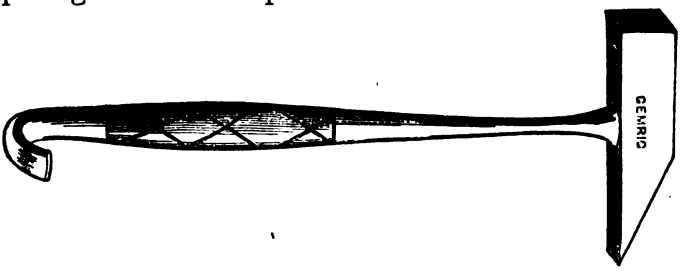

4. An iron mallet or hammer, with a hook on the end of the handle for tearing off the culvarium.

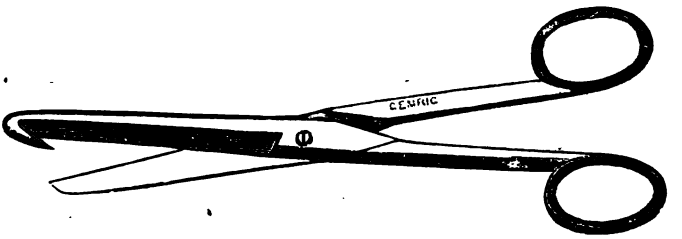

5. An enterotome, or scissors with blunt, hooked point, for splitting open the intestinal canal.

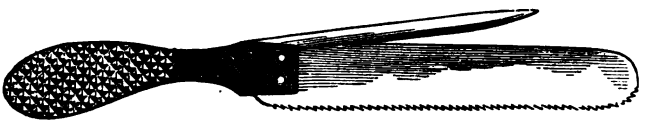

6. A saw with movable back; this arrangement permitting of a deeper cut, in dividing large bones.



7. The rachitome, a chisel-like instrument, to be used with the hammer in opening the spinal canal.

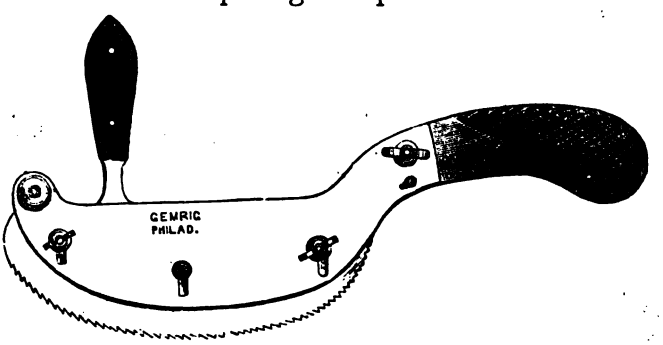

8. The double saw, used for dividing the laminæ of the vertebræ. A side view of the instrument being given in the cut, one blade only is seen. The two are attached to one handle, placed parallel with one another, and about one and one-fourth inches apart. After the soft tissues have been

removed, this saw is used by passing the spinous processes between the two blades, and thus dividing both laminæ at once.



9. A skull clamp, for steadying the head while removing the calvarium. After the removal of the scalp, this instrument may be employed, and be of much service for the above object. It is applied by placing the open end of the instrument over the crown of the head, turning down the screws, and thus fastening it just above the line of division of the bone. The arched end of the instrument now serves as a handle for turning or steadying the head.

10. Rib-shears, for dividing the ribs where that operation is found desirable.

11. A tube for inflating the lungs, and an ordinary blowpipe.

12. Dissecting forceps, tenacula in handle and with chain, grooved director, and assorted needles, straight and curved.

While a post-mortem case with all of the above instruments is very convenient, and important even, where there is frequent occasion for its use, still its absence should never deter the physician from making an examination where the ordinary dissecting case may be had; and with the country physician generally, this case is all that is absolutely essential, as a common carpenter's saw and chisel may at any time be found, in cases where the head is to be opened; while for opening the chest and abdomen, the dissecting case contains everything that is essential.

Instruments used in post-mortem examinations should never be employed for operating upon the living, without first being repolished by the instrument maker, and the handles disinfected by careful cleaning in a solution of permanganate of potash.

PRELIMINARY PREPARATIONS.

The Preliminary Preparations at the place of the operation should consist in providing a sponge for absorbing fluids; newspapers and old cloths for filling cavities or wrapping up any morbid specimen that it may be desirable to preserve: a couple of quarts of clean sawdust or wheaten bran for throwing into the cavities before closing them up, and thus absorbing any excess of fluids; stout thread or twine for tying intestines and closing the cavities; lard or sweet oil for oiling the hands; a couple of empty slop-buckets for receiving the fluids, bloody water, &c., and plenty of water, hot and cold, with towels and soap. If the floor of the room is carpeted, to protect it from accident, a piece of old carpet, or quilt, or oilcloth should be spread alongside the table or box where the examination is made. Care should be observed to have all these matters provided before the operation is commenced, when the door should be fastened, that there may be no intrusion, by accident or otherwise.

In preparing the body for examination, if the head is to be opened and the body is in an ice-box, it will be absolutely necessary that it be removed. Placing the cover of the box on the floor, the body may be lifted out and placed on the same, when both may be again placed on the top of the box or on a table, for the examination. If only the chest and abdomen are to be examined, it will hardly be necessary to lift the body from the box. In all cases, the sheet in which the body is placed, with the underclothing, (the latter having

been split down the centre,) should be carefully turned aside, and care observed during the operation to avoid as much as possible soiling them with blood-stains.

Precautionary Measures. That there is a certain amount of danger from absorption of virus in case of cuts or scratches received while conducting a post-mortem examination, cannot be denied; yet this danger is by no means common to every case. In the great majority of instances, probably no mischief whatever would follow such an accident, the danger being confined almost wholly to cases of peritoneal inflammation, erysipelas, and certain malignant forms of disease. In all cases, however, it will be well to look for any scratch, cut, or abraded point on the hands or fingers, and first touching them with nitrate of silver, cover them finally with collodian. Smearing the hands well with lard or olive oil will also aid much in preventing absorption.

Should an accidental cut be received during the operation, it will be prudent, in all cases, to wash the hands at once, squeeze and suck the part, to favor bleeding, and, finally, touch with a crystal of nitrate of silver. Punctures with a needle or slight scratches which do not bleed are, probably, more dangerous than a free cut; hence, in cases of suspected danger, when a puncture has been received, it would be safer to make a free incision with a knife, thus inducing bleeding, which will favor the washing out of any virus, and finally, use the caustic.

Time for Making the Examination. As a rule, post-mortem examinations should be made as soon after death as a due regard to the feelings of friends will permit, say within twelve to twenty-four hours; a longer delay would give time for such decomposition as not only to make the examination extremely disagreeable, but, from change of structure in tissues and organs, much less satisfactory. In cold weather, however, or where the body has been placed

in ice soon after death, as is the custom in most cities, the examination may be postponed to any convenient time before the burial.

Notes. In all important cases, notes should be taken down by an assistant, on the spot, as dictated by the operator; heading these by the name and age of the patient and a brief sketch of the disease. In medico-legal cases, this is to be conducted with particular care, as will be pointed out hereafter.

Consent of Friends. Much difficulty will sometimes be met in obtaining the consent of friends for a post-mortem examination, the idea of the mutilation of the body of the deceased striking many with particular dread. With a little tact and management, however, consent may, in the majority of instances, be obtained. Instead of speaking to a single member of the family and leaving him or her to bring the subject before others, in all doubtful cases it will be better for the physician to see all the interested parties himself, either together or separately, and endeavor to interest them in the case, by pointing out the peculiar character of the disease, the satisfaction which the friends will themselves derive from a verification of the diagnosis of their physician, while, when too late, they may regret having withheld their consent; also the scientific interest which attaches to the case, and the benefit which will no doubt accrue to medical science through a post-mortem examination, and the possibility that the lives of others may depend upon a knowledge of the true state of this case. These, with like considerations, adapted with ready tact to the class of persons to be persuaded, will, in the majority of instances, be enough to overcome all scruples, especially when joined to the assurance that the examination will be so conducted as to leave no visible trace of the operation with which to embitter the remembrance of the well-known countenance.

PART I.

THE HEAD AND SPINE.

CHAPTER I.

THE OPERATION.

In opening the head for a post-mortem examination, let a thick block be placed beneath the occiput, when, after having carefully parted and turned aside the hair, an incision may be made through the scalp, over the top of the head, from ear to ear. The back of the scalpel being placed next the head, the point may be pushed in advance, thus dividing the tissues without danger of injuring the edge of the instrument by bringing it in contact with the bone.

From the loose connection of the tendon of the occipito-frontalis muscle to the periosteum, by the use of the handle of the scalpel, the flaps of the scalp may readily be turned aside, the anterior over the face, the posterior on the back of the neck. The *skull clamp* may now be applied, which will be of great service in steadying the head while using the saw. Instead of dividing the skull in a circular manner, as is usually done in the dissecting-room, it will be better to start the saw above the frontal eminences and run obliquely down towards the mastoid process, meeting this line by another commencing at the occipital protuberance and carried horizontally forwards, thus giving a wedged form to the portion removed. The advantage of this method consists in our

being better able to hold the parts in position as they are replaced, as in the old method, from the readiness with which the parts move upon one another, the calvarium is liable to slide forwards or backwards from its position, thus producing an unsightly ridge across the forehead, which will more or less plainly show through the integument. With young children, a strong pair of scissors may be used instead of the saw in dividing the calvarium.

In using the saw, care should be observed not to injure the dura-mater; hence it will be better not to attempt to divide both tables with that instrument, but rather depend upon the chisel or rachitome for breaking away the inner table. To avoid the sound which would attend the use of the iron hammer, which, if heard by members of the family, might excite unpleasant feelings, a billet of wood or wooden mallet may be used; or, these not being at hand, the head of the iron hammer may be muffled with a towel, so as materially to deaden the sounds. The inner table having been divided, the calvarium may be pried off with the chisel, or torn away with the hook on the handle of the hammer. This, from the close adhesion of the dura-mater to the bones, will generally require considerable force.

The calvarium having been removed, and the superior longitudinal sinus opened, and the condition of its contents noted, the dura-mater, after its careful examination, may be cut through with the knife or scissors in the line of the division of the bone. The membrane may now be lifted up, when adhesions will be found between its under surface and the pia-mater, along either side of the falx cerebri. These should not be mistaken for results of inflammation, as they sometimes are, they being simply the points of entrance of the veins of the pia-mater into the superior longitudinal sinus. These having been divided, with the falx near its attachment to the crista galli, the whole may be turned back, exposing the brain.

To remove the latter, take away the block from beneath the head, and lifting the anterior lobes of the brain, divide successively the several pairs of nerves as they appear in sight, with also the tentorium on either side, and as the brain falls back into the left hand, the knife may be passed down into the foramen magnum, and the medulla oblongata and vertebral arteries divided, when the whole may be lifted from its position. More or less blood with the *cerebro-spinal fluid* will necessarily flow off during this operation, to secure which, a bucket should be placed beneath the edge of the table, over which the head should slightly project. In dropsy of the brain, although the fluid is mainly in the ventricles, it may escape during the operation and be caught in the same manner.

The external surface of the brain having been carefully examined, the hemispheres may be sliced off to a level with the corpus callosum, when, by removing the latter, the cavities of the lateral ventricles will be exposed. After a careful inspection of the several objects seen here, the fornix and velum interpositum may be removed, opening thus into the third ventricle. Slices may now be taken off the corpora striata and optic thalami, with deeper portions of the hemispheres, and sections made of the crura cerebri cerebellum and medulla oblongata, thus giving an opportunity of judging of the condition of all those parts.

After the removal and examination of the brain, attention should be given to the *base of the skull.* The lateral and other sinuses should be laid open, the dura mater, as far as possible, torn away, and the bones examined for fractures, caries, abnormal growths, etc.

"*The simplest method for removing the ear* for the sake of dissection is, after the removal of the calvarium in the usual way, to take out both the petrous bones together by means of two transverse vertical sections, one in front of the two

petrous bones and the other posterior to them. The anterior of these sections should pass in a line a little anterior to the anterior clinoid processes, and the posterior in a line through the posterior third of each mastoid process. By means of these two sections, the trumpet-shaped extremity of each Eustachian tube, a portion of the mucous membrane of the fauces, and the whole of each petrous bone, together with the mastoid processes, can be taken out.

"The disadvantage of this procedure is the disfigurement which is apt to ensue from the falling in of the face. To avoid this disadvantage, another mode of removing the ear may be resorted to. This consists in taking out each petrous bone separately in the following manner: The calvarium having been sawn off, an anterior section is to be made in each side in the same line as in the above plan, but extending only as far as the outer part of the body of the sphenoid bone; a posterior section in each side is then to be made, as in the first plan, but not extending farther inwards than the basilar process of the occipital bone. These two sections are to be made with a saw or with a chisel and hammer. The apex of each petrous bone is then to be separated from the sphenoid and occipital bones, and each petrous bone (the outer ear and integument being detached and reflected downwards) is to be drawn outwards, taking care, by inserting the scalpel deeply, to remove as much of the soft parts as possible.

"The organ of hearing having been removed, the dissection may be conducted in the following manner: The auditory nerve in its meatus should be first carefully examined, presuming that a previous inspection has been made of the portion of the brain to which the portio mollis and portio dura nerves are attached. The size of the external meatus having been ascertained by allowing a strong light to fall into it, its anterior wall is to be removed by the cutting forceps.

"The state of the epidermis, the ceruminous glands and secretion, the dermis, periosteum and bone is to be noticed. The outer surface of the membrani tympani is then to be examined; also the state of its epidermoid and dermoid laminæ, its degree of tension, and the amount of motion possessed by the malleus when pressed upon by a fine point. The next step is to ascertain the condition of the guttural portion of the Eustachian tube, to lay open the cartilaginous tube with the scissors, and then to expose the cavity of the osseous portion by means of the cutting forceps. In doing this, the tensor tympani muscle is exposed; its structure should be examined, and if it has not a healthy appearance, portions of it should be submitted to microscopic inspection. The upper wall of the tympanum is next to be cut away by means of the cutting forceps. In doing this, great care must be taken not to disturb or disconnect the malleus and incus, which lie immediately beneath it. After the tympanic cavity has been exposed, the first step is to pull the tensor tympani muscle and ascertain how far it causes a movement of the membrana tympani and ossicles. The incus and stapes are now to be touched with a fine point, so as to ascertain their degree of mobility; the tendon of the stapedius muscle is also to be pressed upon. The condition of the mucous membrane of the tympanum and of the mastoid cells is then to be ascertained, and any peculiarity of the cavity, the existence of bands of adhesion, etc., to be noted.

"The most delicate parts of the dissection, viz., that of the internal ear, must now be undertaken. The cavities of the vestibule and cochlea are to be exposed by removing a small portion of the upper wall of each. Before reaching the vestibule, the superior semi-circular canal will be cut through and removed; the membranous canal should be drawn out and inspected. As the cavities of the vestibule and cochlea are laid bare, it is desirable to see that the quantity of perilymph is natural, as well as its color and consistence. The

outer surface of the membranous labyrinth having been observed, it should be opened so as to expose the endolymph and otoliths, portions of all which parts should be removed for microscopic inspection. This having been effected, the remaining membranous semi-circular canals are to be exposed, and the connection of the base of the stapes to the fenestra ovalis carefully examined. The last stage of the dissection consists in removing parts of the lamina spiralis, in examining them microscopically, and in exposing from within, by following the course of the scala tympani, the membrane of the fenestra rotunda.

"The only part which now remains unexamined is the stapedius muscle; in order to expose it, the course of the aquæductus Fallopii, beginning at the stylo-mastoid foramen, should be followed until the base of the pyramidal eminence containing the muscle is reached."*

The Eyes, with the optic nerves, may be most conveniently removed for examination, by breaking up the roof of the orbit with the hammer, and, after the removal of the fragments of bone, dissecting away the fat and muscles until the ball is exposed, when, with the scissors, the tunics of the latter may be divided just behind the conjunctival attachment, and the ball removed with the optic nerve. The front portion of the eye being left in position, by filling the cavity behind with a little cotton or paper, any flattening may be prevented, and thus any appearance of loss of parts avoided.

The examination having been completed, the brain may be replaced, the calvarium put in position, the scalp brought over the same and united with stitches, the arranging of the hair effacing all traces of the operation.

---

* Toynbee on the Ear.

THE SPINAL CORD.

For the removal of the *spinal cord*, place the body in a prone position, and make an incision the whole length of the back, over the spinous processes of the vertebræ. Then raise up and turn aside all the muscles with the integument, exposing the laminæ of the vertebræ. The latter may now be divided with the single or double saw, the rachitome or chisel being used to complete the operation, when the laminæ, with the spinous processes, may be removed in one strip, exposing the cord enclosed in its membranes.

The roots of the nerves may now be divided, and the cord, enclosed in its sheath, removed; care being observed not to handle the parts roughly while so doing. The dura mater may now be split open for the examination of the cord. Should it be desired to preserve any portion for microscopic examination, it may be suspended in a solution of bichromate of potass, xx to xxx grs. to the ounce of water, and in a few days transferred to a solution of chromic acid, ij grs. to the ounce of water, where it should remain until sufficiently hardened to be cut into thin sections.

The examination completed, the parts may be replaced and the incision sewed up.

CHAPTER II.

PATHOLOGICAL CONDITIONS.

Section I. OF THE SKULL.

[**Notice** in examination, condition of *scalp;* cuts, bruises, extravasation of blood, &c. *Cranium*—Color, smoothness or roughness of exposed surface; fractures, their position and relation to injuries of scalp. *Removal of Calvarium*—Adhesion of dura mater; inner surface of; smooth or rough; seat of same; deposit of new bone; depression of inner table; thickening or thinning of. State of fontanelles in children; condition of frontal sinuses; condition of base of skull noted after removal of brain; fractures; condition of petrous portions of temporal bones, &c.].

Fracture. In a post-mortem examination of the head, after death from a blow or fall upon that part, a fracture may be disclosed of which there was no external trace. Owing to the greater thinness and brittleness of the inner table, it is possible for this to be fractured without any corresponding injury to the external; such fracture may possibly rupture some of the branches of the meningeal arteries, which will be followed by the formation of a clot between the bone and dura mater, the pressure of which may be sufficient to produce death. Owing to the same cause—greater brittleness of the inner table—when fracture of the outer exists, that of the inner table will be likely to be more extensive, accompanied perhaps with depression, of which there is no external evidence.

Again, it will sometimes be discovered that fracture exists at a point opposite to that upon which the blow was received, on the principle of the "*contre coup*" of the French; thus, the blow having been received on the occiput, the fracture may be found in the frontal region; or, received on the top of the skull, fracture may result at the base. In falls from a height, upon the top of the head, the weight of the body,

acting through the cervical vertebræ as a propelling force, is very likely to produce fracture of the occipital bone.

Caries may affect any of the bones of the head, but in the majority of cases it will be the result of syphilitic or mercurial poisoning. Following an attack of periostitis, the inflammation extends to the bone and gradually develops the carious ulceration. While the condition is usually confined to, or at least, most strongly developed upon the outer table, it may involve the entire thickness. In syphilitic ulceration of the bones of the nasal cavity, the disease may destroy the cribriform plate of the ethmoid bone, and thus extend to the membranes of the brain.* So also, in caries of the petrous and mastoid portions of the temporal bone, which sometimes results from scarlet fever, the disease may extend to the inner surface, resulting in the accumulation of pus within the cranial cavity.

Along either side of the central portion of the inner surface of the calvarium may be usually seen, at least in the heads of aged persons, a number of irregular, rough pits, varying in size and depth, which are not to be mistaken for disease of the bone, they being simply impressions of the *Pacchionian glands.*

Thinning of the bones of the head will always indicate *increased pressure* from within, induced by hypertrophy of the brain, or, as is more frequent, hydrocephalus. In the latter case, not only thinning, but complete absorption of the parietal and other bones may result.†

Increased Thickness will also sometimes be found. This condition indicates *diminished pressure* from within, as in atrophy of the brain. The thickening results from a

---

* See No. 509, College Museum. †Id, 473.

gradual remodeling of the inner table and diploe, so that while the exterior of the skull may retain its normal size and form, the inner table following the retiring and shrinking brain, the interval between the two becomes filled with the thickened diploe. It has been observed that this hypertrophy is greatest at those parts of the bones where ossification first commences, as at the parietal and frontal eminences. It is not confined to old persons, though perhaps more frequent with them.*

Section II. THE MEMBRANES OF THE BRAIN.

1. The Dura Mater.

[**Notice** color and general character of surface; blood between it and bone; position of; quantity; coagulated or not. Condition of bone—necrosed or fractured; pus between dura-mater and bone. Tumors—their position, size, &c. Wounds—their position, extent, &c. Open longitudinal sinus and note contents.]

This membrane, serving both as a periosteum to the inner surface of the cranial bones and as a support to a serous membrane—the reflected layer of the arachnoid—is subject to affections of a two-fold character, those peculiar to the fibrous and serous portions.

Inflammation of this membrane, may involve either the outer fibrous, or the inner serous layer. In the former case, the membrane appears congested, red and more or less softened. The inflammatory process may result in the formation of pus between the bone and dura mater, and even in gangrene. The disease may also extend to the adjacent portions of the pia mater and brain substance. External injuries, fractures of the bones of the skull, inflammation of the periosteum, otitis, resulting in caries of the temporal

* See No. 490, College Museum.

bone, may all be causes of inflammation of the outer portion of the dura mater.

Inflammation of the inner surface of this membrane, is marked by the presence of a net-work of delicate red vessels, while the surface is covered by a soft, grayish or yellow semi-purulent matter, and may attend cases of pyæmic poisoning, puerperal peritonitis, or some of the exanthemata.

Thickening of the fibrous portion of the dura mater may be found as a result of chronic inflammation, either spontaneous or as the result of external injury. From the identity of structure between this and other fibrous tissues of the body, it is not unlikely that this thickening is often the result of a rheumatic form of inflammation.

External violence is, however, most commonly the cause of the change. In one case, the patient fell down stairs in a state of intoxication, striking the head on the steps. He continued in a state of insensibility for nine days, when he began to show signs of returning consciousness, taking food and drink, but memory, judgment, and all the mental faculties were gone. Death ensued in about two years. The dura mater of the left hemisphere was found greatly thickened. The pia mater infiltrated with a large amount of serous fluid. The convolutions were atrophied, and about four ounces of serous fluid found in the ventricles. The *fornix* was softened and the *septum lucidum* entirely destroyed.

Fibrinous Clots, or Thrombi, will be occasionally found within the sinuses of the dura mater, where they may have given rise to congestion of the brain, with apoplectic effusions, paralysis, convulsions, coma, etc. They may originate from injuries of the head, inflammation of the dura mater, pulmonary disease, etc.

Tubercular Deposits are also sometimes found in this membrane, appearing, however, mainly upon the arachnoid surface. They present the usual character of tubercle, having a whitish or grayish appearance, with the consistence of cheese, and scattered in small particles upon the surface. They are found in *tubercular meningitis*, (a disease common with children but rare with adults,) and in most of those cases of so-called acute hydrocephalus.

Tumors of various kinds are occasionally found in the dura mater, including *cystic, fibrous, fatty, osseous* and *cancerous* growths. The latter may cause such absorption of the bones of the skull, as to appear on the exterior of the head.

In one case which came into the dissecting-room some years ago, thin *bony formations* of the size of a silver quarter dollar were found in the tentorium, and smaller ones in the falx cerebri. Nothing could be learned of the previous history of the case.

2. Arachnoid and Pia Mater.

[**Notice** in examination, contents of cavity of arachnoid; serum or blood; if former, amount, color, odor; if blood, situation, quantity, fluid or coagulated; adhesion of surfaces of arachnoid; tubercles, their position, &c.; color of membrane; vascularity, transparency, or opacity. *Sub-arachnoid* fluid—quantity, position, color, &c. *Pia mater*—vascularity, in points and entire; serous effusion into substance of; blood, &c.; position, size, &c., of clots; granulations, (tubercles,) number, position, &c.; Tumors—size, position, and character.]

As morbid conditions of the arachnoid membrane are more common with its visceral layer, and as these conditions usually involve the pia mater, the two membranes are here noticed together. They will be found presenting various

degrees of congestion after death, which will not necessarily be a positive indication of the extent of congestion during life.

Pacchionian Bodies. Along either side of the great fissure may be noticed within the pia mater of adults, several small white bodies, varying in number and size—the *Pacchionian bodies.* They may cause absorption and perforation of the dura mater, and even of the bones of the skull. Being looked upon as the result of mere senile changes, they do not indicate the presence of disease, though repeated congestions of the brain appear to favor their more rapid development.

Inflammation of these membranes, or *meningitis*, is a very common affection, and is accompanied with an accumulation within its substance or beneath its layers, of serum, lymph, or fibrine in various proportions. It may be confined to circumscribed portions, or involve a large portion of the membrane, and even extend to the spinal cord. Adhesions between the two surfaces of the arachnoid sometimes result from this form of inflammation.

Insanity in its various forms is most frequently accompanied with some morbid condition of these membranes. In twenty-two cases of insane persons whose brains were inspected by Dr. Marshall, in twenty-one, serous fluid, varying in amount from one to twelve ounces, was found in the ventricles, and in seventeen of these twenty-one cases, similar effusion was found in the sub-arachnoid space, or within the substance of the pia mater. While red injection of the membrane was found only in four cases, yet other conditions —the effusions, &c.—were evidently the result of previous inflammation. In nine cases were the arteries of the brain opaque, thickened, steatomatous, or ossified; conditions

highly favorable for deranging the capillary circulation of the membranes or of the brain.*

The following statement gives the principal morbid changes of these membranes which have been found in cases of insanity:

1. Injection, more or less intense, of the *pia mater*, giving a red or scarlet appearance; or, where infiltrated with serous fluid, presenting a pale gray color and increased in thickness.

2. The arachnoid (the visceral layer) becomes opaque and thickened, resembling the dura mater or macerated parchment.

3. The meningeal injection may terminate in serous effusion, either from the free surface of the arachnoid into the sub-arachnoid tissue, (pia mater,) or from the choroid plexus into the ventricles.

4. Albuminous exudations may be found upon the free surface of the arachnoid of the *dura mater*, covering its whole extent, or confined to definite portions.

5. Adhesions of the two surfaces of the arachnoid may rarely be found. It is most common in the great fissure, and has been found in the ventricles.

6. Blood may be effused upon the surface of the arachnoid or in the substance of the pia mater.

Serous Effusion. As has been already intimated, this may be found either in the cavity of the arachnoid—between the reflected and visceral layers—or within the ventricles. In the former position, the quantity is never large, while in the latter, it may amount to twelve or sixteen ounces, and be present for many years. When in such large quantity, there

* Morbid Anatomy of the Brain, in Mania, &c.," by Andrew Marshall, M. D.

will be great distension of the ventricles and thinning of the corpus callosum and fornix, with destruction of the septum lucidum, as well as more or less separation of the cranial bones. It is only in children and before the bones of the head have become united, that such large accumulations are possible, as at a later period, from the unyielding condition of the walls of the skull, the presence of a single ounce, particularly if suddenly formed, would produce death. In all cases, the danger to life will be in proportion to the rapidity of the formation; a very slow and gradual accumulation permitting either of an expansion of the cranial bones, or a gradual absorption of brain substance, thus preserving an approximation to the normal pressure on the brain tissue.

Serous effusions, like sanguineous, are generally the result of over distension of the cerebral vessels, either from mechanical obstruction, or a weakened condition of the coats of the vessels, with increased force in the action of the heart. It generally attends tubercular meningitis, and may be favored by an anæmic condition of the system. The symptoms during life, attending a rapid effusion of serum, are not so readily distinguished from those of sanguineous effusion, as to enable us to pronounce with certainty in any given case as to the cause of the cerebral pressure.

Sanguineous Effusion—Apoplexy. Effusions of blood may be found between the bones and dura mater; between the two layers of the arachnoid; within the substance of the pia mater; within the ventricles, or within the brain substance. Blood clots will seldom be found between the bone and dura mater, except as a result of mechanical injury, and in the majority of cases as an attendant upon fracture. If a fragment of the bone at the same time, be driven through the dura mater, then a clot may be found in the arachnoid cavity. But in another class of cases, where death has

resulted from blows upon the head without producing fracture of the bones, the whole surface of the brain in the region of the injury, and not unfrequently in distant parts, after the removal of the dura mater, is found covered with a layer of blood, which at first sight appears to be outside of the membranes; but on close examination, it is found that the blood is effused or infiltrated into the sub-arachnoid tissue, and that it has escaped from the lacerated vessels in the pia mater. The thickness of the layer varies. It is generally in greater quantities at the sides and base of the brain, and the inferior lobes and cerebellum may be covered by it. It is usually thickest over the crura, the pons Varolii and medulla oblongata.

In the same class of cases the blood may be also effused into the ventricles. These appearances are so uniformly the result of violence, as to form a valuable piece of evidence in medico-legal inquiries, to prove that such hæmorrhage and death could not be the result of internal causes.

In the greater number of *still-born* children, an examination of the head will show a similar condition of things. The surface of the cerebrum generally, with sometimes that of the cerebellum, will be found covered with a layer of coagulated blood effused into the pia mater, while the ventricles will often be filled with clots. Where the history of the case is not known, it might at first be suspected that death was the result of violence inflicted after birth. Violence has, to be sure, been the cause of death, but it is such violence as attends a protracted case of labor, with, perhaps, a large head, and a contracted pelvis of the mother. The wonder is, that from the great pressure to which the head is subjected during labor, that so few children are still-born or do not die soon after birth, from rupture of the cerebral vessels.

Effusions into the ventricles, may also be frequently the

result of external violence. The pia mater, the vascular membrane of the brain, we find carried into these cavities by means of the velum interpositum, which forms the roof to the third ventricle, while its borders extend into the lateral, forming the choroid plexuses. The effused blood may, therefore, extend along this membrane into the cavity of the ventricles.

Again, blood may be effused in any portion of the *brain substance*, constituting true sanguineous apoplexy. Certain parts are much more frequently the seat of these effusions than others. They are more common in the striated bodies or optic thalami—probably from the greater vascularity of those parts—but may be found in the corpora quadrigemina, the pons Varolii, the crura cerebri, or in the cerebral hemispheres, and occasionally in the cerebellum. The symptoms duriug life will vary according to the location of the effusion; when in the pia mater, or in other words, outside of the brain, paralysis will seldom attend, though the coma may be profound, with relaxation of the muscular system and sometimes convulsions. When the hæmorrhage is in the optic bed or striated body of one side, from the decussation of fibres in the medulla oblongata, paralysis of the opposite side of the body will follow; while if the effusion has taken place in both hemispheres, the palsy will be double-sided, though probably more complete on one side than on the other.

Effusions of blood into the corpora quadrigemina, will most frequently be attended with muscular tremblings or convulsions, and probably impaired sight, with some change in the pupil. When in the medulla oblongata, convulsions, followed by palsy, deep coma, and early death; greater fatality attending effusions at this point, probably, than at any other. When the effusion takes place in the cerebellum, the loss of consciousness will be very temporary; there may

be relaxation of muscles without palsy or loss of sensibility, and, it is said, frequent vomiting.

The *amount* of blood effused is subject to the greatest variation. Clots may be found as large as a hen's egg, or smaller than a pea. Indeed, violent apoplectic attacks, ending in death, may occur, where the most careful examination will fail to detect *any* effused blood, death being the result of extreme congestion of the membranes. On the other hand, the presence of a clot is not necessarily fatal, evidence being abundant that they may be so far re-absorbed as to be followed by at least partial recovery.

The following cases will serve to illustrate these several conditions:

CASE I.—*Sudden Death from Cerebral Congestion.*

Mr. M———, aged thirty-five years, had always enjoyed good health. For some months previous to death, had been working very hard, with a good deal of anxiety, in arranging the affairs of a company of which he was secretary. On the evening previous to his attack, he retired at eleven o'clock, well and in good spirits. At three o'clock A. M., his wife was wakened by his heavy, stertorous breathing, attended with slight convulsive movements of the limbs. In less than a half hour he was dead. The post-mortem showed the heart, lungs, and abdominal organs to be in a perfectly healthy condition, while the most careful examination of every portion of the brain failed to expose the least effusion of blood. The ventricles and sub-arachnoid space contained a moderate amount of serum, while the vessels of the pia mater were strongly engorged with blood.

CASE II.—*Apoplectic Attack, followed by Death in Three Days; Clot found in Thalamus.*

Mr. J———, aged sixty-one, a butcher, abstemious in his habits but plethoric in temperament, was suddenly stricken down with an attack of apoplexy, which left him with paralysis of the right side of the body, with impaired speech and memory. He gradually and almost entirely recovered. Ten months after, while in the street, he

fell with another attack. He partially recovered consciousness, but had complete palsy of the *left* side, and died in three days. Here, the post-mortem revealed excessive congestion of the pia mater, and a large clot, the size of a hickory nut, in the *right optic thalamus.* In the *left thalamus* was a distinct trace of a clot, (nearly absorbed, however,) which had undoubtedly been effused in the attack ten months previously.

CASE III.—*Apoplectic attack, followed by Hemiplegia, and Death in Five Years.*

Charles E. W———, at the age of forty-seven had a sudden apoplectic stroke, in January, 1867, followed by partial paralysis of right side. In May following, he had a second attack, which greatly increased the hemiplegia, impaired the articulation, and weakened the memory and intellect. His general health and strength gradually failing, he died August, 1872, five years after the original attack.

Post-mortem revealed a greatly thinned and dilated condition of the walls of the arteries of the base of the brain and the remnants of the original clot imbedded in the left optic thalamus, the brain substance around being of a dark color and much softened. From the appearance of the dark, ragged remnant of the clot, it must have been originally of about the size of a robin's egg.

CASE IV.—*Death from Congestion, with Serous Effusion and Softening.*

Mr. F. H———, aged thirty, had an attack of brain fever at twenty-three, followed by attacks of severe pain in the head, recurring every few days, weeks or months. These attacks were accompanied with slight convulsive symptoms and delirium, the pain being of a most excruciating character, and lasting from a few hours to two or three days. The attacks were gradually increasing in severity, but without any impairment of the faculties of the mind. On a Saturday night, he was brought home with one of his worst attacks. When I first saw the patient on Sunday evening, I found him in a half-delirious, stupid condition, yet when roused up, giving satisfactory answers to questions, but immediately sinking into his former condition, and every one to five minutes starting suddenly up and, with staring eyes and distorted face, uttering piercing shrieks and screams, and calling to those around to shoot him, split open his head with a hatchet—anything to release him from his sufferings. These paroxysms would sometimes be followed by

a convulsive action of the diaphragm and abdominal muscles, ending in his sinking into the same dull, stupid condition as before. In the interval of calm, the respiration was remarkably slow and feeble, with a slow irregular pulse of forty beats to the minute. These symptoms becoming gradually worse, he sank into a comatose condition early Tuesday morning, expiring at daylight, sixty hours after the commencement of the attack.

The post-mortem revealed greatly enlarged Pacchionian glands, with extreme thinning of the skull over the same. The pia mater was considerably congested. Upon turning the brain back for removal from the base of the skull, there was a sudden gush of water from the ventricles, sufficient of which was secured to show that the quantity could not have been less than two ounces. Upon opening the lateral ventricles, these cavities were found unusually large from distension by the fluid, while the *septum lucidum* and *fornix* were found in a soft, pulpy condition, the former being completely broken down and detached from the corpus callosum above. The gray portions of the corpora striata were also softer and more easily broken up than was natural.

The appearance presented by a clot, as well as the brain substance immediately around it, will vary according to the time the patient survives the attack. When death follows in a few days, the clot will have a soft, blackish appearance; after a month or six weeks, it becomes firm, and assumes a deep brown color, and at a still later period, it becomes still more firm, and of a pale red tint; lastly, it may become entirely absorbed. Peculiar changes also take place in the brain substance immediately around the clot, which vary according to the time intervening between extravasation and death. The portion immediately in contact with the clot is generally of a dark red or wine color, or, at a later period, of a chocolate brown, and of a soft, pulpy consistency. Exterior to this, the color is paler and of an orange tint, and still further on, of a bluish-white or yellow. The change in *structure* and *consistence* of the brain, immediately around the clot, constitutes one form of softening soon to be noticed.

Section III. OF THE BRAIN.

[**Notice** *before removal*—size; form; symmetry; space between surface of brain and calvarium. *After removal*—parts at base, their size, symmetry, color on surface, infiltration with serum or blood. *Removal of pia mater*—degree of adhesion; appearance of convolutions; color; consistence; effect of stream of water. Ulcers—condition of brain around. Sloughs—relation to membranes, condition of brain around. Deposits; tumors, wounds, etc. *After section, notice* breadth and character of gray portions of convolutions; color, vascularity, etc. *Consistency*—softened or hardened; of white substance; color. *Blood-vessels*—number and size of red points in different portions. *Extravasation of blood*—its situation; fluid or coagulated; amount or size of coagulum; color, etc. Cavities in brain substance; their number, shape and contents. Blood, purulent, or fluid; its quantity and color. Condition of brain around; cicatrices; wounds; adventitious substances, as tumors, calcareous masses, tubercle cancer, etc. *Lateral ventricles*—note any difference in the two; contents; amount of serum or blood. *Choroid plexus*—pale or congested; cysts; calcareous bodies; their size and situation. *Lining membrane* of ventricles; its vascularity, roughness, opacity, etc. *Septum lucidum*—entire or lacerated; consistence. *Fifth ventricle*—size, contents, etc. *Third ventricle;* contents. Commissures—their condition; middle, broken or double. *Optic thalami and corpora striati*—size, symmetry; character of surface and interior; if softened, extent; extravasation of blood, etc. Condition of *pineal gland; corpora quadrigemina; valve of Vieussens, etc. Medulla oblongata*—degree of adhesion of membranes; softening, exact locality of; condition about origin of nerves; appearance upon section. *Fourth ventricle*—contents; condition of floor, etc. *Cerebellum*—examine with same care, and note same points as in cerebrum.]

Inflammation. Acute inflammation of the brain substance is a rare disease, except as the result of mechanical injury. In such cases, the disease is generally quite circumscribed, being confined to the immediate region of the injury. The brain becomes very vascular, acquiring a red color, which, at a later period, changes to a brown or greenish hue, and becomes much softer than natural.

If a foreign body be lodged in the brain, as a piece of bone, or a bullet, then the inflammation is likely to result in an *abscess*, which will give rise to head-ache, delirium with intolerance of light, succeeded by convulsions, coma and death.

Subacute, or chronic inflammation of the brain, is much

more common, yet is accompanied with pathological changes similar to those of the acute form. At first, the inflamed portion becomes red and congested, the color gradually changing to a crimson, purple, brown, or claret color, with more or less change of consistence.

The symptoms attending inflammation of the brain substance, or *cerebritis*, are not readily distinguishable from those of meningitis; indeed, in most instances the two diseases are, to a certain extent, combined; as, from the vascular connection between the brain and pia mater, there might be a ready extension of inflammation from one to the other. When, however, there is any sudden perversion of the sense of vision or hearing; or if there are convulsions, affecting mainly one side of the body; or if coma succeeds the convulsions and is accompanied by one-sided paralysis, we may expect to find evidence of inflammation of the cerebral substance, with possibly that of the membranes also. It is a fact to be borne in mind, however, that while in typhus and typhoid, and perhaps some other forms of fever, we may have symptoms strongly resembling those of idiopathic inflammation of the brain or its membranes, still the post-mortem will reveal no trace of any such morbid condition.

Softening. To be able to recognize readily any change in the consistency of the brain, clear ideas must first be had of the normal density of this organ. This may be obtained from an examination of the brain of some of the lower animals—as the sheep or ox—that has been killed in a state of health. We shall then find that the brain presents sufficient firmness to permit of its being handled without rupture of its substance, and to allow of its being sliced into thin sections which will support their own weight. The gray portion is somewhat softer than the white, yet the fibrous character of the latter, becomes apparent only after hard-

ening in alcohol. If put into pure water, it continues unchanged for eight or ten hours, and without any portion becoming dissolved, or rendering the water any degree turbid. The consistence of the brain varies, normally, at different periods of life. In the fœtus and at birth, its softness approaches to semi-fluidity. From this to the fifteenth or twentieth year, it gradually acquires the firmness of the brain of the adult.

Softening, one of the most common variations from the normal condition, is generally a mere result of inflammation of a chronic or sub-acute form, accompanied with a fatty degeneration of nerve substance. Under the microscope, the change is seen to consist in a disintegration of the nerve fibres, the medullary substance breaking up into large masses, and undergoing fatty metamorphosis. It may take place either on the *external surface* of the organ, or in the *septum lucidum* and *fornix*, the *corpora striata*, or *optic thalami* of the ventricle, the central parts of the *hemispheres*, the *cerebellum*, or the *crura cerebri*, in the order mentioned.

While this change is usually the result of inflammation, as already mentioned, it may accompany or succeed the following morbid conditions of the organ: 1. It may be the result of congestion of the vessels of some portion of the brain. In this case, the softened portion is reddish, crimson, or brown in color. 2. It may follow the effusion of blood in apoplexy. The softened portion is then of a brownish color, or, if considerable time has elapsed, it may be of a dirty ash color, tending to green. 3. It may accompany or follow the process which terminates in serous effusions. It is then of a milky-white color. 4. It may take place in the brain substance immediately around tumors, when its color may present a variety of tints.

Among the causes tending to induce this condition of

the brain, may be mentioned a diseased state of its blood vessels, or their obstruction by fibrinous clots; constitutional syphilis; excessive mental labor, or frequently repeated epileptic convulsions. The consistency will be found to vary from a slight change from the normal condition, to that of a soft, pulpy, or even cream-like condition.

The symptoms accompanying softening of the brain, present a considerable variation. Among the more prominent, may be mentioned an unsteady or tottering gait, partial palsy, thick and inarticulate speech, feeble memory, disordered intellect, dull pain or heaviness in the head, frequent drowsiness, formication, numbness or rigidity, or occasional involuntary contraction of the muscles of the upper extremities.

Abscess of the brain, differs from softening, to which it may have some points of resemblance, in the purulent matter being contained in an irregular cavity, lined with a more or less distinct membranous cyst. Flakes of lymph are frequently found in these abscesses, giving the matter much the appearance of that contained in scrofulous abscesses, and they are most commonly found in subjects who present the usual symptoms of the strumous diathesis.

While these collections are unquestionably often the result of inflammation, yet it has been claimed that they may result from previous disease of a suppurative character in the lungs, and perhaps other organs, the purulent matter being taken up by the veins and carried into the general circulation, and finally deposited in the substance of the brain. Abscesses may be found in any portion of the brain substance, or the purulent accumulation may be found between the bone and dura mater, or between the two layers of the arachnoid. In the latter cases, the disease may generally be traced to caries of some of the bones of the head, as of the petrous or mastoid portions of the temporal,

or of the bones of the nasal cavity, involving the cribriform portion of the ethmoid.

Again, abscesses in the brain may result from external violence, as from a blow or fall upon the head. It is remarkable, that in these cases, some months may elapse between the date of the injury and death.

Hardening. Induration of the cerebral substance, is a condition not readily distinguished during life from that of softening, the two states being accompanied by symptoms of a similar character. Dr. Jones, who has charge of the male department of the Pennsylvania Hospital for the Insane, and has had many opportunities for examining the brains of insane patients, tells me that he found hardening, nearly as frequently as softening, in these cases, and never could tell beforehand, with certainty, which condition might be present.

In hardening of this organ, its density may be increased to that of boiled white of egg, or it may approach in consistence to that of a brain that has been hardened in alcohol, losing much of the sticky, adhesive character when broken up by the fingers, which marks the brain substance when in its normal state. The cause of the change is not well known, yet it is conjectured to be one of the results of inflammation, inasmuch as it is generally found with its capillaries greatly loaded with blood, while more or less fluid is found beneath the arachnoid and in the ventricles. The induration may affect the greater part or even the whole of the cerebral mass, or may be confined to particular portions or regions.

In a case recently examined for Dr. Toothaker, of this city, where insanity of some years' duration, and finally death, had followed a severe injury of the head, the brain was found so hard as to permit of fracture in the direction of the fibres, thus readily tracing their course.

The symptoms that have most frequently been observed to accompany this change are, defect and gradual loss of memory, apathetic indifference, slight difficulty of articulation, followed by loss of sexual desire, partial palsy, fatuity, wasting and death.

Extreme induration is often found in the brains of idiots. The whole organ may be found resembling in color and density boiled white of egg, or even cheese. The cerebral substance is shrunken, dense, and apparently quite void of vessels.

Hypertrophy of the brain, is a condition in which there is usually increased hardness as well as increased volume, and is distinguished by flattening of the convolutions, narrowing of the ventricles, and a remarkable dryness of the whole organ with its membranes, the change involving both the cerebrum and cerebellum, and accompanied with an increase of weight, all indicating increased nutrition, or the deposit of new matter in the tissue of the brain. Thinning of the cranial bones may attend this condition, increased internal pressure resulting in their partial absorption.

The causes of this form of disease are not generally understood. The symptoms, though always present, are not uniform. Among them may be mentioned intense headaches, a weakened or perverted state of the intellectual faculties, fits of giddiness, accompanied with stupor; finally, convulsions, with perhaps loss of sensation and motion, the patient being unexpectedly cut off by an epileptic attack. The disease has not been observed in persons over fifty. In most cases, the patients were between twenty and thirty. In one instance, however, it was developed in a young girl of thirteen. Lead poisoning would seem to be an exciting cause, it having, in several instances, been developed in painters and manufacturers of white lead.

Atrophy. In this condition, there is found a general diminution of the volume of the brain, and especially of the convolutions. The latter are shrunk, narrow, and sometimes softened, while the sulci are large and open, the brain receding from the skull, and the pia mater greatly injected with serous fluid, giving the appearance of a jelly-like investment to the whole brain.

The brain substance is at the same time soft, the ventricles enlarged and filled with fluid, while a large amount of serum will flow from the subarachnoid space at the base of the brain, and from the spinal canal.

While this condition of the brain might be looked upon as a result of pressure from the accumulated serum, the absence of the usual symptoms of hydrocephalus, with the known history of these cases, renders it quite probable that the change commences as an actual loss of brain substance, the place of the latter being supplied with serous fluid.

Resulting from atrophy of the brain, there will often be found an increased thickness of the cranial bones, this being another conservative effort of nature to preserve the normal support and pressure upon the brain.

Atrophy of the brain is sometimes found in old age and in various enfeebling diseases, where all the organs suffer more or less waste from improper nutrition, but it is so frequently found with drunkards, especially those who have died with *delirium tremens*, that this condition may, in the large majority of cases, be considered as the effect of intemperance.

Several forms of atrophy may also be observed. It may be confined to some portion of the convoluted surface, or to one of the striated bodies or optic beds. Atrophy of the optic tracts, or nerves of one or both eyes, is not unfrequently associated with loss of sight from amaurosis.

Tumors of the Brain.

The brain, like other parts of the body, is subject to morbid growths of a great variety of forms. The symptoms of tumors in the brain, in many points, present such resemblances to other forms of disease, that it is usually the post-mortem alone, that will determine the fact of their presence or character. It may be said in general, however, that the effects of morbid growths in the brain will vary according: 1. To the changes in the surrounding cerebral substance. 2. To the size of the growth; and 3. To the position of the brain in which it may be developed.

1. The changes induced in the brain substance surrounding tumors are usually, first, derangement of the circulation, and second, as a result of this, effusion of serum, or finally, softening of a greater or lesser amount of contiguous cerebral substance. Head-ache, with epileptic attacks, loss of memory, irregular contraction of the muscles and partial paralysis may accompany the vascular derangement, while as softening or pulpy destruction supervenes, a general aggravation of all the symptoms will follow, ending in death, either with coma or by a sudden apoplectic attack.

2. Tumors of the brain of a *small size*, may be found after death from other causes, that have evidently produced no symptoms during life; and in other instances, they have induced no change until a few days before death, in which cases, the convulsions, paralysis and coma which precedes this result, must be attributed to the vascular disturbance in the surrounding brain tissue.

3. The position of the tumor, will modify to some extent the character of the symptoms manifested. When in the anterior lobes, loss or impairment of speech is said to attend. While, when in the *corpus striatum*, the motions of the legs and arms are disordered.

The following are the more commonly recognized tumors of the brain:

Adenoid, or Glandular-like Tumors. These are generally described as resembling an enlarged lymphatic gland, both in color and density. They may vary in size from a filbert to that of an orange. There may be a single growth of this kind, or several, and they may be found in any part of the brain.

Tubercular or Scrofulous Tumors. Under this head may be placed certain bodies of a white or pale yellow color, firm, like soft cheese, sometimes granular and friable, and consisting chiefly of a large proportion of albuminous matter. They may be found first, as one or more individual masses of considerable size; or second, sometimes as many minute rounded bodies, distinct and separate from one another.

In examining the head of a hydrocephalic child of four years, with Dr. von Tagan, we found attached to the underside of the middle lobe of the left hemisphere, a body of a white cheesy consistence, and of the size of half a hen's egg. Connected with the cerebellum, was another tumor of the same character, but smaller in size.*

Tubercular masses of this kind, may be found on the surface, or imbedded in the substance of any portion of the cerebrum or cerebellum.

The second form of tubercular deposits, are confined almost wholly to the gray matter of the surface. In one case, over two hundred of these bodies were found scattered through the gray matter of the cerebrum and cerebellum, of the size of a pea or bean, and of a pale yellow or bluish color. When cut open, the interior of the bodies was found to resemble boiled potatoes in consistency.

---

* See No. 1386, Case T, College Museum.

This form of disease is confined principally to children. Of thirty cases collected by Dr. P. H. Green, of London, all were between the ages of nineteen months and twelve years.

Adipose Tumors. Under this name, has been described a peculiar and quite rare form of disease of the brain, in which either some portion of the brain itself, or growths attached to or imbedded within the cerebral substance, present a fatty appearance, which by some has been denominated *lardaceous degeneration.* The exterior of the tumor is smooth, of a yellow color, and the interior composed of adipose matter of ash color, and semi-solid consistency.

Cholesteroma. This is another rare form of tumor of the brain, consisting of white pearl-like, glistening bodies, varying in size from that of a pea, to a walnut or small orange. They are found mostly at the back of the brain, and in the subarachnoid tissue. When examined chemically, the substance of these tumors is found to consist almost wholly of cholesterin.

Cartilaginous Tumors. These are often spoken of as *scirrhus* in their nature. They may be described as irregular in shape, sometimes lobulated, the interior yellowish in color, of a cartilaginous hardness, and arranged sometimes in streaks or bands, in other cases, in rounded masses. At a more advanced stage, from softening of the interior, cavities begin to form, which are filled with a semi-fluid or jelly-like substance. Death will generally ensue before this process is far advanced.

Calcareous or Bony Deposits. *Osseous* formations are not unfrequently found connected with the membranes of the brain, but rarely, if ever, with the brain substance.

Calcareous deposits, on the other hand, have been found in almost every part of the brain. In the brain of an idiot of sixteen, the pons Varolii, crura cerebri and cerebellum, contained so much earthy matter, as to give difficulty in cutting with a knife, (*Sir E. Home.*) In the brain of a man who had long suffered from acute pain in the head, a hard plaster-like concretion was found as large as a filbert.

These bodies are, therefore, not to be looked upon as genuine bony formations, but rather as an infiltration of chalky substance into the brain tissue. Of the same nature, are the calcareous deposits found in the pineal gland, which, although very constantly present after the age of eight or ten years, can hardly be considered as normal products, although it is well established that they exert no influence on the functions of the brain.

Encysted Tumors, Hydatids. A variety of tumors of the encysted form have been found in the brain by different observers, varying in size from a pea, to that of an egg or orange. Their contents also, have presented a great degree of variation. While some have been filled with the cheesy substance of the ordinary steatome, others have contained blood, a jelly-like, or even a limpid watery fluid.

It has been claimed by some, doubted by others, that the *animal hydatid*, the *cysticercus*, has been found in the human brain. Having unquestionably been observed in the eye, the heart, and other parts of the body, it may also, possibly, sometimes be found in the brain. This curious animal is now known to be but the larval form of one of the cestoid entozoa, the *Tœnia solium*. Its position in the brain, can only be accounted for, by supposing that the embryo, which in its first stage is very minute, by piercing the coats of the stomach, into which the egg has been taken with the food, enters a blood vessel, and being carried into the brain, lodges in some of the capillaries, the walls of

which it penetrates. Entering thus the brain substance, it develops into the second larval form, which consists of a small bag or cyst, filled with a limpid fluid. Developed within the cyst, yet capable of being thrust out, is the head, which presents four sucker-like processes, surrounded by a circle of minute hooks, which give it the power of active migration through the tissues. In the pig, the presence of these cysticerci constitutes measly pork, which if taken into the stomach in a raw state, the contained larvæ at once develop into the perfect worm, the *Tænia solium.*

Blood Cysts, though not common, have been found in the brain. They consist of a membranous cyst, which may be lobulated or contain smaller cysts, the inner surfaces of which are lined with a vascular membrane, from which escapes a bloody fluid.

Cancerous Tumors may be found in any portion of the brain, and may present the several varieties of these malignant growths, including *fungus hæmatodes.* While they are generally secondary with similar tumors in other parts of the body, they may be primary in their origin. They may acquire such a development as to cause absorption of both the dura mater and skull, and thus appear upon the outside of the head. In *fungus hæmatodes*, the enclosed substance consists of soft spongy matter, of a brain-like consistency, divided into lobular masses, of a reddish shining aspect. They are mainly found in young subjects, sometimes in adults.

Melanosis. This form of morbid growth is occasionally found in the human brain. The middle lobe of the left hemisphere of the brain of a subject in the dissecting-room, was found to be attached to the dura mater by a melanotic

mass, resembling the dark bodies frequently found around the bronchial tubes. Its attachments were such as to render it doubtful whether it had its origin in the brain or in its membranes. The gray substance of the brain of persons who have suffered malarial diseases, is sometimes found presenting a blackish appearance from the dark pigment within its substance, or within the pia mater.

Syphilitic Tumors are occasionally found in the brain, situated near its surface. Their characters are not such as to permit of their ready recognition, except when associated with syphilitic growths in other parts of the body. They may vary in size from a pin's head to a cherry. They present a rounded or irregular form, a yellow color, and are composed of spindle-shaped or round cells, which may undergo a cheesy degeneration.

Obstruction of Cerebral Arteries. Patients suffering from endocardial inflammations, or from aneurism of the arch of the aorta, or from any cause having fibrinous deposits forming in the heart, are liable to have the same washed along the carotids, and thus carried into the vessels of the brain, thereby deranging the circulation through this organ. The symptoms resulting, are generally those of apoplexy. Hemiplegia, with or without loss of consciousness, follows. Softening of the cerebral substance follows as a result of the accident, and it is not impossible but that the presence of these bodies is the general cause of this structural change of the brain.

The position of the embolus, in fatal cases, is usually in one of the middle cerebral arteries; these vessels being in a more direct line with the internal carotids. They may lodge, however, in the vertebrals or basilar, yet through the circle of Willis, the several parts of the brain will still receive a partial supply of blood.

Atheromatous Degeneration, and Calcification of Cerebral Arteries. The coats of the arteries of the brain in old people, are liable to become infiltrated with atheromatous and calcareous matter to such a degree, as to render them rigid, and inelastic.

While the arteries of the base of the brain, as the basilar, the cerebrals, or the communicating of the circle of Willis, are more liable to this change, it may involve the smaller branches as well. The increased thickness of the coats of the vessels, results in a diminution of the calibre, while they are enlarged in external circumference.

Resulting from this state of the vessels, we shall have disturbed circulation, followed by effusion, and in some cases by atrophy of the brain. Attending this condition, are frequent attacks of stupor and insensibility, lasting for several hours or even days.

Again, from the weakened condition of the coats of the vessels in these cases, we may have an *aneurism* resulting, the walls of which suddenly giving away, death from hæmorrhage speedily follows.

Section IV. OF THE SPINAL CORD.

[**Notice** in examination. 1. *Vertebræ.*—Condition of several parts; caries, etc. 2. *Vertebral Canal.*—Proportion to cord; contained fluid; serum, pus or blood; amount, etc.; condition of spinal veins. 3. *Membranes of cord.*—Bulging of any part; thickening; congestion; morbid growths, etc.; fluids within; amount, color, etc. 4. *Spinal cord.*—Weight; size; condition of fissures; of interior, as seen on section; softening; exact point of; roots of nerves; pressure upon, etc.]

From the continuity and identity of structures, the spinal cord is subject to essentially the same diseases as those of the brain.

1. The Membranes.

Inflammation of the latter may exist alone, or in connection with that of the membranes of the brain, constituting

cerebro-spinal meningitis. Inflammation of the dura mater is an uncommon occurrence. The inflammation in spinal meningitis is almost wholly confined to the pia mater, this being the more vascular of the membranes. A pale reddish, or sometimes purple color, with a bloody jelly-like infiltration, characterizes the earlier stage, while at a later period the membrane presents a greyish or dirty yellow appearance, from the presence of a thick pus-like substance covering the surface. Such inflammations may be either idiopathic, rheumatic or traumatic in their origin.

In *spotted fever* the inflammation extends to the pia mater of the base of the brain, and is remarkable from the epidemic form which it sometimes assumes.

Tubercular deposits, as well as *tumors* of various kinds, may be found connected with the spinal membranes, so similar to those described with the cerebral membranes, as not to require separate notice.

Serous effusion may be found in the spinal canal, in the same cases when it exists in the cranial cavity, and may be either a diffusion of fluid through the sub-arachnoid space, that has been effused in the brain, or it may originate from the membranes of the cord itself. The fluid may be either between the vertebræ and dura mater, or between the latter and the pia mater.

A peculiar form of dropsy of the spine is sometimes found, congenital in its nature, and accompanied with a deficiency in the spinal column, by means of which a cleft remains in the arch of one or more of the vertebræ; hence the name, *Spina bifida*, as applied to this disease. The effusion in these cases, taking place before the vertebræ are fully developed, the pressure from within prevents the final closure of the canal posteriorly; when, from want of support at that point, the membranes and covering tissues, yielding to the pressure from

the accumulating fluid, gradually protrude at that point, producing a rounded fluctuating tumor. The disease is more frequently found in the lumbar region, although it may occur in the dorsal or cervical, and in some cases may involve the whole spinal column.

2. Spinal Marrow.

Inflammation of this structure, (*myelitis*,) presents the same character, and may be followed by the same results as inflammation of the brain. From the distension and engorgement of the capillaries of the inflamed part, a bright red color may be presented, not only on the surface, but in the substance of the cord when exposed by division. Blood may also be found effused in the substance of the cord, or between its membranes, or between the bony walls and the dura mater.

Softening of the spinal cord, may arise either spontaneously, or as a consequence of injury. When spontaneously taking place, a large portion of the cord may be involved. The appearance presented, is most usually that of a soft pulpy mass, which easily breaks down upon the opening of the membranes. When the result of injury, the softening is generally confined to the portion involved in the original violence.

Hardening of the spinal marrow, (*sclerosis*,) may be one of the results of inflammation, yet the accompanying symptoms may vary so slightly from those of other forms of spinal disease, that the post-mortem alone, will disclose the true nature of the difficulty. In *locomotor ataxy*, the posterior columns of the cord are usually affected with this change.

Atrophy of the spinal cord, differs from hardening, in the *shrinking* which attends the progress of the disease, although there may be increased density, as in the former case. The essential peculiarity of atrophy, consists in an increased development of the fibrous elements of the cord, which by pressure, gradually destroys the elementary nerve constituents. This disease is confined chiefly to men of a middle age, and is generally the result of venereal excesses; muscular over-exertion, exposure to cold, &c., may also be exciting causes.

Morbid Growths, of various kinds, and closely resembling those found in the brain, as well as *animal parasites*, are sometimes found in the spinal cord.

PART II.

THE NECK AND CHEST.

CHAPTER I.

OPERATION ON THE NECK.

THE parts which we may wish to examine in the region of the neck in a post-mortem examination, include the tongue, the larynx, the trachea and the œsophagus. These may be removed together, by first making a single, straight incision from the chin, down the central line of the neck to the sternum. Next turn aside the integument with the superficial structures, separate the muscles of the tongue from their attachment to the jaw, and divide the mucous membrane of the floor of the mouth on either side of the tongue, when, with the tenaculum, the latter may be drawn down beneath the jaw. The neck being well extended and the tongue forcibly drawn down, the knife may be carried back on either side of that organ, dividing the muscles and mucous membranes, including the palatine arches and tonsils, when the tongue may be so drawn down as to permit the knife to reach the posterior walls of the pharynx. This being divided, from the slight adhesion to the spinal column, the whole may now be drawn down and removed together, the trachea and œsophagus being divided at the upper end of the sternum.

By the use of the enterotome, the pharynx, larynx and trachea may be laid open from behind, which will fully expose their interior for careful examination.

After the examination of the parts is completed, if it is desired to preserve the specimen, the cavity remaining may be so filled with paper or rags, as, upon the closing of the part, to leave little or no evidence of the absence of any portion.

Through the mouth, the buccal cavity may be examined, when there may be noted the condition of the teeth, gums, tonsils, palate, etc.; the presence or absence of ulcers on any of these parts, or of food or other foreign substances within the cavity.

OPERATION ON THE CHEST.

In opening the thoracic cavity for an examination of its contents, a straight incision may be made along the central line, through the skin and superficial tissues, from the upper end of the sternum, to near the umbilicus. If it is desired to examine the abdomen at the same time, the incision may be carried on to the pubis; otherwise, ending just above the umbilicus, a transverse cut may be carried from its lower end, to the border of the chest upon either side. These incisions being carefully carried through the muscles and peritoneum, the flap thus formed may be lifted and turned up upon the chest, and the peritoneum divided along the cartilages of the ribs. The integument with the pectoral muscles may now be dissected up together, and turned back as far as the union of the cartilages with the ends of the ribs. With the heavy cartilage knife, the former may now be divided near their union with the ribs; care being observed not to permit the knife to pass into the chest, and thus injure the lungs. In aged persons, and sometimes in the middle aged, the cartilages will be found so ossified, as

to require the use of the saw or chisel in the place of the knife; this being more frequently required with the first ribs, than with any other. The ligaments uniting the clavicle with the sternum, having been divided, the latter may be removed by commencing at the lower end, and separating the diaphragm from its connections to the sternum and costal cartilages. The sternum being now lifted from below, the mediastinum may be divided, this forming the only bond of union to the parts beneath, except in cases, where, from pleuritic inflammation, adhesions may exist between the lungs and costal cartilages.

The sternum having thus been removed, the lungs will be found more or less collapsed from atmospheric pressure, unless adhesions be so extensive as to prevent.

The attention may now be given to the pericardium and heart. By making a small opening into the cavity of the former, any dropsical fluid present may be removed and measured. This may be accomplished, by introducing the point of a syringe into the opening, and carefully drawing the fluid into the same, and then forcing it into some vessel. Or, it may be carefully absorbed by a sponge, and then squeezed out and measured.

The *heart* may be removed for examination, by dividing the large vessels springing from its base. In examining the cavities, valves, &c., the right auricles should first be opened, by an incision along its base, another meeting this at right angles, thus making two angular flaps, which may be turned aside, exposing the interior. In opening the ventricle, let one incision be made parallel with, and about one-third of an inch from the groove in the anterior surface dividing the right from the left ventricle, commencing at the base and extending to the apex; and another along the posterior groove, meeting the former at the apex, thus making a triangular flap, which may be lifted, exposing the interior of the cavity, without injury to the tendonous

cords. The semilunar valves of the pulmonary artery may readily be exposed, by splitting open that vessel, and turning aside its walls. The left side of the heart may be examined in the same manner.

The examination of the *lungs* may often be made *in situ.* Deep incisions may be made into their substance at various points, or portions may be removed for examination. If a more careful inspection is desired, or if we wish to examine the bronchial tubes or aorta, the whole thoracic viscera may be removed together. To accomplish this, divide the trachea and œsophagus, as they enter the chest, with also the branches arising from the arch of the aorta. Carry the hands around either lung, breaking up any adhesions which may be found, and then by grasping the trachea and arch of aorta, and dragging down upon the same, the posterior mediastinum may be divided from above downwards, the aorta and œsophagus divided as they pass the diaphragm, and the whole of the contents of the chest thus removed *en masse.* Placed upon a large tray, they may now be examined in detail. The bronchial tubes may be best inspected from behind, laying open the passages with the scissors at their posterior walls. By means of deep incisions, extending from apex to base upon the anterior surface, the condition of the interior of the organs may be carefully noted.

The examination completed, all blood should be sponged from the cavity, the organs replaced, and any remaining vacancy filled with bran or saw-dust. The sternum now being placed in position, the incision may be sewed up.

CHAPTER II.

PATHOLOGICAL CONDITIONS.

Section I. OF THE TONGUE.

[**Notice** in examination: size; form; surface coated or clean; furrowed or fissured; marks of bites, stains; color generally; vesicles; ulcers; sloughs; tumors, wounds, etc.]

THE diseases of the tongue, the appearance of which we may wish to examine after death, include *cancer, syphilitic ulcers or tubercle, tumors, hypertrophy, etc.*

Cancer is the only disease of this organ likely to result in death. It is said to occur more frequently in females than males. It may assume the various forms of this disease, but is more frequently epithelial or scirrhus, than medullary.

Syphilitic Ulcers or Tubercle, may be confounded with cancer, and in some instances, only a previous knowledge of the history of the case, assisted by a microscopic examination, would positively determine the diagnosis.

Tumors of various kinds—encysted, fatty, fibrous and erectile—may be found in the substance of the tongue, or underneath it in the floor of the mouth.

Ranula is a peculiar form of tumor found under the tongue, often attaining the size of a pigeon's egg, and filled with a watery or albuminous, or sometimes cretaceous matter. The tumor is usually considered as arising from a dilatation of Wharton's duct, but of this there is doubt in some cases.

Hypertrophy of the tongue is sometimes found, where, from an increase of the connective or areolar tissue, without any change in the muscular fibres, the organ has become greatly enlarged, so as to cause deformity of the mouth, or even of the whole lower part of the face. This condition may involve the whole or a portion only of the tongue.

Section II. OF THE LARYNX AND TRACHEA.

[**Notice** in examination: 1. *Contents*—mucus; lymph; pus or blood; amount; foreign bodies; false membranes, etc. 2. *Larynx*—condition of epiglottis; œdema, ulcers, sloughs, polypi; same of superior opening to cavity. *Ventricles*—condition of mucous membranes, etc. *Vocal Cords*—thickness, color, œdema, ulcers, etc. *Cartilages*—condition of; ossification; caries, etc. 3. *Trachea*—contents; mucous membrane; cartilaginous rings; ossification of; caries; denuded of mucous membrane, etc.]

Inflammation, ulceration, œdema, necrosis of the cartilages, tumors and *false membranes* are the more usual pathological conditions of these parts that may claim the attention in a post-mortem examination.

Inflammation of the mucous membrane of the larynx (laryngitis) and trachea, will appear as a diffused redness, with some thickening of the membrane, and within which may be traced many *small, congested blood-vessels.* It may be important to distinguish the redness of inflammation, from that attending the early stage of decomposition, which, it is an interesting fact to know, first appears in these parts. Immediately after death, the mucous membrane is *pale,* except in death from suffocation or laryngitis. In a day or two it becomes of a dusky red, which is distinguished from that of inflammation by *the absence of congested vessels;* the redness of decomposition, also, having a superficial filmy appearance, as if washed with dirty wine.

Ulceration of the larynx commences in the mucous membrane, but may extend to the deeper parts. The more usual location is upon the epiglottis, or on the margin of the glottis and vocal cords. Impairment of the voice to a greater or less degree, will have attended either inflammation or ulceration of the vocal cords. It is to be borne in mind, however, that aphonia may arise from some impairment of the nerves of the larynx, in which case, a post-mortem examination will fail to reveal any morbid condition of the mucous membrane or vocal cords.

Pulmonary consumption we sometimes find accompanied with the presence of ulcers upon the posterior walls of the larynx, with evidence of inflammation in the surrounding parts. Whether these arise from tubercles in the mucous membrane, or ulceration of the mucous follicles, is uncertain.

Œdema of the larynx, is attended with great swelling of the mucous membrane, from serous effusion into the submucous tissues, and frequently attends chronic inflammation of the parts, with ulceration. It may, however, be of an erysipelatous character, occurring as the result of exposure to infection. The surface appears red, pulpy and swollen, from infiltration of the submucous tissue. Œdema of the larynx, is confined to the parts around the epiglottis, and margins of the glottis, never descending below the true vocal cords, owing to the close adhesion of the mucous membrane to the fibrous structure of the cord, without any intervening areolar tissue.

Necrosis of the Cartilages of the larynx, may occur in the advanced stage of laryngitis with ulceration. In this manner the epiglottis, with the arytenoid, the cricoid, and even thyroid cartilages may, to a greater or less extent, be destroyed.

Abscesses may also form, where the cartilages are so much involved, these in some cases breaking upon the outside, and establishing fistulous communications through which air may escape during respiration.

Tumors of the larynx, may be found *first*, outside of the cavity, imbedded in some portion of its tissues; and may include encysted, fatty or fibrous tumors; or, *second*, they may be found in the interior, springing from the mucous membrane, and resembling polypi in their form and structure. They are sometimes granular or cauliflower-like in appearance, and vary in size from a pea to a hazel-nut.

False Membranes may be found in the larynx and trachea in fatal cases of croup or diphtheria. In croup, the membrane adheres but slightly to the mucous structure beneath, which will be found red and congested, but may form a complete tubular lining to both larynx and trachea, extending also into the bronchial tubes.* It is usually tougher in the larynx and upper portion of the trachea, becoming softer and more gelatinous in the lower portion of the trachea and bronchial tubes. Much difference of opinion has been entertained as to the nature of this substance. It may, however, be considered as a morbid secretion from the inflamed mucous surfaces, in a semi-fluid form, which, in consequence of the presence of albuminous matter, coagulates upon exposure to air.

The false membrane of croup may generally be distinguished from that of diphtheria by the fact, *First*, That the latter is usually confined to the fauces, sometimes extending to the larynx, rarely to the trachea. *Second*, That diphtheritic membrane occurs more in patches, is tougher, is more directly incorporated with the mucous surface beneath, and

* See No. 1295, Case R, College Museum.

is removed with more difficulty. *Third,* A microscopic examination shows the membrane to be composed mainly of fibrine in a fibrillated condition, with granular corpuscles and pus cells.

Section III. OF THE PHARYNX AND ŒSOPHAGUS.

[**Notice** in examination: displacements; their cause, as by tumors, etc.; dilatation; contraction or stricture, seat of; calibre at stricture; above, below; condition of mucous membrane; ulcers, etc. Contents of œsophagus; food, foreign bodies, wounds.]

These parts are liable to *inflammation, ulceration, stricture, dilatation* and *new growths.*

Inflammation of these passages, rarely occurs, except as the result of mechanical injury, as from the lodgment of a foreign body, or from swallowing some caustic or highly irritating substance. Catarrhal or croupous inflammation of the mouth and tonsils, may, however, involve a portion of the walls of the pharynx.

Ulceration may result from the same causes, and hence may be confined to a small portion or may involve the greater part of the tube.

Stricture of the œsophagus may be either *spasmodic* or *organic.* The former usually occurs in hysterical women, and may result from the irritation following the removal of some foreign body lodged in the canal. Never proving fatal of itself, we seldom have the opportunity of examining a case of this kind.

Organic stricture is found usually at the commencement of the canal, sometimes at its lower end. It may result from contractions attending the healing of an ulcer, but is more frequently induced by a cancerous affection of the walls, or

by the projection of some morbid growth into its interior, as from aneurism of the aorta, or tumors, abscesses, &c., in the lungs or left lobe of the liver.

Dilatation of the œsophagus may result from the presence of stricture. When the latter is near the cardiac orifice of the stomach, the entire length of the tube may be involved. The walls in these cases may be either thickened or thinned. From the accumulation of food above the point of stricture, the walls gradually yield to the distending force, until a degree of dilatation is attained that is quite remarkable.

Tumors of various kinds are occasionally found within the walls of the pharynx or œsophagus, including cystic, fatty and fibrinous tumors of a polypoid form.

Malignant or cancerous growths may appear in any part of the tube, the epithelial form being more common. Beginning in the submucous tissue, the disease will soon involve the whole circumference of the tube, to the extent of from one to three or four inches, producing a hardness of the tissues with more or less contraction. Ulceration ultimately taking place, a dilated cavity may take the place of the original stricture.

Section IV. OF THE PERICARDIUM.

[**Notice:** 1. *External characters*—shape; measurement; amount of fat, etc. 2. *Contents*—serum; quantity; color; how affected by heat; blood; quantity; character; source. 3. *Internal surface*—adhesions; their position, extent and character; as firm, soft, etc.]

THE pericardium is subject to the same affections as other serous membranes, including *inflammation, adhesions, effusions* or *morbid growths.*

Inflammation of the pericardium or *pericarditis*, is characterized by an unusual dryness of the surface, with

injection of the vessels in the early stage, while at a later period a layer of plastic lymph will be found adhering to the surfaces. The deposit may be limited to some small portion, or be distributed over the whole inner surface of the membrane and upon the exterior of the heart, giving them the appearance of having been smeared over with some sticky substance. Often the surfaces are rough or villous in appearance, like the mucous membranes of the intestines. Irregular calcareous patches are sometimes found in old chronic cases, developed within the thickened portions of the membrane.

Adhesions may also form between the surfaces in contact. The whole cavity may in this manner become obliterated, or bands of adhesion may be found here and there.

Effusions may be found in the pericardium, as in other serous cavities. When the result of *pericarditis*, the fluid will often contain floating shreds of lymph. Sometimes the fluid will be found highly albuminous, and again bloody or mixed with pus. This effusion may have taken place so early as to have prevented any adhesion of parts; or it may not have commenced until union had taken place at certain parts, when, from the distension of the sac, these bands may be found greatly elongated, and stretching across the cavity in various directions. When the effusion is but part of a *general dropsy*, it will be clear, while the surfaces of the membrane will be smooth and destitute of evidences of inflammation. In quantity, the fluid found in these cases may vary from a few ounces to a pint or more.

Blood may sometimes be found filling the pericardium, either from a wound of its walls, rupture of the heart, or from the bursting of an aneurism. In scurvy, purpura, etc., small patches of extravasated blood may be found in its walls.

Morbid Growths. The more common of these, found in connection with the pericardium, are *cancers*. They are usually secondary in their appearance, and generally will have first developed in the mediastinum.

Fibrous or *cystic* tumors have been noticed in a few rare cases, while *tubercles* of the miliary form, are not uncommon within this membrane.

Section V. OF THE HEART.

[**Notice:** 1. *In situ*—exact position and relation to surrounding organs; shape; size; degree of firmness or flabbiness. 2. *After removal*—amount and kind of blood discharged from divided vessels; shape of heart; round or elongated; apex formed by which ventricle; amount of fat on surface; relative size of each cavity. 3. *Right auricle*—character and quantity of blood contained; fibrinous clot. Lining membrane; general condition of; foramen ovale; open or closed; thickness, consistence, etc., of muscular walls. Auriculo-ventricular opening; its shape; estimate of size by introducing fingers; rough or smooth; fibrous or calcareous deposits; circumference. 4. *Right ventricle*—nature and quantity of contents; fluid blood; blood clot; fibrinous clot; size; attachments of same to muscular columns; firm or soft; size of cavity; thickness and condition of muscular walls; color, firmness, etc. 5. *Tricuspid valves*—natural, thickened, thinned or contracted; granulations; patches of calcareous matter; degree of flexibility; can they close the opening? Condition of chordæ tendineæ; length, thickness, flexibility, rupture, etc. 6. *Pulmonary opening*—size and shape; smooth or rough. Semilunar valves; thin and smooth, or thick, rough and inflexible; power of closing the opening; will water pass through when poured in from above? 7. *Left side of heart*—observe same as on right. 8. *Generalities*—weight after removal of blood; wounds; morbid growths; abscesses; malformations; aneurism; rupture, etc.]

The several morbid conditions of the heart may be classified as follows:

1. Inflammation	of muscular walls.	Carditis.
	of serous membranes.	Pericarditis. Endocarditis.
2. Diseases of valves.		Thickening. Ossification. Atrophy.

3. Changes in the walls of the heart, influencing the size of the cavities.		Hypertrophy. Dilatation. Atrophy.
4. Morbid conditions of the walls alone.		Fatty degeneration. Morbid growths. Ossification of coronary arteries. Malformations. Abscess. Aneurism. Rupture.
5. Displacements.	Congenital. Pathological.	Ectopia cordis. Transposition.
6. Contents of cavities.		Heart clots.

1. Inflammatory Affections.

Carditis. Inflammation of the muscular substance of the heart is by no means a common disease, and when present, is probably always associated either with endocarditis, or more frequently pericarditis. We may recognize this condition after death, by the light yellow color of the heart; with a relaxed, flabby, and in some instances a softened condition of the walls. Upon cutting into the muscular walls, there will be found exuding a semi-purulent fluid, and often small cavities, varying in size from a pin's head to a small pea, will be found filled with pus. This condition may involve the whole heart, or may be confined to one or more portions. Inflammation of the muscular substance of the heart, may, undoubtedly, be one of the primary causes leading to aneurism or even to rupture. The symptoms of this disease are not readily recognized during life, being always combined with inflammation of the peri- or endocardium.

Pericarditis. Affections of the pericardium have been noticed in the previous section.

Endocarditis. Inflammation of the lining membrane of the heart (*endocardium*) most frequently occurs in connection with an attack of articular rheumatism. It may, however, result from blows or injuries of the chest, and has been induced by violent muscular efforts. It is said also, to be often connected with some vitiated condition of the blood, as in pyæmia or Bright's disease of the kidneys, and has been noticed also in cases of measles, typhus and puerperal fever.

Endocarditis more frequently attacks the left, than the right side of the heart. The anatomical appearances, are a loss of smoothness and transparency of the membrane, with an injected condition of its vessels. Deposits of lymph may be found adhering to the free surface at various points, or to the tendinous cords or valves, giving a roughened, or even warty appearance to all those parts. These may become detached, and swept on with the blood, and finally lodging in some of the arteries of the head or extremities, where they are known as *emboli*, they may become a source of serious trouble. The inflammation may extend to the muscular structure, resulting in softening or the formation of purulent cysts.

It is, however, upon those folds of the lining membrane constituting the valves, and particularly upon the left side of the heart, that the effects of endocardial inflammations are especially manifested. In this way originates most of the so-called

2. Valvular Affections of the Heart.

One of the most common of the results of inflammation extending to the valves, is

Thickening. This may depend either upon a deposit of lymph beneath or between the layers of membrane constituting the valves, thus rendering them thick and inflex-

ible while the surface is left smooth, or, at the same time, a deposit upon the exterior may be found, rendering them rough and even warty in appearance, and so stiffened and irregular upon their borders as to greatly interfere with the performance of their functions, and thus permitting *regurgitation* to take place at the imperfectly closed opening.* The tendinous cords, at the same time, may be found thickened, hardened, and contracted, or even ruptured, while the auriculo-ventricular openings may also be found greatly contracted from the thickening of the base of the valves and the fibrous tissues forming the borders of the openings. In one case the contraction on the left side of the heart was so great as scarcely to admit the little finger, while the thumb should readily pass that opening.

The semilunar valves of the aorta are liable to the same changes, their thickened condition preventing their folding back completely into the sinuses of the artery during the systolic action of the heart, or of completely closing the vessel upon pressure from above.

Calcification. This condition of the valves may result from a progressive change from simple thickening with fibrinous deposits, to a cartilaginous state, accompanied with so-called bony, or more properly *calcareous* patches, which may involve large portions of the valves. Ossification of the valves upon the right side of the heart, is but rarely found; upon the left, both the mitral and aortic valves are liable to this affection.

Atrophy. The aortic, pulmonary, and sometimes mitral valves, are occasionally found greatly thinned; and this condition may result either in a gradual stretching of the central portion of the valve from pressure of the blood,

---

* See No. 1385, College Museum.

giving rise to *aneurism* of the valves, or, it may become *perforated* with small irregular openings, or, from its weakened condition, *rupture* may take place, producing sudden death. This condition appears to consist in a gradual wearing away of the substance of the valves, from unusual brittleness of their structure, the result probably of chronic inflammation.

Again, the valves may be found greatly contracted, (*stenosis*) hard and rigid, which will be attended with imperfect closure and consequent regurgitation. Dilatation of the orifices without any change in the valves, may also be found, resulting in the same imperfect closure.

Disease of the valves of the heart, by obstructing the orifices, is likely to result in

3. Changes Affecting the Size of the Cavities.

Hypertrophy. Hypertrophy of the heart, is a condition in which there is an increased thickness of its walls, and generally also enlargement of its cavities. Yet there may be thickening—very rarely however—with a diminution in the size of the cavities. It may affect both sides of the heart, but is frequently confined to the left ventricle.

The main cause of hypertrophy of the heart, is the existence of some obstruction to the circulation, either in the heart, or some portion of the arterial system, as by aneurism, pressure of tumors, etc., or by disease of the kidneys. It is most frequently, however, associated with disease of the valves or large arteries. It may sometimes result from continued functional excitement, and generally accompanies cases of partial adhesion of the surfaces of the pericardium, while complete adhesion is more likely to be followed by dilatation or atrophy. On the right side of the heart, hypertrophy is usually the result of some obstruction to the circulation through the lungs, as in an emphysematous condition of that organ.

The following measurements, &c., of the normal heart, will serve as a guide in judging of cases of enlargement:

Size. Lænnec has stated, that the heart in its normal condition, is about the size of the closed fist of the individual. This comparison, however, is not very satisfactory. It will be usually found to measure about 5 inches in length, 3½ in its greatest width, and 2½ in its extreme thickness, from its anterior to its posterior surface.

Weight. From an examination of four hundred cases, the average weight was found to be 9½ ounces in the male, and 8¼ ounces in the female. In a robust, muscular male, the heart may, however, be found to weigh as much as 12 ounces, and still be normal in all its parts.

Thickness of Walls. Right auricle, 1 line; left, 1½ lines. Right ventricle, 1½ lines, and left, a little over 5 lines, or half an inch, at its middle, being a little thinner both at the base and apex.

Size of Orifices. Circumference of auriculo-ventricular opening of the right side, nearly 4 inches; of left side, 3½ inches; of the pulmonary artery, 2⅝ inches; of aorta, 2⅜ inches.

When enlarged, the heart may be found measuring 6 to 7 inches in length, as much in breadth, and 12 to 16 inches in circumference. The weight may also be increased to 15, 20 or 25 ounces, and the walls may increase in thickness to nearly a-half inch, and upon the left to over an inch.

Hypertrophy of the heart, has been divided into three forms:—1st, *simple* hypertrophy; 2d, *eccentric;* and 3d, *concentric* hypertrophy.

In the first form, the walls are thickened, while the cavities remain unchanged. (Simple hypertrophy.)

In the second form, the thickening of the walls is attended

with an *enlargement* or *dilatation* of the cavities. (Eccentric hypertrophy.*)

In the third form, the thickening is attended with a *diminution* in the capacity of the cavities. (Concentric hypertrophy.)

It has been observed in cases where an examination has been made very soon after a sudden, violent death, attended with loss of blood, as in decapitation, etc., that the cavities have been nearly obliterated, while the walls were greatly thickened. By maceration for a few days, the ventricles have become relaxed to their natural size and capacity. This state of the heart has been observed in persons in whom, during life, none of the symptoms of disease of the heart had been manifested, and hence the condition is to be considered as the immediate effect of the peculiar character of the cause of death.

Dilatation. Dilatation of the cavities of the heart, is a condition which may also result from the presence of obstacles or impediments to the circulation, as from ossification of the valves; narrowing of the pulmonary or aortic orifices; employments requiring powerful muscular efforts; and in consolidation, tubercular induration, emphysematous condition of the lungs, or fatty degeneration.

The muscular substance is usually soft and flaccid, sometimes of a violet color, again pale and yellowish. The thinning may be so great, as to reduce the thickest part of the left ventricle to two lines or even less, when the walls will appear to be composed of but little more than a thin layer of fat covered with the pericardium.

Three forms of dilatation are recognized: *active, simple* and *passive.*

Active dilatation is associated with *hypertrophy* of walls, constituting eccentric hypertrophy.

* See No. 1387 College Museum.

In simple hypertrophy, the walls retain their *normal thickness*, while the shape may be changed according to the cavity affected.

Passive dilatation, on the other hand, is accompanied with *thinning* of the walls, and usually results from fatty degeneration, atrophy, or some other change in the muscular fibre.

Atrophy. In this condition there is a uniform decrease in the size of the heart. Its cavities becomes small, and its walls thin. It usually attends diseases accompanied with great impoverishment of the blood, as in cancer, diabetes, etc., or may result from obstruction of the coronary arteries from calcification, atheroma or thrombi.

Paget mentions a case where the heart of a cancerous man, fifty years old, weighed only five ounces, four drachms; and that of a diabetic woman, which weighed only five ounces, one drachm. It is usually accompanied with a general wasting of the tissues and organs of the body, and frequently will be found associated with fatty degeneration, which will now be noticed.

4. Morbid Condition of the Walls Alone.

Fatty Degeneration. Two forms of fatty diseases of the heart have been recognized. In the first, which should be known as "*fatty growth*," to distinguish from "*fatty degeneration*," there is an unusual quantity of adipose matter in those parts of the heart where more or less is usually found, viz.:—Along the furrows through which the vessels run, and particularly about the base of the heart. The fatty masses may dip more or less into the substance of the walls, displacing the muscular fibres, although the latter are generally normal in color and density, even when imbedded in masses of fat. This condition may be found in persons who are otherwise thin, as well as in the obese.

But the more frequent form of fatty disease, is that known as *fatty degeneration.* In this, we find upon opening the heart, that it has lost the reddish-brown color characteristic of the muscular fibre in its normal condition, and is pale, soft and flabby. The whole organ feels soft, doughy and inelastic, much like a heart beginning to decompose. If the wall of the left ventricle be partly cut through, the remainder is easily torn, and the surfaces have a granulated appearance.

Upon the inner surface, beneath the endocardium, numerous small thickly set spots, or sometimes wavy lines, of a pale buff, or light yellow color, may be noticed. This appearance does not depend upon a deposit of fat among the muscular fibres, but rather upon a change in that tissue; and an examination with the microscope, will show fatty degeneration of the fibre.

This condition of the heart, may involve the whole organ, or may be confined to one or more portions. It is much less common in the auricles, than in the ventricles, and more frequent in the left ventricle than in the right. It will be generally found more advanced in the upper portion of the septum of the ventricles, and in the large, fleshy columns of the left side; or it may be found in these columns alone, which accounts for the occasional rupture of the latter.

Fatty Degeneration may be associated with *fatty growth,* or with hypertrophy, or thinning and dilatation, and may be the cause of rupture. The general character of softness, paleness, and mottled color, should lead to *suspicion* of the existence of this disease, when a microscopic examination being resorted to, the conclusion would be decisive. A small portion of fibre, examined with a power of 300 or 400 diameters, will present, in fatty degeneration, instead of the striated appearance of the normal fibre, a granular appearance, with numerous minute oil globules scattered through the fibre. In the palest part of the heart, the disease will

be generally most advanced; but even here, the microscope will show some fibres in a healthy condition, while others around them are rendered completely granular.

Exhausting diseases of various kinds, typhus and other severe fevers, phosphorus poisoning, etc., may result in this peculiar condition of the heart.

5. Morbid Growths.

Under this head may be placed *tumors*, *cancers*, *melanosis*, and *hydatids*.

Tumors of various kinds are occasionally found in connection with the heart. *Fibrous* tumors of a small size may develop within the muscular walls, while *syphilitic* growths, *cysts*, and *tubercular* deposits may also, in rare cases, be discovered.

Cancer. Cancer of the heart has been noticed in two forms—*epithelial* and *medullary*. A man, fifty-eight years old, had an epithelial cancer of the eye, which was removed. Two years after, the man died with a large cancerous tumor over the parotid gland. A post-mortem examination revealed a cancerous mass, about an inch and a-half in diameter, imbedded in the apex of the right ventricle and septum of the heart. A microscopic examination revealed its epithelial character.*

Medullary cancer of the heart has been usually found associated with the same disease in the lungs and liver, and forms an investing mass which may involve the whole organ.

Melanosis of the heart presents the same character as in other parts of the body, and is considered but a variety of the medullary cancer, pigmentary matter being added.

---

* Paget's Pathology, p. 586.

It may be developed upon the surface, or may infiltrate the substance of the whole organ.

Hydatids have been occasionally found in the heart, the most of which have probably been animal in their character, (*acephalocysts.*) A female, forty years old, who had been suffering pain in the region of the heart for some months, suddenly died, after running rapidly up stairs. One ounce of fluid was found in the pericardium. A considerable tumor was found at the apex of the heart, which slightly fluctuated. This tumor was about three inches in diameter, globular in form, and encroached considerably upon the cavity of the right ventricle. When laid open, it was found to contain a large number of small cysts or hydatids, varying in size from that of a small pea to that of a pigeon's egg, the space between which was filled with a soft curdlike substance, of a yellow color.*

Ossification of Coronary Arteries. That condition of the arteries of the heart usually termed *ossification* is more properly one of *calcification*, consisting of a deposit of hard, gritty, calcareous matter, in which there is none of the true character of real bone, no trace of bone-corpuscle or vascular canals ever being discovered in them. Chemical analysis has shown the deposits to be composed of 50 parts of animal matter, with 47½ of the phosphate and 2 of the carbonate of lime in every 100. This matter being deposited in circular layers, the artery becomes gradually converted into a hard, bony-like tube, which may be traced with the finger along the grooves of the heart through which the coronary artery runs. This is peculiarly a disease of old people, and may accompany a similar condition of the arch of the aorta or of the semilunar valves, and by interfering with the proper

* Medico-Chirurgical Trans. xvii. p. 507.

nutrition of the heart may result in other forms of disease, as fatty degeneration, dilatation, &c.

Abscess. Abscess of the heart, may unquestionably follow an attack of carditis, or inflammation of the muscular substance. The cut surface of the heart in these cases, not unfrequently shows small cavities containing a purulent fluid, and in some instances a distinct abscess is found.

A man, sixty years old, was suddenly attacked, while at work, with coma and great feebleness, followed by death on the third day. The left ventricle being opened, an abscess was discovered near the apex, irregular in form, and containing a bloody, purulent-looking fluid. The coronary arteries were much ossified.

Malformations of the heart, are extremely rare in adults, or even in children that have passed the early days of infancy. They consist frequently in arrest of development of the auricular septum, or, in other words, of a patulous foramen ovale, which, by permitting of a mixture of arterial and venous blood upon the left side of the heart, results in early death. I have in several instances found this foramen imperfectly closed in the adult heart, but the opening has been so small—barely sufficient to permit the passage of a probe —as to offer little or no obstacle to the proper performance to the heart's function. Malformation of the heart is undoubtedly one of the many causes of death in utero, which might be demonstrated by a post-mortem examination.

Aneurism. Partial aneurism, or false aneurism of the heart, consists in the formation of a sac or pouch, in some portion of the walls of the organ, communicating with the cavity of the chamber, in the walls of which it has been formed. They may form in any part of the muscular walls of the heart, but are more frequent in the left ventricle.

They would seem to result from a separation of some of the muscular fibres, when, by their retraction, a cavity or pouch, of a rounded or oval form results, which, in some instances, has its walls composed of the pericardium alone, there being a complete destruction of the muscular fibres.

The interior of these pouches, may be found filled with layers of coagulated fibrinous deposits, as in the case of aneurism of arteries; or, if they communicate with the ventricular cavity by a large opening, they may be filled with a simple soft clot of blood.

The size of these aneurismal pouches, vary from that of a cherry, to a pigeon's egg, or larger, when they change much the usual figure of the heart, by their projection upon the external surface.

The following conditions have been supposed to favor the formation of these aneurismal sacs:—1st, softening of the muscular tissue of the heart; 2d, ulceration of the lining membrane; and 3d, rupture of the muscular fibres.

Rupture of the walls of the heart sometimes happens, producing sudden death. It may result from severe contusions of the chest, in which case, the auricles are more likely to give way. More frequently, rupture will result from softening of the walls in fatty degeneration or ulceration, or from the bursting of an aneurism of the heart, or from stenosis of the aorta. In the latter cases, the left ventricle will be usually the seat of the rupture.

6. Displacements.

Changes of Position of the heart, are by no means unfrequent. They may be congenital in their origin, or the result of disease in the surrounding organs. Of congenital displacement, we may mention first:

Ectopia Cordis, where, from some arrest of development, in the inclosing parts, the heart may be found in some position other than its normal one. From deficiency of the sternum and ribs, the heart has been found protruding from the chest, (*ectopia pectoralis*,) or from absence or deficiency of the diaphragm, it may be found in the abdomen with the abdominal viscera. Such cases live but a short time after birth.

Transposition of the heart is found in those cases where all the viscera, abdominal and thoracic, are exactly reversed in position. A case of this kind was discovered in the dissecting room a few years ago, by Dr. R. B. Weaver, demonstrator of anatomy, in the Hahnemann Medical College. The heart was here upon the right side, the aorta curving to the left; the liver upon the left; the stomach with its pylorus to the left; the colon commencing in the left iliac fossa; in short, everything completely reversed in position. The subject was a female of about thirty years, and undoubtedly suffered no inconvenience from the abnormal positions.

The more frequent displacements of the heart, however, are those resulting from disease in the surrounding structures. It may be crowded from its normal position, by pleuritic effusions, accumulations of air (pneumothorax), or even by a highly emphysematous lung. Displacements may also result from the presence of aneurismal or other tumors in the chest; curvatures of the spine; or from a hernial protrusion of some of the abdominal viscera through an opening in the diaphragm; or the presence of tumors, enlarged viscera, dropsies, etc., within the abdomen.

7. Contents of the Cavities.

Heart Clots. This subject is one that has until recently, been but imperfectly understood; and now even, our knowledge relating to it, is by no means complete. Enough

is known, however, to convince us that *heart clots*, are a more frequent cause of sudden death, than has been heretofore supposed.

Having in a recent paper, read before the Philadelphia County Homœopathic Medical Society, quite fully treated of this subject, I shall here merely transcribe the leading points of the same.*

Fibrinous heart clots, polypus of the heart, or fatty deposits, as they are sometimes called, differ from ordinary clots of blood, in the absence of the blood corpuscles, and hence, presenting the buff color characteristic of the coagulated fibrin of the blood. Ordinary blood clots, with the corpuscles entangled with the fibrin—and hence presenting the red color of blood—are usually found in the cavities of the heart and large blood-vessels after death, but in greater quantity upon the right side.

Color. The shade of color presented by the fibrinous clot varies in different cases. While *buff* is the prevailing color, the shade varies from a light drab to a decided yellow.

Consistency. In this respect a good deal of variation is also found; the difference depending, probably, in part upon the character of the disease, and in part upon the rapidity or slowness of the formation; those of a rapid or very recent formation, having a soft, fatty, or jelly-like character;† while, on the other hand, those of a more gradual formation, and with more sthenic forms of disease, acquire a considerable degree of density, the surface presenting a smooth appearance, as if acted upon by a current of blood, and in all respects resembling the dense fibrinous masses, found blocking up the cavities of aneurismal tumors.

Position. In every case reported below, the clot has been on the *right* side of the heart, although in some, a

* See Hahnemannian Monthly for May, 1871.

† In one case, the clot presented a marked resemblance to the abdominal fat of the goose, both in color and consistency.

small, soft clot has been found on the *left*. I am not sure that I have ever found one of these clots on the left side of the heart of such a size and consistency, or under such circumstances, as to have led me to suppose that it might have been a cause of death.

The body of the clot is usually found in the ventricle, extending from this, either up into the pulmonary artery, or through the opening into the auricle. In all cases, the clot has been more or less entangled with the tendinous cords of the valves and muscular columns of the heart, requiring, in some instances, considerable force to tear it away from its attachments.

Time of formation. An important question to be decided in regard to these heart clots, is the time of their formation. Are they *ante* or *post*-mortem in their origin? And upon the solution of this query depends the conclusion as to whether they are the *cause* or the *result* of death in the cases where found. That a fibrinous clot may sometimes be formed in the coagulation of the blood *outside* of the body, is a fact well known; as in the blood drawn from patients suffering from acute inflammatory affections, where, from the retarding of the coagulation, the blood corpuscles, from their greater specific gravity, have time to fall towards the bottom of the vessel, thus giving the "buffy coat" to the upper portion of the clot. The same cause—retarded coagulation—unquestionably may give rise to a clot *in the heart* after death, presenting the same character, viz., with the upper portion, of the buff, fibrinous character, while the lower portion, from the presence of corpuscles, will present the appearance of an ordinary blood clot. Such clots are not unfrequently found after death.

But have we any evidence that the fibrin of the blood may be deposited, forming clots within the vessels during life? In proof of this, we have only to refer to the result of the application of a ligature to an artery; where the

interval between the point of application and the first vessel coming off above, will be filled with a fibrinous clot, which performs an important part in the closing up of the vessel; or, to the well-known deposits of fibrinous layers within aneurismal tumors, sufficient, in many cases, to so fill up the sac as to result in a cure; therefore, the favoring conditions being present, it is not unreasonable to claim that fibrinous clots *may* form within the heart, of such size and in such positions as to be an immediate cause of death.

Causes. In looking for the causes, or conditions promoting the formation of these fibrinous deposits, we have to consider, first, variations in the character of the blood itself; and secondly, peculiarities in its circulation and in the circulatory apparatus. Fibrin, one of the normal constituents of the blood, is estimated by physiologists as forming from 2 to 3 parts in 1000, while it may fall as low as 1, or rise to 7½ parts. We find it reduced to the minimum quantity in all diseases which present a hæmorrhagic tendency, as in true typhus, yellow fever, certain malignant forms of disease, and as the effect of many poisons, both animal and vegetable. In these cases, the loss of fibrin results in the effusion of blood into the tissues, producing petechial spots, or upon the mucous surfaces, giving rise to epistaxis, black vomit, hæmaturia, etc., while very feeble, if any, coagulation of the blood will be found after death.

In scurvy, however, where we have a condition of the blood not unlike that above referred to, there appears to be a marked tendency to the formation of clots, as has been noticed by many observers, and as has been verified by Dr. J. C. Morgan, in several cases which came under his notice while in the army.

But it is in cases where there is at least a *relative increase* of fibrin, that heart clots are more liable to form. Such a condition we find in cases where, while the fibrin remains

normal in quantity, the water of the blood, the menstruum in which the fibrin is held in solution, is below the normal standard, this reduction favoring the tendency to deposit. Thus, in all cases where there has been an exhausting and rapid flux from the bowels, as in cholera, or excessive purging from drastic cathartics, or from the colliquative sweating of phthisis, we have the favoring condition, and death may be the immediate result of a fibrinous clot in the heart.

The *most* favorable condition, however, for the formation of heart clots, is undoubtedly that in which there is an *absolute* increase of fibrin, and this we find in a large number of diseases marked by acute inflammatory symptoms; as in pleurisy, pneumonia, diphtheria, croup, acute rheumatism, erysipelas, puerperal fever, etc. In a large number of deaths from these diseases, a post-mortem examination would undoubtedly bring to light a heart clot, which has at least served to hasten, if it has not been the immediate cause of the fatal termination.

Again, the formation of heart clots is evidently promoted by any circumstances or conditions, resulting in great feebleness or languor of the circulation, independent of variations in the amount of fibrin. A complete stasis of the blood is certain to be followed by coagulation; as in employment of pressure in the treatment of aneurism; so in cases of great prostration of the powers of life, attended with extreme feebleness of the circulation, as 1st. In cases of shock, where life is not immediately destroyed; 2d. In certain cases of poisoning, as by opium, where the action of the heart is greatly depressed; and 3d. In syncope, either with or without loss of blood. In all of these cases the danger of the formation of the heart clot is very great, and probably in a large number this is the immediate cause of death.

It is a fact well established, that loss of blood, either by hæmorrhages or venesection, is followed by an increased

coagulability of that fluid; hence, the fearful hæmorrhages which sometimes attend parturition, if accompanied with syncope, are in great danger of being followed by the formation of the heart clot, and thus ending in death.*

Another circumstance tending to promote the formation of fibrinous clots in the heart, is evidently to be found in the peculiar formation of the valves guarding the auriculo-ventricular openings. It is well known how fibrin may be collected from fresh blood, by beating the same with a bundle of twigs, the latter soon becoming coated with shreds of fibrin; so the *chordæ tendineæ* and fleshy columns of the heart, between which the blood is continually being driven, affords convenient points for collecting the same from the feebly circulating or overcharged blood; and from the close intermingling of the tendinous cords, with the substance of the clot, it is probably upon these that the deposit first begins to form.

In explanation of the fact that fibrinous clots are almost universally found on the *right* or *venous* side of the heart, notwithstanding that arterial blood is richer in fibrin than venous, the following has been suggested to my mind: *First.* While venous blood contains a smaller proportion of fibrin, may not its deoxydized condition favor the more ready deposit of this substance, than by the more highly vitalized arterial blood? *Second.* The feebler muscular power of the right side of the heart would necessarily be attended with a slower circulation through its cavities, the partial stasis of the blood giving another condition favorable for the formation of a clot; and *Third.* The valves of the right side of the heart, present three flaps or folds, instead of two as on the left, and hence, with their numerous tendinous cords, offer an increased number of obstructing points, around which the deposit may be made. These several circum-

* Meigs' Treatise on Obstetrics, p. 308.

stances would seem sufficient to account for the admitted fact.

Symptoms. The symptoms attending the formation of fibrinous clots in the heart, are usually sudden in their accession, frequently attended with a chill, and marked by great oppression in breathing, coldness of surface, and *pallor of face and lips*, the latter symptom distinguishing from the dyspnœa attending croup, asthma, pneumonia, etc., where the face is *livid* from venous congestion. The pulse is usually rapid and feeble; the action of the heart labored, palpitating, and sometimes intermitting, while auscultation will reveal a tumultuous churning-like action, the normal sounds being quite undistinguishable.

Pulsation of the jugulars will be present in most cases, and where the clot greatly obstructs the play of the tricuspid valves, a double pulsation will be likely to be noticed. In the last stage, a copious cold perspiration appears upon the whole surface of the body.

As might be anticipated, fibrinous formations, while of small size, are sometimes washed away from their attachments and swept on with the current of blood into the arteries and carried to distant parts of the body, as is sometimes the case also in aneurism, thus producing the embolic masses often found blocking up arteries in different parts of the body. When upon the right side, the embolus would be carried into the pulmonary artery, obstructing the circulation through the lungs, and producing symptoms more or less grave, according to the size of the clot. Upon the left side of the heart, from the greater force of the circulation, these bodies are probably more frequently swept away from their attachments and carried into the aorta, and thus on, perhaps, through the carotids to the head, or into the subclavian, or down the aorta, finally lodging in some of the branches of the lower extremities. Convulsions, paralysis, etc., are not unfrequently produced by the lodgment of

emboli in some of the arteries of the brain, while, when carried into the arteries of the extremities, pain, falling of temperature, impairment of sensation, contraction of muscles, atrophy, and even gangrene may result.

The following examples will serve to illustrate the class of cases to which I refer:

CASE I.—*Death from Heart Clot in Anæmia.*

A lad, 11 years old, and very anæmic, went to school in the morning in his usual health; while there was taken with a chill. On his way home vomited freely. The chill lasted for a long time, and was accompanied with an oppression in breathing, which gradually increased through the day and night, and until the time of my first visit at 11 o'clock A. M. the next day. I then found him extremely pallid, lips bloodless, perspiring freely, suffering from great restlessness and distress, with extreme dyspnœa; mind wandering, pulse irregular and feeble; action of the heart very tumultuous, the normal sounds being unrecognizable. In the neck noticed a rapid rolling pulsation of the jugulars, which presented two beats to one of the artery at the wrist.

At my second visit, made at 4 o'clock P. M., the patient had just expired.

The autopsy, made twenty hours after death, gave the following results: Upon opening the abdomen found the liver presenting a dark mottled appearance, and highly congested; other abdominal organs natural; pericardium contained about one ounce of serum. Upon opening the right auricle of the heart, found a firm fibrinous mass, extending downwards through the ventricular opening, and which, upon the latter cavity being opened, was found firmly attached to the tricuspid valves, and entangled with the fleshy columns and tendinous cords.

The presence of such a body in this position, and with such attachments, it was evident, must have so interfered with the passage of the blood from the auricle to the ventricle, as, upon the contraction of the former cavity, to have caused a backward pressure into the veins, and thus have produced the *first* of the double pulsations of the jugulars.

Again, the position of this clot, preventing the closure of the valves upon the contraction of the ventricle, there would have been a regurgitation into the auricle, and the same backward flow into the veins, thus producing the *second* pulsation of the jugulars seen during life.

CASE II.—*Death from Heart Clot in Pregnancy.*

A lady, 28 or 30 years old, also very anæmic, and three months pregnant, had been suffering occasional fainting spells. For some days before her decease she had suffered from dyspnœa, and on that day, after ascending a flight of stairs, fell upon the floor, and before a physician could be obtained breathed her last. A post mortem showed all the thoracic and abdominal viscera in a healthy condition, while the right side of the heart contained a large fibrinous clot, with attachments similar to those found in Case I.

CASE III.—*Death from Heart Clot in Diphtheria.*

A boy, 3 years old, had an attack of diphtheria. The case presented no unfavorable symptoms until about the fourth day, when he was taken with great restlessness and oppression in breathing, and while sitting on the chamber at stool, suddenly died. The autopsy here again revealed the heart clot, as in the other cases.

CASE IV.—*Death from Heart Clot in Consumption.*

A man, 30 years of age, a furrier by trade, was suffering from tubercular disease of the lungs. He had never given up his work, though he was much reduced in flesh, had a bad cough, diarrhœa, and night sweats. While at his employment, he was one day taken with great oppression, increased cough, etc., and in twenty-four hours expired.

The post mortem showed that, while the upper portion of both lungs contained large deposits of tubercles, there were no abscesses, and the lower portions presented sufficient sound lung tissue to have maintained life. Upon opening the heart the usual fibrinous clot was found in the right ventricle, extending upwards into the auricle.

CASE V.—*Death from Heart Clot in Rheumatism.*

A strong colored man, of 25 years, had an attack of inflammatory rheumatism. The disease presented the usual characters, the inflammation wandering from joint to joint. During the second week he was suddenly attacked with great difficulty in breathing, violent and irregular action of the heart, and great distress, followed by rapid prostration and death. The post-mortem examination revealed thickened tricuspid valves, with a firm clot of large size adhering to the same.

CASE VI.—*Death from Heart Clot in Debility.*

A gentleman, 55 years old, who had been for some time in feeble health, was taken, upon rising in the morning, with oppression and

distress in the region of the heart, dying in twelve hours. The heart clot was found here, as in the other cases, upon the right side of the heart.

CASE VII.—*Heart Clot in Death from Over-dose of Morphia.*

A gentleman, of about 50 years, a physician, was found one morning dead in his bed. His health had been previously good, excepting that he was troubled with neuralgia which gave him sleepless nights, and for which he sometimes took morphia. On the night previous to his death he came home and retired at a late hour. An open bottle of morphia and small spatula were found on his desk next morning, the spatula showing evidence of having been thrust deeply into the morphia, and probably a large and over-dose carelessly removed and taken. The autopsy here again revealed a large and firm fibrinous heart clot.

CASE VIII.—*Death from Heart Clot in Acute Gastritis.*

A lady of about 60 years, had an attack of acute gastritis, but was considered convalescing, and her physician (Dr. Martin) made his last visit in the evening. The next morning she was found dead in her bed. The post-mortem showed the spleen somewhat enlarged, and its capsule greatly thickened.* Other organs healthy, while the heart contained an unusually large fibrinous clot, which has been preserved in the College Museum.†

The above include the more marked cases of death that have come under my notice, where that result could, in my mind, be fairly attributed to the formation of fibrinous clots in the heart.

The following inferences may, we think, be fairly deduced from the several cases reported:

First. In some instances the fibrinous clots are apparently the *sole cause* of death. (Cases 1, 2, and 3.)

Second. In other, and a larger number of diseases, as in acute rheumatism, pneumonia, croup, etc., which otherwise would recover, a fatal termination results from the formation of heart clots. (Cases 3 and 5.)

Third. In still other diseases, which are of themselves necessarily fatal, as in phthisis, cholera, etc., death is often hastened by these formations. (Case 4.)

* No. 1470 College Museum. † No. 1344 College Museum.

Section VI. THE AORTA AND ARTERIES GENERALLY.

[**Notice:** 1. *Before Opening Vessel*—size; course; condition of external coat and surrounding tissues. 2. *After Opening Vesssel*—character of blood within; coagulated or not; size, color, consistence, etc., of clot; size of canal; thickness of walls; rigid or flexible. *Lining Membrane*—smoothness; transparency, etc.; readiness of detachment; thickness, etc.; if rough, the apparent cause; fibrinous, atheromatous or calcareous deposits. *Middle Coat*—its thickness; color; deposits within, and their character. *External Coat*—general condition.

ANEURISMS:—1. *External Characters*—size; shape; is the dilatation lateral or general in its relation to the vessel? Openings as seen externally; size, position, etc.; blood effused; quantity, etc. *After opening, notice*—contents; blood fluid or coagulated; fibrinous contents; laminations; their thickness; number; density; dryness; difference between outer and inner layers. Channel for blood: size; character of inner surface; how formed? Walls of aneurism: how formed; by all, or one coat of artery. Size of artery above and below aneurism.]

The diseases of the aorta, and of arteries generally, which may claim attention in a post-mortem examination, are *inflammation, fatty degeneration, calcification, aneurism,* and *rupture.*

Inflammation. This process may be found involving either the outer or inner coats of arteries. In the former case the walls appear thickened and infiltrated with a soft, jelly-like substance, which appears, at a more advanced stage in some cases, to degenerate into a purulent condition, while in others, great thickening of the coats, or even obliteration results. Inflammation of the inner coat generally precedes atheromatous or calcareous deposits, and is mostly confined to old persons. The roughened inner surface thus produced, may serve to collect fibrinous shreds from the blood, and thus be the occasion of the formation of emboli.

Inflammation of arteries may result from injuries, from the presence of emboli, or may be spontaneous in its origin. While the more frequent seat of the disease is in the aorta, it may occur in any other artery.

Fatty Degeneration, or atheromatous disease of arteries, is an important affection of those vessels, and is usually associated with aneurism. It is seen more frequently in the arch of the aorta, and consists in the presence of fine white streaks, situated in the substance of the lining membrane. The disease may be found in children as young as from three to seven years of age, but is more common with adults. As the disease advances, the middle coat becomes involved. The streaks gradually change into large, white, opaque patches. The middle coat becomes thinned, loses its elasticity, assumes a gray, semi-transparent appearance, and, at a later stage, becomes soft and cheesy, and sometimes even undergoes a form of liquification into a creamy fluid resembling pus, but dependent upon the abundant formation of fat globules, with scales of cholesterine and granular matter.

While these destructive changes are going on in the inner and middle coats, and tending to their rupture, by a conservative process, the outer coat, upon which the strength of the vessel mainly depends, becomes thickened and strengthened by the accumulation of plastic matter.

Ossification. Ossification of the aorta, like that of the coronary and other arteries, consists rather in a process of *calcification.* The deposits are largely confined to the arch, and consist mainly of patches of calcareous matter of various sizes. We seldom find the whole circumference of the vessel involved, as in the case of smaller arteries. The aortic valves will generally be found more or less loaded with the same deposits.*

Aneurism. This disease is said to occur more frequently in the aorta, than in any other artery. It may be developed in any portion of this vessel or its principal branches,

* No. 1385 College Museum.

but is more commonly found in the arch. The walls of the vessel being weakened by fatty degeneration, they become less and less able to resist the pressure of the contained blood, and gradually yielding to the systolic force of the heart, become more and more distended, until the complete aneurismal sac is formed.

Aneurism may be either *true*, in which there is a dilatation of all the coats of the vessel, or *false*, where there is rupture of the inner, and perhaps also of the middle, and dilatation of the outer coat alone. The latter form, when developed upon the aorta, may become very large, and by pressure, cause absorption of the sternum, costal cartilages and ribs, and even of the clavicle.

In some cases, the inner and middle coat having ruptured, the blood instead of being confined in a sac formed by the outer coat, becomes diffused between the middle and outer, or between the layers of the middle coat, thus constituting what is known as *dissecting* aneurism. In these cases, the blood may extend the whole length of the aorta, and even upwards upon the carotids to their bifurcation.

In an examination of an aneurismal sac, the *true* aneurism will be recognized by the walls presenting all the coats of the artery, and generally by the indication of the presence of atheromatous and calcareous deposits, which are confined to the inner and middle coats. In these cases also, the communication between the sac and the aorta is large and free. If the aneurism be *false*, however, there will be an absence of those deposits, the opening into the artery will be comparatively small, and the inner and middle coats will terminate abruptly at its margin.

The interior of aneurismal sacs will usually be found containing a quantity of fibrine deposited from the blood, and arranged in concentric layers. In color, these fibrinous layers are of a light buff, the outer layers being dry and firm, while the inner ones are softer and more moist, and the

central portion, at the same time, filled with a dark mass of coagulated blood. A spontaneous cure will sometimes be effected by a complete blocking up of the sac with fibrinous deposits, thus preventing further dilatation or danger of rupture.

The following case, which has been before reported,* shows a combination of both true and false aneurism, with spontaneous cure of the latter:

CASE.—*Spontaneous cure of aneurism of ascending portion of arch of aorta, with death from bursting of aneurism of descending portion into the œsophagus.*

Mr. H——, of this city, aged sixty years, while walking in his yard one day after a hearty dinner, was taken with a sudden sensation of faintness and nausea, which was soon followed by vomiting the contents of his stomach, with a considerable quantity of blood. After entering his house, the vomiting was frequently repeated, and at each effort large quantities of pale blood ejected. Sinking rapidly, in an hour he was dead.

Twenty-four hours after, I made a post-mortem examination. Upon exposing the chest, found at the right border of the sternum, just below the clavicle, a hard, inelastic tumor beneath the skin, of the size of a small orange. While not adherent to the integument, it appeared firmly attached to the walls of the chest beneath. Upon turning aside the integument and pectoral muscles, the tumor was found connected by a long pedicle to parts within the chest; absorption of considerable portions of the sternal ends of the first and second ribs, with the side of the sternum, having resulted from pressure of the tumor upon those parts, and finally permitting its appearance beneath the skin.

The removal of the sternum at once demonstrated the aneurismal character of the tumor by showing its connection with the ascending portion of the arch of the aorta, while a section of the same, exhibited the interior filled with dense concentric layers of fibrinous matter, separable from one another, the outer layers being dry and hard, while the inner portion was less firm and moist. This aneurism was plainly of the *false* variety. The neck of the tumor was not much

* See article on Spontaneous Cure of Aneurism, with cases in New York Transactions of Homœpathic Medical Society for 1868, page 170.

larger than the thumb, and of sufficient length to reach from the arch of the aorta to the dilated sac beneath the skin, outside the chest.

A further examination of the aorta brought to light a second and *true* aneurism of the descending portion of the arch, the dilatation involving all the coats of the vessels, and which, having *burst into the œsophagus*, explained at once the cause of the hæmorrhage and sudden death.

Upon inquiring of the family, I learned that the tumor upon the chest had been known to have existed for fifteen or twenty years; that for some years the pulsations of the tumor were strong, but that for many years all beating had ceased; that he had never discontinued his work, that of a carpenter, and in fact, it had given him so little trouble that he had never consulted a physician in regard to it. For a year or so previous to death, he had been troubled with a cough, particularly upon exercising, but otherwise had been in good health.

A remarkable and interesting feature of this case was, the little inconvenience experienced by the patient from so grave a malady, and one usually attended with great suffering.

Rupture. Spontaneous rupture of the aorta is a very rare occurrence, and probably never happens except the coats have first been weakened by disease. Hence, in all of these cases, there will be found atheromatous softening, and generally thinning of the walls by dilatation. In this condition, some violent muscular effort may result in rupture at the most weakened point, and this will be generally at that portion of the aorta within the pericardium, the external coat being weaker here than at any other point.

Where the dilatation of the diseased and weakened vessel has resulted in the formation of an aneurism, rupture of this will be the more frequent termination. This may take place into the œsophagus, as in the case reported, or into the trachea, the pericardium, either pleural cavity, or upon the surface of the body.

Rupture of the coronary arteries, of the arteries of the brain, various branches of the abdominal aorta, and arteries of the extremities, have occasionally been found, when softened by fatty degeneration or atheromatous disease.

Section VII. THE PLEURA.

[**Notice:** *Condition of membrane*—inflamed; extent and position of; thickened; transparent or opaque; rough or smooth. *Contents*—blood, gas, serum, pus, amount and probable source of. *Adhesions*—general or local; firmness of, etc.]

Like other serous membranes, the pleura is liable to *inflammation*, both acute and chronic, with their results—*plastic*, *serous*, or *purulent effusions*, *adhesions*, etc.

Inflammation. The first change which is observed in inflammation of the pleura (pleurisy) is a loss of the shining, transparent appearance of that membrane, it becoming dull and opaque. Red injected vessels, in minute ramifications, sometimes radiating from single points, in others more uniformly diffused, will be noticed. Often the surface will present a red mottled appearance, with here and there small points of extravasation. This condition having existed for from six to twenty-four hours, certain results follow —at least in the acute form—which give rise to what is known as

Plastic Effusion. Soon after the inflammatory process is fully established, there will appear upon the surface a small quantity of clear fluid, which, as it increases in quantity, undergoes coagulation, and thus gradually covers the surface with a jelly-like layer of variable thickness and honey-comb surface. A thin fluid of a straw color, will be found oozing from the surface, which is increased as the coagulated membrane is cut or torn. This condition may be extended over the whole surface of both the costal and pulmonary pleura, or may be confined to a limited portion.

Adhesions. The two layers of the pleura being in immediate contact, the consequence of this effusion of coagulated

lymph will be an early adhesion of the applied surfaces. This is accomplished by a blending of the layers of coagulated matter in contact, and a gradual organization of the same by an extension of blood-vessels from the pleura into the new formation. At the same time that these changes are progressing, the watery part of the exudation trickles down to the most dependent portion of the cavity, and there forms a serous or sero-purulent accumulation. Adhesions are more frequent at the upper portion of the lungs, but may be found at any point, as between the inner surface and the mediastinum, or the lower surface and diaphragm; or, from repeated attacks of pleuritis, involving different portions of the serous membrane, the whole of the exterior of the lung may become united to the adjoining surfaces.

The strength of the adhesions will be somewhat in proportion to their age, those of long standing requiring considerable force to break them up, and in many instances the lung tissues becoming lacerated before the attachments can be torn away.

Unusual thickness of the pleura is often found at points where no adhesions exist, this being unquestionably the result of the effusion of plastic matter into the sub-serous tissue during an attack of inflammation.

Serous Effusion. While in the majority of cases of pleuritic inflammation, we shall find *plastic effusions* followed by adhesions of the inflamed with the adjoining surface, in some instances a serous or watery fluid is rapidly poured out, and, accumulating in the pleural sac, constitutes *hydrothorax* or dropsy of the chest. The fluid in these cases may present a variety of shades of color, from a pinkish or light straw color, to a dark brownish shade. It may be transparent or opaque, and generally will be more or less albuminous. The quantity may vary from a few ounces to three, four, or five pints, or more. When in large quantity, the lung will

be found more or less collapsed, shrunken, and pressed against the posterior walls of the chest and spinal column.

In the general dropsy attending diseases of the heart, kidneys or liver, effusions may take place into the pleural cavities, to such an extent as to give rise to great dyspnœa from compression of the lungs.

Sero-Purulent or Puriform Effusions, consist in the presence of a quantity of granular particles with albuminous matter, which subside to the bottom of the vessel when drawn off, and always contains floating flakes of lymph. It may be found in cases of both acute and chronic pleurisy, and, like serous effusions, may be found in large quantity.

Purulent Fluid, as found in the cavity of the chest, consists of a white or cream-colored, opaque, and homogeneous fluid, combined with more or less albuminous matter, in the form of shreds and flakes, yet destitute of the granular matter of the sero-purulent fluids, and not separating into a fluid and solid portion when at rest, as is the case with the latter.

It is a fact well established, that genuine purulent matter may be formed in the pleural cavity, as well as in other serous cavities, without ulceration of any portion of the surface, or discharge of an abscess into the same, it being the result of a more advanced stage of the process which gives rise to the serous or plastic effusions. It may be secreted directly from the capillaries of the inflamed surface, or, in some instances, it would appear to be derived from the organized false membranes, which have taken on a suppurative action.

Pneumothorax. Air may enter the pleural cavity, by perforation of the walls of the chest from external injury, or, as is more common, by the destruction of the pulmonary portion of the membrane, from the bursting of a distended

air-cell, or from softening of tubercular deposits, or bursting of an abscess. If there are but few or no adhesions, the accumulation of air in the cavity may be accompanied by a more or less complete collapse of the lung, as in hydrothorax. This condition, during life, is not readily distinguished from emphysema, both being accompanied with similar oppression in breathing, distension of the chest, and displacements of the heart, and with increased clearness on percussion. Serous or sero-purulent effusions will frequently accompany the presence of air in the cavity, and thus give rise to many of the peculiar physical signs which may have been noticed during life, as metallic tinkling, a splashing sound on shaking the chest, etc.

Section VIII. THE LUNGS AND BRONCHIAL TUBES.

[**Notice**: 1. While *in situ*—degree of collapse; adhesions; position and character of; wounds, etc. 2. *After removal*—external character; color; peculiarity of shape; adhesion of lobes; puckerings at apex; solid or compressible; crepitation; where most noticeable; effect of inflation on color and size. *Tubercular deposits*—size; location. 3. *Substance of lung*—solid or porous when cut; extent of solidified portions; fluids escaping; character and quantity of. *Abscesses*—position; number; size; character of contents; color; odor, etc.; condition of lung around cavities; character of walls; thick or thin; smooth or rough; crossed by bands; communication with bronchial tubes. *Gangrene*—location and extent of. *Bronchial tubes*—contents; contraction or dilatation; measurements at, above and below these points; condition of mucous membrane; congested or ulcerated; walls of tubes; thicker or thinner than natural. *Extravasation of blood*—(apoplexy of lung;) portion and extent of lung involved; condition of surrounding tissue; blood infiltrated or encysted. *Adventitious deposits—cretaceous bodies;* situation; size; density; condition of surrounding tissues. *Tubercles*—seat; size; number; color; density, etc.; condition of surrounding tissue. *Cancerous masses*—size; location, etc. *Carbonaceous deposits*—around bronchial tubes; beneath pleura. *Result of placing entire lungs in water*—do they sink or float? If they sink, is it rapidly or slowly? If they float, is it above, below, or at the surface of the water? Results with portions of each lung.]

The pathological conditions of the lungs, may be arranged as follows:—*Inflammation* and its results, *hepatization*,

suppuration, abscess, gangrene, hæmmorrhage, pulmonary apoplexy, emphysema, tubercular disease, morbid growths, and *parasitical animals.*

When in a healthy condition, the lungs will present the following appearance:—Upon opening the chest, there will be a more or less complete collapse of both organs, partly from atmospheric pressure, and partly from the elasticity of the lung tissue. They will then have a shrunken, shrivelled appearance, crepitating under pressure, and have an ashen gray color. If inflated, the surface becomes smooth and shining, showing an indistinct outline of the lobules, which, with the dark pigmentary matter seen here and there, gives the surface more or less of a mottled appearance.

Where pleurisy had previously existed, there may be adhesions preventing the collapse of the lungs, until these have been broken up. When cut into, healthy lung tissue has a soft, spongy character, the upper portions will be quite destitute of blood, while the posterior portions may be more or less filled with that fluid from gravitation, giving them a dark congested appearance.

Inflammation and its Results.

Pneumonia, or inflammation of the lungs, may affect both the air cells, when the latter become filled with fibrinous exudations, and the connective areolar tissue, which then become increased in quantity.

The following characters present themselves, corresponding to the three recognized stages of the disease:—First, *congestion;* second, *red hepatization;* third, *gray hepatization or softening.*

Congestion. From the peculiar structure of the lungs, in connection with the free circulation through the same,

these organs are peculiarly liable to the several forms of congestion. In many cases of death, without any original disease of the lungs, there will be a tendency for these organs to become loaded with blood, giving rise to post-mortem appearances, often with difficulty distinguished from those of a pathological origin. In this post-mortem, or, as it has been called *hypostatic* congestion, the posterior and inferior portions of the lungs are chiefly affected, as the blood after death, obeying the law of gravitation, sinks to the lowest point. The congested portion presents a dark red color, and though firmer than other portions, crepitates under the finger and floats in water, the latter circumstance serving to distinguish this form of congestion from that of an inflammatory origin. If the congestion be confined to one lung, or to the anterior parts of either, we may safely attribute it to a pathological cause.

In all cases of congestion, upon opening the chest, although there may be no adhesions, the lung does not collapse, or does so feebly. When cut, it is found to be loaded with blood, and upon pressure, much bloody serum escapes, while the divided bronchial tubes will be found filled with frothy mucus.

Red Hepatization. This condition of the lungs soon follows that of congestion. The change is a gradual one, and is first marked by an effusion of serum and coagulable lymph into the connective tissue and air-cells, thus rendering the lungs more solid, while as the change becomes complete, the blood itself, which had during the congestive stage been confined to the vessels, is now found extravasated into the interstices of the tissues. The portion of the lung thus affected is not only of a dark red or violet color, but solid, firm, does not crepitate, sinks when thrown into water, and when cut and washed, the section shows patches of a rough, granular aspect, totally different from that of healthy lung

tissue. The pleura in this condition may be wholly unchanged, even though the solidification may have been of long standing.

Gray Hepatization, which characterizes the third stage of pneumonia, is known by the lung presenting a firm, semi-solid, inelastic, and more or less incompressible character. Failing to collapse, the lung is found more or less completely filling the chest. The pleura will generally present evidences of inflammation in the presence of patches of lymph and more or less points of adhesions. The upper lobe may be soft and compressible, while the lower is solid from hepatization. When divided with the knife, the substance is found of a gray, red, or dirty yellow color; compact, but friable and easily broken down with the fingers, while the smaller bronchial tubes are filled with fibrinous plugs. Bloody purulent matter, with much turbid serous fluid, will ooze from the cut surfaces. Pus globules will be detected in the escaping fluids by a microscopic examination.

Resolution of a hepatized lung, consists in the gradual softening of the effused substances within the smaller bronchial tubes and air cells, and the discharge of the same by cough and expectoration.

Inflammation of the lung usually commences in the lower lobe, and while the disease here may extend to complete hepatization, the middle lobe may be found merely congested, while the upper is quite healthy. Inflammation may attack one or both lungs. In the former case it is known as single, and in the latter as double pneumonia. From an examination of a large number of cases, it has been ascertained that inflammation of the right lung is more frequent than that of the left in the proportion of about three to one, and that single pneumonia is more common than double pneumonia in the ratio of six to one.

Pneumonia is sometimes divided into *Catarrhal* and

Croupous. In the former, the exudation contains little or no fibrinous matter, while the bronchial mucous membranes are also involved, the disease at the same time being confined mostly to the lobules of the lungs. In the *croupous* form, the exudation contains a large proportion of fibrine, and the disease usually involves the greater part of a lobe, or may extend to the whole of one or both lungs.

Both forms of the disease may run through the three stages of congestion, red and gray hepatization.

A peculiar form of inflammation of the lungs, found mostly in children and young persons, and usually chronic in character, has been described as

Lobular Pneumonia. The inflammation here being confined to the lobules, these, after the disease is perfectly developed, present the appearance of a multitude of rounded nodules, of the size of small nuts, scattered through the substance of the lungs. The exterior of these is reddish, firm, and vascular, while the interior is of a grayish color, containing effused lymph, with more or less purulent matter.

This form of pneumonia being frequently associated with diseases of the joints and bones, as well as with inflammation and ulceration of the glands of the intestines, it has been considered as depending upon a strumous diathesis, and as, in fact, but the early stage of tubercular consumption. Seldom proving fatal in the early stage, or before the disease has extended to the whole substance of the lung, and perhaps resulted in the formation of cavities, we much less frequently meet with this form of pneumonia in post-mortem examinations.

Suppuration and Abscess. Gray hepatization must be looked upon as a form of *suppuration* of the lungs; as the purulent-looking fluid found infiltrating the tissues, filling the air-cells and smaller bronchial tubes, upon a microscopic examination, is found containing undoubted pus globules.

This, however, is not an abscess, the matter not being confined within a cavity, but diffused through the tissues of the part. That a distinct abscess of the lungs may form, as a result of pneumonia, is generally admitted, though they are usually small and confined to the lower lobes. From softening of tubercular masses, abscesses not unfrequently form in any portion of the lungs. That they do not occur more frequently in pneumonia, may result from the fact that the disease often proves fatal by suffocation, before there has been time for it to have reached the suppurative stage.

The pleura over the seat of the abscess will generally be found much thickened, and frequently adherent to the opposite walls of the chest. Pulmonary abscess may be wholly discharged by expectoration—the cavity communicating with the bronchial tubes—or it may discharge into the pleural cavity, or when adhesions have first formed, it may work its way between the ribs, and the matter escape upon the surface of the body.

Metastatic or Secondary Abscess. This form of abscess in the lungs, is well understood to be the result of suppuration in some distant part or organ, which, being attended with phlebitis of the part, purulent matter is introduced into the circulation, and thus conveyed to the lungs or perhaps the liver. This original suppuration may be at the uterus after delivery, or from a fistulo in ano, psoas abscess, or any other similar affection.

From the fact, probably, that the whole volume of the blood flows through the lungs, at each round of the circulation, these organs are more frequently affected with this form of abscess than any other, it occurring next in frequency in the liver. These abscesses may be recognized as spots of yellow pus, varying in size from a pin's head to a walnut, generally situated near the surface of the organ and surrounded by a dark, well defined layer of congested tissue,

while beyond this, the structure is in a healthy condition. Several of such abscesses may be found in various parts of the lungs.

Gangrene. Gangrene of the lungs, rarely results from an attack of ordinary pneumonia, but appears more frequently to take place either as a concomitant of pestilential fevers in general, or as an accompaniment of certain cases of tubercular vomicæ of the lungs, or as a primary and peculiar species of inflammatory affection of those organs.

In the first instance, a patient suffering a severe form of typhoid fever, presents symptoms of pulmonary disorder, as hurried respiration, livid face, cough, first dry and soon moist, with thick orange-colored and finally dark or bloody and extremely offensive expectoration, and fetid breath. With these symptoms are generally associated great feebleness, delirium, with tendency to gangrene of the extremities and prominent points of the hips, sacrum, etc.; and finally, with increased difficulty in respiration and fetor of breath, death ensues.

In the second case, a patient suffering from clearly recognized tubercular disease of the lungs, which has passed on to softening of tubercular masses, and the formation of vomicæ, has an aggravation of all his symptoms, accompanied with the expectoration of a highly offensive dark matter, plainly resulting from a gangrenous condition of the interior of a tubercular cavity.

In the third case, the disease comes on at first as an affection of the lungs. The attack commences either as pulmonary inflammation, or bronchial disease, or with spitting of blood with more or less pain in the chest. The patient becomes rapidly worse, the cough increasing, with reddish brown or bloody sputa, and offensive breath. The countenance is anxious and livid, the eye heavy, sometimes wild and glaring. The fetid breath is not always an early

symptom, but when it does appear, the disease in general tends rapidly to a fatal termination, although recovery sometimes takes place.*

The appearances after death, in cases of gangrene of the lungs, are of two kinds, according as the disease is *diffuse* or *circumscribed.*

"In the *first* case, a mass of lung, two and a-half or three inches wide, but irregular in figure and outline, is converted into a soft, pulpy, dark, ash-colored substance, which, when it is handled or pressed by the fingers, falls down into a loose, moist mass, emitting a fetid, offensive odor, without trace of the usual structure of the lungs, except a few bronchial tubes, and blood-vessels, and shreds of filamentous tissue. This mass is generally bounded by, but it does not terminate abruptly in, healthy lung. It is soft, dingy, and infiltrated with a dark, ash-colored, dirty, serous liquor. Occasionally the surrounding portion of the lung is hepatized or infiltrated with blood or bloody serum; the bronchial tubes always contain much bloody, viscid mucus; and sometimes the pleura is reddened, covered with lymph or adhesions, and contains fluid in its cavity."

The portion of the lung thus affected is usually within the lower or middle lobe, the upper portion being rarely involved.

In the *second*, or *circumscribed* form, a portion of the lung, generally near the surface, presents a dark-colored, hard patch, varying in size from a quarter, to a half-dollar piece or more, often quite circular, and bounded all round by healthy lung. This circular hard patch, which resembles closely an eschar produced by caustic potash, may adhere or be easily detached. In the latter case, it generally leaves a cup-like cavity, the surface of which is firm, granular, with the blood-

* See case of recovery reported by Dr. R. Koch, in American Jour. of Hom. Mat. Med., Vol. IV., p. 123.

vessels and bronchial tubes closed, and with the surrounding lung more softened, but generally presenting marks of pleurisy, pneumonia, and bronchitis all combined, which may be looked upon as an effort of nature to isolate and detach the diseased mass.

Pulmonary Hæmorrhage—*Hæmoptysis.* Discharge of blood from the lungs by coughing, may result from a variety of causes, among which may be mentioned: 1, mechanical shock or injury, as in falls or blows upon the chest; 2, inflammatory action within the lungs; 3, disease of the heart; 4, disease of the arteries; 5, tubercular deposition; 6, tubercular destruction, with ulceration of vessels.

In the first instance the expectorated blood may be copious or slight, according to the severity of the injury. If death soon results, an examination of the lungs will disclose one or more of the bronchial tubes filled with blood, which has plainly arisen from a rupture of some of the capillaries of the bronchial mucous membrane. The blood discharged in many cases of the early stage of consumption, and in young females after the suppression or retention of the menstrual flow, is from the same source.

Hæmorrhage from the lungs may also take place as a result of tubercular deposits. The presence of tubercular masses must necessarily produce more or less pressure on the adjoining vessels, interfering with the flow of the blood through the same, and thus inducing congestion, and even rupture of some of the capillary branches. Again, where tubercular masses have progressed to softening, and a cavity has been formed, the ulcerative process may open a large vessel, and death result in a few minutes from excessive hæmorrhage. A post-mortem will here show the cavity, as well as the bronchial tubes and trachea, filled with coagulated blood.

The blood expectorated during the early stage of an attack of pneumonia, is never copious, consisting mainly of streaks

of blood through the saliva, while at a later stage, from being more uniformly diffused, it gives the peculiar *rusty sputa* characteristic of this disease. The post-mortem appearances have already been given under the head of *pneumonia.*

Certain forms of disease of the heart, as ossification of the mitral valves, with contraction of the orifice, or in hypertrophy of the left ventricle, with disease of the aortic valves, are frequently attended with hæmoptysis. In either case, the obstruction to the free circulation through the left side of the heart, must induce an over-distension of the pulmonary veins, which, upon some unusual exertion, may readily result in extravasation through the bronchial mucous membrane, causing the bloody expectoration which takes place during life, or into the pulmonary connective tissue, giving origin thus to what is known as

Pulmonary Apoplexy. The post-mortem appearances in these cases, are as follows:—The portion of the lung involved, fails to collapse on opening the chest. It is firm, and of a dark red color; and when cut into, thick blood issues from the cut surfaces. The portion involved may include from one to four cubic inches. It will be found circumscribed with healthy lung tissue, and looks not unlike a clot of venous blood; these circumstances serving to distinguish it from hepatization, which terminates more or less gradually in sound lung.

While these hæmorrhagic effusions may, in many cases, cause early death by their size and number, in others, the clot may soften, the lung around become inflamed, or even gangrenous, resulting in the formation of an irregular cavity filled with dark, offensive, semi-fluid contents. In still other cases, where the clot is small, and in part within the air-cells, it may soften and become absorbed or coughed up, and the air again enter the cells, or these may contract into a fibrous indurated mass.

Emphysema. Emphysema of the lungs, is usually described as of two forms—*vesicular* and *interlobular*.

Vesicular emphysema, consists essentially in a dilatation or over-distension of a greater or less number of air cells, resulting in giving the portion involved greater buoyancy in water, from diminished specific gravity, lessening the crepitation on pressure, preventing collapse on the opening of the chest, and rendering the affected portion more or less dry and bloodless. From the loss of elasticity, there will be during life, a difficulty in the lungs emptying themselves of air as they should, hence the patient will be subject to severe attacks of oppression upon the slightest aggravating cause. If one lung only is affected, the corresponding side becomes enlarged and less movable than the other; the adjoining viscera, as the heart or abdominal organs, are more or less displaced, the intercostal spaces swell out, and the ribs becoming more horizontal, give a barrel-shape to the chest, which is quite characteristic of emphysema.

This distension of the air-cells, is more marked along the edges of the lungs, the vesicles at these parts being probably the least supported. Patches of dilated cells may be found, however, at other parts, which, if superficial, will project beyond the surface of the surrounding healthy portions, and appear like large bladders, from the coalescing of several vesicles.

This form of emphysema may be induced by any cause interfering with the ready escape of the air from any portion of the lungs, especially if accompanied with severe cough, as in many forms of bronchial disease, enlargement of the bronchial glands, etc.

Interlobular Emphysema, consists in an effusion of air into the connective or areolar tissue of the lungs, from a rupture of air-cells or smaller bronchial tubes, or from the laceration of the lungs from a broken rib, when the air may accumulate in the pleural cavity, constituting pneumothorax,

and may also be accompanied with emphysema of the chest, neck and head, from an escape of the air at the point of injury into the tissues of those parts. This form of emphysema may involve a large part or the whole of the lung, while the vesicular form is generally limited to definite portions. By disturbing the circulation through the lungs, emphysema is liable to induce dilatation of the right side of the heart.

From an evolution of gases within the lungs after death, we may have similar appearances to that above described, requiring some care to distinguish between the two. In the latter case, the general indications of decomposition, with the ease with which these distended vesicles may be emptied by pressure, will aid in determining the character of the case.

Tubercular Disease of the Lungs.

I shall not attempt to present here the various theories that have been promulgated as to the nature and origin of tubercle, contenting myself by giving a description of their anatomical characters, as presented in the several stages of tubercular disease.

Tubercle, or tubercular matter, may be described as consisting of a yellowish-white substance, opaque, friable and unorganized. It may be deposited in most of the tissues or organs of the body, but its more common seat is the free surfaces of mucous membranes, though often found in connection with the serous.

Tubercular deposits in the lungs, are not uniformly distributed through all parts of those organs, being in the large majority of cases confined to the upper and back part of the upper lobes, and in those cases where they are more or less distributed through the whole lung, they will be found more numerous and larger in those parts.

Tubercles may exist as fine points, not larger than a pin's

head, (*miliary tubercle,*) or the matter may accumulate in masses of the size of a kernel of corn, of a cherry, or of a robin's egg. In other cases, the pulmonic exudation in some portion of the lung attending an attack of pneumonia, may become transformed into tubercular matter, having an irregular outline and no distinct boundary, (*infiltrated tubercle.*)

Tubercular matter is undoubtedly, in most instances, deposited within the air-cells, so filling these, as to more or less interfere with the admission of the air, and giving greater density to the portion of lung involved. While the secreted matter is at first soft, or semi-fluid and partially translucent, it gradually acquires greater density, becomes opaque and cheesy in its character, and in all respects acting as a foreign body within the lungs. Sooner or later, the presence of tubercles will excite inflammation in the surrounding tissues. In this manner these bodies may become softened and their substance expectorated. If large numbers be aggregated together, the ulcerative process may completely destroy the tissues between, an abscess or vomica resulting.

In the early stage of the disease, before the inflammatory and ulcerative processes have been set up, the presence of tubercular matter, by interfering with the capillary circulation, may give rise to a hæmorrhage into the bronchial tubes, constituting the hæmoptysis so frequently present in this disease; while at a later period, from a destruction of some of the larger vessels from ulceration, a profuse and even fatal hæmorrhage may result.

Post-mortem Appearances.

In examining the lungs of those who have died after suffering the usual symptoms of pulmonary consumption, we shall find the upper portion of one or both lungs, more or less indurated, and occupied by one or more irregular shaped cavities, containing either air, or air and a quantity of viscid,

puriform, dirty-looking fluid. Generally the apex of the affected lung, will be found firmly attached to the inner surface of the chest, by means of a thick, firm, false membrane, which unites the two layers of the pleura. In some instances, nearly or quite the whole surface of the lung will be found thus adhered, while the lobes will also be united by an interlobular false membrane. When the adhesions are confined to the upper portions of the lungs, the pleura covering the lower portion will frequently be found more or less rough from albuminous exudation, while a quantity of sero-purulent fluid will be found in the posterior part of the thoracic cavity.

The greater part of the upper lobe, may be found converted into one irregular cavity; more frequently, the upper lobe presents two or three, either isolated or communicating. The largest, when several are present, is most commonly in the upper portion of the lobe. When entirely or partially filled with matter, such cavities are usually termed *vomicæ* or abscesses, while when empty, they are generally called *tubercular cavities* or excavations.

In the lower part of the upper lobes, the cavities are few and small. The middle lobe of the right lung, rarely presents cavities, while the lower lobes of both lungs are entirely free. The whole of these parts, however, may be more or less indurated by the presence of hard, irregular shaped masses, the result, probably, of inflammatory action.

Tubercular cavities present a considerable variety, both in size and shape. They may not be larger than a pea, or bean, or may reach the size of an egg, or even of an orange. Always of an irregular shape, they often consist of one large cavity, communicating with two or three smaller ones. The interior will be found traversed by bands, or cords, passing in various directions, but generally taking a longitudinal course, and probably the remnants of blood-vessels and bronchial tubes.

The tissues immediately around a cavity, and forming its walls, will be found firm, inelastic, almost cartilaginous in character, and of a dark red, or brown color. The density of the structures is caused partly by tubercular deposits in the lung, and partly by inflammatory induration.

While tubercular disease of the lungs is almost universally fatal, there is reason to believe that, in a very small proportion of cases recovery has taken place, and the post-mortem appearances of the lungs have accorded with this view. These appearances may be described as follows:

We sometimes observe in examining the lungs of individuals who may have died from diseases of other organs, that the pleura covering the upper lobe of the lung, presents, at a certain point, a puckered, shrivelled appearance, with a leather-like feel, and with a rounded, firm mass beneath. Upon dividing the latter with the knife, the interior is found composed either of a soft substance like putty, or more frequently of a chalky nature. This is looked upon as a cicatrized or contracted vomica, the putty or chalk-like contents being the residuary matter of the softened tubercle, the thinner portion having been expectorated or removed by absorption. In some instances, these bodies are of almost a stony hardness, grating against the knife.

In other cases, cavities lined with a smooth, semi-cartilaginous false membrane are found, containing air only, and with dilated bronchial tubes opening into the same, no appearance of ulceration being visible, everything indicating that a tubercular mass had once occupied the cavity, its softening and expectoration having been followed by a healing of the inner surface.

Morbid Growths.

Cancer. Malignant disease of the lungs is by no means frequent, yet we have abundant evidence that cancer in its

several forms may be developed in these organs. Colloid cancer, has been usually found more or less infiltrated through the substance of the lungs, while other forms appear in nodules or isolated tumors.

It is seldom, perhaps, that cancer exhibits itself as a primary affection of the lungs, the disease first appearing in some other part, and more frequently, it is said, in the bones or testicles; operation for the removal of cancer in these parts being very liable to be followed by an early development of the disease in the lungs or other internal organs. On the other hand, where the cancer is connected with any organ whose veins form a part of the portal system, as the stomach, spleen, pancreas, intestines, etc., the disease does not so frequently extend to the lungs, while in those cases the liver is more liable to become affected.

The *encephaloid* form of cancer, is that more frequently met. It may be connected either with the bronchial glands, when the diseased mass will be mainly confined to the mediastinum, and may consist of bodies varying in size from that of a cherry to that of a large apple, or, the disease may commence directly in the substance of the lungs, the tumor rapidly increasing in size, and crowding the lungs from their normal position. After death, the encephaloid mass may be found compressing the lungs into a very small space. The tumor presents the usual character of this disease, some of the lobules being soft and pulpy, or brain-like, others of a more firm, cheese-like consistence.

Melanosis. Two forms of melanotic deposits are observed in the lungs: one, *true melanosis*, and frequently associated with encephaloid disease; the other a deposit of carbonaceous matter from coal dust, smoke, etc., which has been inhaled during life, and distinguished as *spurious melanosis.*

True melanosis consists in a deposit of a dark pigmentary

matter in the substance of the bronchial glands, found at the bifurcation of the trachea, and along the main bronchi. The glands are at the same time enlarged. The coloring matter may be solid, or slightly fluid, or pasty. At the same time the melanotic matter may be infiltrated to some extent into the substance of the lungs, or deposited in cysts within the same.

In *spurious melanosis*, the dark carbonaceous matter is diffused more or less through the whole lung, and may be seen distinctly through the pleura. The bronchial mucous membrane is more or less tinged with the same substance, and generally a quantity of black-colored fluid may be expressed from the cut surfaces.

Hydatids. Acephalocysts or animal hydatids, have not unfrequently been found in the lungs, and in several instances they have been discharged by expectoration.

These cysts vary in size from a cherry to an egg, and consist of a double membrane containing a limpid fluid within which other hydatids may be found, of the same character as the parent cyst. They may excite inflammation and suppuration in the tissues around, and thus become discharged into the bronchial tubes, the pleural cavity, or through the diaphragm into the abdominal cavity.

Cystic, *Fibrous*, *Cartilaginous*, and other forms of tumors, are occasionally found in the lungs, and, while they are generally small, they may acquire such size as to become a source of trouble during life.

The Bronchial Tubes.

The examination of the trachea and bronchial tubes in post-mortem examinations, is too frequently omitted. The lungs having been removed from the chest, they may be readily opened along their posterior aspect, and the bronchial tubes traced into the substance of the lungs. The

pathological conditions of the bronchial tubes which may claim our attention, are *inflammation* in its various forms, *obliteration*, and *dilatation*.

Bronchitis. Bronchial inflammation has been divided into two varieties, according to the portion of the tubes affected. In one case the disease may be confined to the large and medium sized tubes; it is then known as *tubular bronchitis*. In the other, it is seated principally in the terminal ends, where the lining membrane is more delicate, and the tubes much smaller, and from this, extending to the air cells, forms what has been called *vesicular bronchitis*. The latter form is closely allied to pneumonia; in fact the two diseases pass into each other, and in most cases probably co-exist.

Ordinary, or *tubular bronchitis*, is not often a fatal disease, hence we cannot speak accurately of its anatomical characters; yet, being frequently associated with other forms of fatal disease, we have opportunities of examining it under those circumstances. The lining membrane is then found thickened, rough, of a dark red or brown color, with more or less contraction of the calibre of the tube, and covered with a viscid, jelly-like mucus, often streaked with blood, and in some cases of a puriform character. This form of bronchitis may occur as a primary disease, or it may accompany tubercular consumption; is frequent in cases of heart disease, and may arise in the course of typhoid fever, measles, scarlet fever, and small-pox.

Vesicular bronchitis, from its involving the smaller tubes and air cells, is much more frequently fatal than the tubular form of the disease, although in fatal cases the two forms will usually co-exist. In a post-mortem examination of these cases, we find the bronchial membrane red and injected, pulpy and thickened. In a more advanced stage, the air cells and smaller tubes are filled with a viscid, puriform mucus, which prevents the air from reaching the vesicles during life, and the

lungs from collapsing upon opening the chest after death. Minute ulcers are not uncommon upon the mucous membrane, the effect of these, being that of changing the character of the secretion from a transparent mucoid, to an opaque purulent form.

Bronchial inflammation, as has been stated in another place, may result in emphysema of the lungs. In these cases, a valvular-like obstruction is produced in some of the bronchial tubes, which, offering little impediment to the entrance of the air, interferes with its escape, and thus by producing increased pressure upon the air cells supplied by the obstructed tube, a gradual dilatation or rupture ensues, resulting in the former case in vesicular, and in the latter, in interlobular emphysema.

Disease of the heart may also result from chronic bronchial inflammation. Not only respiration, but the circulation may be so impeded as to exert a direct influence upon the heart. From the difficulty which the blood encounters in flowing through the branches of the pulmonary artery, the main trunk of that vessel becomes permanently dilated, while the right ventricle, from the increased force required to overcome the obstruction in the lungs, becomes gradually dilated, and at the same time, perhaps, hypertrophied. From the union of the two ventricles, the excessive action of the right may induce a similar action in the left, and thus in time result in that hypertrophy of both ventricles, which is sometimes found in persons who have suffered from chronic bronchitis.

Narrowing or Obliteration of Bronchial Tubes. In some cases, in carefully tracing the bronchial tubes, we may find either a remarkable narrowness of the vessel, or a complete closure of the same. In the former cases, there is a distinct thickening of the walls of the tube, by an effusion of lymph, or blood and lymph, into the submucous tissues;

or, from induration of the lung tissue around the smaller bronchial tubes, from tubercular or other deposits, a similar narrowing may result from external pressure.

Complete closure may be found in any portion of the tubes, in the large trunks, arising from the main branches, as well as in the smaller branches. They may be detected by passing a blunt probe into the tubes. The branches will frequently be found continuing from the points of closure, as a fibrous cord. The most common seat of these closures is in the upper lobe of the lung, yet they have been found in the lower lobes.

The causes of obliteration of the bronchial tubes is not well understood, yet, they are more frequently observed in persons who have suffered repeated attacks of bronchitis, or of chronic pneumonia.

Dilatation of the Bronchial Tubes. This condition of the bronchial tubes is more frequent in its occurrence than obliteration. It takes place in two forms, either several tubes are uniformly dilated, like the fingers of a glove, or a single tube may form a cavity, by undergoing a sacular enlargement. Some mechanical obstruction, by interfering with the free passage of air through the tubes, will usually have caused the difficulty, as an enlarged bronchial gland, pressing one of the bronchi. Here the free exit of the respired atmosphere being prevented, an accumulation of air takes place behind the narrowed point. Any impediment to the entrance or exit of the air into the lungs will produce irregular and forcible breathing, and throw a greater strain upon those parts especially which are in the vicinity of the obstacle. If, at the same time, the patient suffers an attack of asthma, bronchial catarrh, or whooping-cough, the violence of the cough materially aids in developing the dilatation.

The degree of dilatation is greatly variable. Tubes which, in their natural state, are not larger than a crow-quill, may,

especially in the lower and middle lobes, reach the size of the finger, while at various points, sacular dilatations may occur, which at first sight may appear as vomicæ, but which upon more careful inspection, prove to be dilated portions of the bronchial tubes. The tubes in this state are usually filled with a puriform fluid, upon the removal of which the lining membrane is seen to be reddened and softened, or perhaps ulcerated.

This condition of the bronchial tubes may frequently be detected during life. The voice is hoarse, like a person in croup. The cough is also hoarse and brazen, while the breathing is difficult, and mucus rattling is heard in the middle or lower portion of the lung.

The post-mortem appearances in cases of *foreign bodies* in the bronchial tubes, may be readily anticipated and easily recognized.

The Mediastinum.

Inflammation may arise in the anterior mediastinum, from fracture or caries of the sternum; and in the posterior, from injury, inflammation, caries, or necrosis of the vertebræ. This inflammation may also result in the formation of an

Abscess; or, ulceration and perforation of the œsophagus, or inflammation of the lymphatic glands may lead to the same results. These abscesses may reach large size, resulting in displacement of the heart, and may rupture into the pleural cavity, the trachea or œsophagus.

Tumors of various kinds, may also develop within this space, including the several forms of *cancerous growths.* The latter will frequently have their origin in the bronchial or lymphatic glands, or, perhaps, in the remnant of the thymus gland.

PART III.

THE ABDOMEN AND PELVIS.

CHAPTER I.

THE OPERATION.

THE cavity of the abdomen, may be opened without disturbing that of the chest. An incision from sternum to pubes, down the central line, and through the superficial structures, should be followed by a careful division of the tendinous portions of the muscles and peritoneum, for a sufficient space to admit two fingers, when, by introducing the same, the remaining portion may be divided without risk of injury to the intestines. A cross incision having been made at the umbilicus, the angular flaps may be turned aside, fully exposing the abdominal contents. Where the chest is opened at the same time, the transverse incision will not be required. The peritoneum, with any serous or other contents having been examined, the attention may be given to any special organ or part that may be involved, or each may be taken up seriatim.

In many instances there will be no occasion for removing any of the viscera, while in others, one or all of the organs may require so careful an examination, as to necessitate an entire removal from the body.

The *small intestines* may be removed *en masse*, or in sec-

tions. After applying double ligatures at the lower end of the illeum, and just below the duodenum, the bowel may be divided between these, when, by dividing the mesentery near its intestinal border, with either the knife or scissors, the whole mass may be removed. By means of the *enterotome*, they may now be rapidly laid open through their entire length, the contents removed, and the surface cleansed if desired for more careful inspection. Occasionally, portions only of the small intestines will require examination. By applying double ligatures, above and below the portion to be examined, the removal is effected without escape of the contents into the abdominal cavity.

In the removal of the *colon*, either in sections, or as a whole, the same care should be observed in the application of the ligatures. The rectum having been divided, it may be lifted and rendered tense, its attachments, with those of the ascending transverse and descending colon, being successively divided with the knife, and thus the whole gut removed and afterwards split open with the enterotome.

The removal of the *rectum*, for the examination of its whole length, will usually require the removal of the other pelvic viscera, directions for which will be given further on.

In all cases where the *stomach* is to be examined, it will be better first to remove it from the body. To accomplish this, both omenta should be detached from the curves of the stomach, which may be done either with the fingers or scissors. The hand may now be carried down to the cardiac end of the stomach and the fingers forced around the œsophagus without the use of the knife, and a ligature placed upon that tube. A ligature should also be placed just below the pyloric orifice, and another an inch below this. The knife or scissors may be used to divide the œsophagus close to the diaphragm, and the duodenum between the two ligatures; the stomach may then be lifted from its position without loss of any of its contents.

If the object is merely to make a chemical analysis of the contents, the stomach should be placed immediately in the vessel prepared for its reception, and carefully sealed and labelled. If, on the other hand, we may wish to examine the inner surface of the organ, it may be freely opened along one of the curves with the scissors, the contents removed, and the mucous surface cleansed with a stream of water, for more satisfactory inspection. Both the contents and the stomach, may still be preserved for chemical examination, should the circumstances of the case seem to require it.

From the manner in which the *duodenum* is bound down to the posterior abdominal walls by the peritoneum, some little care will be required in its removal. Ligatures should be applied for retaining the contents, as directed with the stomach.

The kidneys, with the suprarenal capsules, may be reached by lifting the intestines, and tearing open the peritoneum with the fingers. The gland may then be readily lifted from its position, and the vessels divided with the knife. To examine the interior, the gland may be split open longitudinally along its convex border, which will give a view of the cortical and pyramidal portions, with the interior of the sinus and pelvis. For microscopic examination, portions should be hardened in alcohol or solution of bichromite of potassa.

The spleen may be easily removed from its position, by dragging it from its bed, in the left hypochondriac region, and dividing its vessels and omental attachments to the stomach.

The pancreas may be brought into view, by tearing open the great omentum just beneath the stomach, when the gland may be seen behind the peritoneum, extending transversely across in front of the aorta. To remove it from its position will require some care, owing to its being bound

down to the posterior walls by the peritoneum, and closely attached to the duodenum by its right extremity or head.

The liver may be generally examined *in situ.* The condition and contents of the gall bladder, the size, color, density, etc., of the gland, may all be noted without removal. Where, however, we may desire to ascertain the weight of the gland, or to examine its posterior and upper surface, its removal will be required. Where the chest has previously been opened, this will not be a difficult operation. In other cases, the cartilages and ribs, forming the lower boundary of the chest, should be strongly elevated by an assistant; the operator then, by dragging down the liver, having first divided the suspensory ligament, may expose the coronary and lateral ligaments, which will require care in their division, to avoid opening through the diaphragm into the chest. The fingers should be now freely used, to peel the gland from the diaphragm. From the close connection of the liver to the ascending vena cava, this vessel will require to be divided at the upper border of the liver, close to the diaphragm, and again, after the gland has been rolled from its bed, at its lower border, with also the portal vessels, hepatic artery and duct, which reach the transverse fissure through the border of the lesser omentum.

The liver may now be lifted from the body, and placed in any convenient vessel for a more detailed inspection.

The Pelvic Viscera.

The whole *pelvic viscera,* with the external organs of generation, in either the male or female, may be removed together, in the following manner:—Apply a double ligature to the upper portion of the rectum, and divide the gut between. The peritoneum may now be divided around the border of the pelvis, in the female, at the same time, cutting

across the round and broad ligaments of the uterus, when, with the hand, the bladder may be stripped down from the inner side of the pubes, the rectum torn from the hollow of the sacrum, and in the same manner the parts torn off from the sides of the pelvis, using the knife only for dividing the more closely adhering points.

Now, after flexing the thighs upon the abdomen, an incision may be made through the skin of the mons veneris just over the anterior commissure of the vulva of the female, and over the penis of the male, and then carried back upon either side of the genital organs, meeting behind the anus, near the point of the coxcyx. This incision may be carried through the superficial tissues, down to the pubic arch, when the crura of the penis, or clitoris, may be detached from the rami of the pubes, by carrying the knife close to the bone. The finger may now—after a slight use of the knife—be pushed beneath the arch of the pubis, and made to appear in the pelvis. Taking this as a guide, the knife may be introduced at this opening, and carried deeply along the ramus of the ischium and pubis of either side, dividing the levator ani muscle and pelvic fascia. The bladder may now be drawn forward beneath the arch, this followed by the rectum, deep incisions being carried back to the tuberosities of the ischia and point of coxcyx, and thus the whole mass removed entire.

The external parts may afterwards be so drawn together by stitches, as to make the absence of the external organs scarcely noticeable, while a bundle of rags crowded into the pelvis from above, will prevent the possible escape of any of the abdominal contents.

Where the *internal organs* only, are required to be removed; after they have been detached upon all sides as before directed, the knife may be carried down beneath the pubic arch, and the urethra divided, in the male, just in advance of the prostate. Incisions may now be carried back

upon either side of the bladder and rectum, dividing the levator ani muscle, when, by drawing upwards upon the mass, the rectum, and in the female, the rectum and vagina, may be divided near their lower ends, and the whole removed together.

In many cases it may be desired to remove the uterus of the female alone. This may be done by dividing the broad and round ligaments upon either side, when, by dragging the uterus forcibly upwards, the vagina may be cut across about an inch below the cervix, and thus the organ removed. In all cases, a few rags should be crowded into the pelvis for the purpose of preventing the escape of any fluids.

In hospital cases, where parts are to be exhibited to a class, and especially if several organs are involved in the disease, the whole thoracic and abdominal viscera may be removed together and brought before the class on a large tray. This may be effected in the following manner:—A single incision may be carried from the upper end of the sternum to the pubes, and the sternum removed in the usual manner. The trachea and œsophagus, with the large vessels of the arch of the aorta, may now be divided at the root of the neck. Grasping the arch of the aorta and the trachea, the whole thoracic contents may be stripped from the spinal column. The diaphragm being now separated from its attachment to the ribs on either side and the spinal column, the whole abdominal contents may, in the same manner, be dragged from above downwards, the rectum tied and divided, and the contents of the two great cavities removed entire and with little disturbance of the relation of parts.

In closing up the cavity after the examination is completed, the viscera having been replaced, a sufficient quantity of wheaten bran or clean sawdust should be thrown in to absorb any remaining fluids, thus preventing their escape after the sewing up of the incisions.

CHAPTER II.

PATHOLOGICAL CONDITIONS.

Section I. OF THE PERITONEUM.

[**Notice** in examination:—1. *Contents of cavity*—serum; amount, color, coagulable or not; *pus*—amount, consistence, odor, source; *blood*—amount, source; foreign bodies; gall-stones; worms. 2. *Condition of membrane*—color, transparency, rough or smooth, moist or dry, thickness; *adhesions*—position and strength of. Vascularity; ulcers; perforations; tubercles; tumors; wounds, etc.]

This membrane we find liable to *congestion*, *inflammation*, *gangrene*, *effusions*, and *morbid growths*.

Congestion of the peritoneum, may result from obstructed circulation through the liver, or ascending vena cava, or from inflammatory action; and may terminate in serous effusions into the abdominal cavity, or thickening of the membrane. The redness of congestion, may be distinguished from that of inflammation, by the larger vessels appearing more involved, and by the absence of any plastic effusions.

Inflammation of this membrane, (*Peritonitis*,) may be either acute or chronic.

Acute peritonitis, in most instances, commences at some one or more points, and from this gradually diffuses itself over the membrane until it becomes general. Such point of inflammation may commence immediately over some inflamed, or ulcerated, or perforated spot in the intestines, or in the peritoneal covering of an inflamed uterus, liver, etc., or as the result of external injury.

In the early stage of peritonitis, the injected vessels give the membrane a more or less red appearance, which will be

more marked in streaks and patches. From the readiness, however, with which fibrinous exudation takes place from this membrane, this redness is seldom very strongly marked, and in some instances will scarcely be noticed, unless the surface is carefully scraped, thus removing the exudation.

Small extravasations of blood are occasionally found in the substance of the membrane. The muscular coat of the intestines, where the peritoneal covering is involved, may become infiltrated with serum, the fibres relaxed and paralyzed, thus permitting of the great tympanitic distension found in these cases.

Chronic peritonitis, is not a very common occurrence. It may, however, follow an attack of acute peritonitis, and is sometimes found in connection with ascites, or tubercular deposits in the peritoneum. In examining the body of a colored woman who had died of heart disease, accompanied with general dropsy, and who had suffered abdominal pain and tenderness for a number of weeks previous to death, a large portion of the peritoneum, particularly that reflected upon the abdominal walls, was found intensely red, the blood-vessels having an arborescent arrangement, and being beautifully injected. No plastic matter was found effused upon the surfaces. The cavity contained some twelve quarts of serum.

Fibrinous Exudation, as already observed, readily follows inflammation of this membrane. It will often be found as a uniform layer covering the whole surface of the peritoneum, rendered more apparent, however, by separating parts, when it appears as delicate bands or filaments, stretching across the interspace. In cases of acute inflammation, this plastic effusion is often very great, and frequently intermixed with purulent matter, while the serous fluid, which is poured out in considerable quantities in these cases, is rendered turbid by the presence of numerous flakes of

fibrin, and quantities of pus cells diffused through the same. More or less extensive and firm adhesion of parts may thus be induced, the plastic matter effused becoming more and more firm, and finally converted into dense bands of fibrous tissue.

Mechanical obstruction and strangulation of the bowels, may be induced by the presence of these bands, stretching between parts, and forming thus an opening through which the bowel passes, and finally becomes incarcerated.

Suppuration is not an unfrequent result of acute peritonitis; the matter being found uniformly smeared over the whole surface, or, in some cases, confined to a single part, thus forming a circumscribed abscess. Adhesions having taken place around the boundaries of the suppurating surfaces, in this manner the diffusion of the matter is prevented, and its discharge into the intestinal canal, or in some instances upon the surface of the body, is promoted.

Gangrene of the peritoneum may result from intussusception or hernial incarceration of some portion of the bowel, when the part will appear as a softened, dark, offensive mass, limited by a band of highly congested tissue.

Ascites. Dropsical accumulations in the abdominal cavity, may result from obstructed circulation, caused by disease of the liver, kidneys, heart or lungs; or from pressure upon the vena cava, or portal vein, by some abnormal growth.

The fluid effused may be nearly colorless, or present various shades of yellow, red or green, and usually coagulates on the application of heat. The peritoneum may appear unchanged, or it may present a thickened, opaque, white or macerated appearance, in chronic cases.

Blood may be found in the peritoneal cavity, as a result

of wounds, rupture of some of the abdominal or pelvic organs, or bursting of an aneurism.

Morbid Growths.

Tubercular Deposits, of the miliary form, are not unfrequent in the peritoneum. They may be diffused over the whole membrane, as semi-transparent, gray granules, but more frequently are found on the under surface of the diaphragm, in the neighborhood of the spleen, and on the viscera generally, while the parietal layer is more free. The tubercles, acting as foreign bodies, give rise to inflammation, usually of a chronic form, but sufficient to result in exudation of lymph, and the formation of adhesions between the adjoining surfaces. Softening of the tubercular deposits sometimes takes place, and perforation of the intestinal wall results, leading to an effusion of the intestinal contents into the peritoneal cavity.

Cancer of the peritoneum, is sometimes seen as a primary affection, yet it more frequently extends to this membrane from some of the deeper parts. The encephaloid variety may be met with, but the colloid form is that most frequently seen. The omentum is the occasional seat of this form of cancer, the membrane in such cases becoming enormously increased in size.

Tumors of various kinds, including *fibrous*, *fatty*, and *cystic*, may be found in the peritoneal cavity, generally having had their origin, however, in the sub-peritoneal tissues. *Fatty* tumors may originate within the substance of the omentum or mesentary, while *cystic* tumors may be found within the broad ligaments of the uterus or ovaries.

Section II. OF THE STOMACH.

[**Notice** in examination:—1. *External characters*—position; size; form; adhesions. 2. *Contents*—quantity, color, odor, reaction. *Food*—its nature, degree of digestion. *Blood*—pure or mixed with food; probable source. *Foreign substances*—powders, metallic particles, spirits, fœcal matter, bile, pus, worms. 3. *Mucous membrane*—general condition of; color, soft or firm, rugæ present or absent; thickness at various points; ulcers; their position, size, etc. 4. *Muscular coat*—thickness; visibility of fibres. 5. *Entire walls*—transparency; wounds; perforations; ruptures; weight. 6. *Condition of orifices*—constricted; dilated. *Tumors*—position, size, character, etc.]

Few organs of the body are subject to such a variety, or to such early *post-mortem* changes as the stomach, many of which, being closely simulative of the effects of disease, render a satisfactory examination of this organ, in many instances, very difficult. Therefore, before entering upon an account of the morbid anatomy of the organ, I shall briefly notice those changes which are *post-mortem* in their origin.

The ordinary interval which intervenes between death and a post-mortem examination, is, in most instances, sufficient to seriously change the appearance even of the healthy stomach. Hence our knowledge of the healthy appearance of that organ, at least, previous to the experiments of Dr. Beaumont upon the stomach of Alexis St. Martin, was quite imperfect.

Post-Mortem Changes.

Among those changes taking place after death, which are no evidence of disease during life, may be mentioned:

First. Appearances of Congestion. Very soon after death, or at least within ten or twelve hours, by gravitation of the blood, the same *hypostatic congestion* will be found in the most dependent portion of the stomach, that is seen in a more marked degree in the lungs, or in the subcutaneous tissues.

Second. Coloring of Tissues. Not unfrequently, the tissue of the stomach will be found strongly tinged by coloring matter of food or medicine, such as the red color of wine or logwood, or the black color of the metallic sulphurets, etc.

Third. Change of Shape and Size. Variations in the shape and size of the stomach from the normal standard, are not unfrequently found after death. It is sometimes found unusually small, apparently from the influence of the *rigor mortis*, the contraction necessarily resulting in increased thickness of the walls. What is known as hour-glass contraction, although sometimes congenital in its origin, is frequently but a manifestation of the *rigor mortis*, when it may be distinguished from the former by inflation. Extreme dilatation, with thinning of the walls, is also sometimes seen, this condition resulting apparently from an absence of the post-mortem contraction.

Fourth. Exfoliation of Epithelium. The stomach of young adults, dying of some acute disease, not unfrequently is found to have thrown off the epithelial layer of its mucous lining, even when the examination is made soon after death, and in cold weather. In many of the healthiest animals slaughtered for food, the same change has been noticed as early as two hours after death. The detached cells are found floating in a thick mucus, the microscope also showing that the gastric follicles have thrown off their epithelial lining, with their pepsinous contents. With this change commences the post-mortem digestion of the stomach, to be soon noticed.

The younger and healthier the subject, and the more acute the disease causing death, as a general rule, the more rapidly and effectively does this exfoliation take place. It may affect only the summit of the folds into which the mucous membrane is thrown by the contraction of the muscular coat, or it may uniformly involve the whole mucous surface.

Fifth. Softening and Perforation. It is an interesting

fact, that while the tissues of the stomach during life are unaffected by the gastric juice—the vitality of the tissues enabling them to resist its solvent power—after death, they immediately yield to its influence, and hence results a greater or less degree of softening of the coats, or even in some instances, complete perforation of the walls, the extent of the change depending upon the quantity of gastric fluid in the stomach at the time of death. In these cases there is, of course, no evidence of inflammation, while the tissues present a pulpy, gelatinous appearance, the walls being greatly thinned, and breaking down under the slightest force. In most instances, probably the *actual perforation* is the result of the force employed in lifting the stomach from its position. The opening in these cases is an irregular ragged hole, with soft, pulpy margins, and will more frequently be found at the large or cardiac extremity of the organ.

In some extreme cases, the process of softening has not been confined to the *walls* of the stomach, but has extended to the adjoining organs, as the spleen, liver, or diaphragm.

The whitish-gray and gelatinous appearances of these cases, will enable us to distinguish them from ordinary cases of softening and perforation from ulceration.

This form of softening is especially observed in cases of sudden death immediately after a meal, while the stomach contains a large quantity of gastric juice. It is also seen much more frequently in children and young persons than in the aged, or those dying from chronic forms of disease. It has often been noticed in cases of consumption, however, which is to be accounted for upon the fact that many of these patients retain a good appetite to the last.

Brinton, is of the opinion, that the solvent action of the gastric fluids upon the walls of the stomach, is promoted by the presence of vegetable or starchy food:—(1) by offering little substance upon which the fluids can expend themselves; and (2) by producing by its decomposition, an

amount of acid, favoring an energetic action of the gastric fluids; while on the other hand, the action of those fluids is retarded, (1) by the presence of alkaline saliva, or bile in any quantity; and (2) by the presence of animal food upon which the juices may act.

CASE .—*Perforation of the Stomach in a child two years of age—death from Hydrocephalus.*

A child of Mr. T——, in its second summer, had an attack of hydrocephalus, finally dying in convulsions. The autopsy, made twenty-four hours after death, disclosed great congestion of the membranes of the brain, with two ounces of serum in the ventricles. Upon opening the abdominal cavity, all the viscera appeared healthy. In lifting the stomach from its position, a gush of colored fluid appeared from behind it, which at once led to the suspicion of a rupture. The whole organ was then carefully removed, when a ragged rent, through which the thumb could readily be passed, was discovered at the posterior portion of the cardiac end. The walls of the stomach at this point were extremely thin, soft and jelly-like; this condition being plainly the result of the post-mortem action of the gastric juice, while the rupture was the immediate consequence of lifting the organ from its position.

Pathological States of the Stomach.

Gastritis. *Acute inflammation* of the stomach rarely occurs, except as a result of some chemical or mechanical irritation. From the experiments of Dr. Beaumont, however, we learn that the stomach is extremely liable to various grades of inflammatory action, which passing rapidly through their several stages, end finally in recovery. By watching the effects of excesses in the use of alcoholic stimulants, food, condiments, and of exercise after meals, etc., he observed that the pale, pink color, natural to the mucous membrane of the healthy stomach, was exchanged for a somewhat livid erythematous redness, which was distributed throughout the organ in irregular patches of various sizes, and in its most intense form, amounted to a kind of ecchymosis.

Again, he noticed an excessive growth of epithelium, forming patches of false membrane like, which at various points appeared distended by an accumulation of a puriform fluid beneath, giving the appearance of little pustules.

The following forms of gastritis are generally recognized:

1. *Catarrhal Gastritis.* This, in its *acute* form, is seldom seen in post-mortem examinations. *Chronic Catarrhal Gastritis,* however, is by no means uncommon, and may be a result of the use of alcoholic drinks, the presence of various irritating substances taken either as food or medicine, and may attend many forms of chronic disease of other organs, or may be caused by obstruction to the circulation from disease of the heart, liver or lungs.

The post-mortem appearances are neither very marked, nor constant. The mucous membrane may be found red, or of a dark color, thickened and sometimes roughened. The submucous and muscular coats may also be thickened, while less frequently, small ulcers may be found.

2. *Croupous Gastritis.* This form is very rare, and seldom diagnosticated during life, but may be found with children who have died with croupous inflammation of the air passages, when small patches of false membrane may be found adhering to the mucous surfaces. It may be found in adults also, as an attendant of certain grave forms of disease, as typhus, puerperal fever, cholera, dysentery, or in death from irritating poisons.

3. *Phlegmonous Gastritis,* is another very rare form of inflammation of the stomach, in which the disease involves all the coats, although originating in the submucous, and may destroy the patient in a few days with symptoms of peritonitis. The submucous tissues will be found filled with an exudation of a sero-plastic, yellowish substance, which produces thickening of the walls, and which may be confined to a portion or involve the whole organ.

Effects of Poisons. The effects of caustic and other irritant poisons upon the stomach, as exposed by a post-mortem examination, will vary according to the nature of the substance, and the time it may have remained in the stomach. Redness in various degrees, and of various shades, ulceration, softening and perforation, may one or all, be detected in different cases.

In large quantities, the mineral acids may leave the mucous membrane black, and of a soft, tarry consistence, readily breaking down upon handling the stomach.

The peculiar action of the several poisons will be noticed in another place. (See Part IV.)

Gastric Ulcer. Ulceration of the mucous membrane of the stomach, is much less frequent than of other portions of the intestinal canal, except as a result of the corrosive action of poisons.* A peculiar kind of ulcer, however—rare in this country, but said to be common on the Continent of Europe and in England—is sometimes found, which is of interest, from its occurring in tissues otherwise healthy, and often leading to a rapidly fatal termination. Rokitansky terms it the *perforating gastric ulcer*, from its marked tendency to perforate the walls of the stomach. It is situated in the region of the pylorus, and more frequently at the posterior surface and near the lesser curve. It is of a circular form, of three to six lines in diameter, and with as sharp edges as if a round piece of the walls had been punched out; the edges being bevelled off, however, from within, leaving the peritoneal opening less than that in the muscular or mucous coats. Being usually situated near the lesser curve of the stomach, some of the larger blood-vessels are liable to become involved, giving rise to hæmorrhage more or less

* See Nos. 1309 and 1351 College Museum.

severe. While but a single ulcer of this description is generally found, two, three or more, may be present.

A peculiarity of this form of ulcer, consists in its not being dependent upon irritation or inflammation, but rather upon a loss of vital assimulative power in the part affected.

This form of ulcer may heal at any time previous to perforation, and it is not uncommon to find a cicatrix in the mucous membrane of the stomach which has probably arisen in that way.

Gastric ulcer is much more frequent in females than males, and is mainly a disease of middle and advanced life.

Hæmorrhagic Erosions. The appearance of the stomach, where there has been frequent vomiting of blood from this cause, is thus described by Rokitansky: "There are several roundish spots of the size of a pin's head or pea, or narrow elongated streaks at which the mucous membrane appears dark red, lax, soft and bleeding, and presenting a depression in consequence of loss of substance or slight erosion. This condition is invariably accompanied by hæmorrhage, the effused blood being mixed, in a more or less altered state, with gastric mucus. The erosions are often very numerous, studding, perhaps, every part of the stomach, except the fundus, the pylorus being their chief seat."

This condition of the stomach is not peculiar to any form of disease, or age, but is frequently associated with intemperance. It is rarely fatal, except by inducing some other lesion of the stomach, or by being united with some more general malady.

Softening of the Stomach. We have already referred to that form of softening of the stomach, which is attributed to the action of the gastric juice after death. Another form is sometimes met with, which evidently takes

place during life, and in most instances is attributable to a chronic form of inflammation. It is not always easy to distinguish the two forms of softening without a knowledge of the previous history of the case. The distinction may, however, generally be made by attending to the following points:—1. The presence during life, of symptoms of disease of the stomach. 2. Appearances of congestion or inflammation, as well as softening, after death. 3. Extension of the morbid change to other portions than that affected by post-mortem softening, the latter being usually confined to the posterior portion of the cardiac end.

Cirrhosis of the Stomach. In some obscure cases of gastric disease, upon opening the abdominal cavity in a post-mortem examination, we may at once notice a marked change in the appearance of the stomach. It presents a peculiar whiteness and opacity, an appearance which is partially due to a dulness of the peritoneal coat, in marked contrast with its usual brilliancy; at the same time the organ may be either larger or smaller than the average size. Upon removing the organ, we find it greatly increased in weight and density, and presenting a hard, gristly feel, and with so much elasticity as to fail to collapse. An incision shows the walls uniformly thickened, to the extent of six or eight times their normal condition; the whole organ is comparatively bloodless, a condition strongly in contrast with the usual appearance after death.

A close inspection of such a specimen, shows the several coats—muscular, mucous and fibrous—to be remarkably alike, the thickening and increased density, resulting from the presence of a generally diffused imperfect fibrous structure, similar to that found in common fibrous tumors. The several coats of the stomach will be found unequally affected by this deposit. The submucous structure, as seen in a vertical section, being increased from ten to twenty fold,

while the serous with the subserous may be increased seven to ten fold. The muscular tunic may be found from five to eight times its normal thickness, while the mucous membrane proper, is seldom more than double.

Notwithstanding the bloodless character of the walls of the stomach in this disease, the abnormal condition is unquestionably the result of a chronic form of inflammation. The symptoms during life are usually obscure, and although the hard contracted stomach may form a sort of epigastric tumor, noticeable upon the surface, the absence of acute symptoms, with the age at which the disease makes its appearance—usually between twenty and thirty—permits of a ready distinction being made between this disease and cancer, with which it might otherwise be confounded.

Atrophy of the Stomach. This condition of the stomach can hardly be looked upon as an independent malady, being rather an attendant of the general wasting of certain diseases, particularly of pulmonary consumption, marasmus, and starvation. The organ, in these cases, may be reduced to less than half its normal proportions, while its walls may be thinned and frequently softened.

Dilatation of the Stomach, is another condition that can scarcely be considered as a primary affection. A great variation in the size of this organ is evidently compatible with health, large eaters having necessarily large stomachs, yet as the result of certain other morbid conditions, dilatation to an enormous extent may be induced.

The following conditions may result in dilatation :

1. Obstruction of the pylorus, as in scirrhus of that portion of the stomach.

2. Destruction of a segment of the muscular coat by ulceration, or by becoming involved in a cancerous growth. Here the loss of contracting power, permits of a gradual

dilatation, from the inability of the segment involved to aid in carrying on the contents, their accumulation above this point aiding in the distension.

3. An acute form of dilatation is sometimes met with, which can only be attributed to a paralysis of the muscular and secreting structures of the organ. It occasionally happens to a patient recovering from a fever. He has perhaps over-indulged in eating, as is not unfrequently the case with convalescents, and is suddenly seized with intense pain in the stomach, followed by rapid and great distension, and finally death. The autopsy discloses the stomach enormously distended, and its contents, including matters, in some cases, which were injested many days before. The mucous membrane appears but little changed, while the muscular coat is so thinned and stretched, as to appear like a scattered network of fibres.

Morbid Growths.

Cancer. This formidable disease occurs more frequently in the stomach, than in any other organ of the body, excepting the uterus of the female. The disease is usually primary in this organ, but frequently springs up secondarily in other parts.

The disease may occur in the three following forms—the *scirrhus*, *medullary*, and *colloid;* while Dr. Brinton adds a fourth, the *villous* cancer of the mucous membrane. The usual seat of the disease is at the pylorus. It may involve a portion or the whole circumference of this opening, and from this extend along the lesser curve. In some cases, it commences at the cardiac orifice, and very rarely involves the whole organ, the fundus usually remaining free. The walls of the stomach may become greatly thickened in this disease, the inner surface tuberculated and roughened, and the cavity much diminished in size. When situated at the

pyloric end, the disease seldom or never extends into the duodenum, but when at the cardiac, it generally involves the lower portion of the œsophagus.

The *fibrous* or *scirrhus* form of the disease, is by far more commonly met with than any other, although it may be found occasionally combined with the medullary, or both these with colloid. Indeed, it is not improbable, but that in many cases, a growth originally scirrhus, becomes gradually converted into one of the other forms.

In almost all cases, cancer commences in the submucous tissue, in the form of a dense mass, of a white color. When cut, the surface presents a whitish-gray appearance, contrasting strongly with the vascular mucous membrane of the stomach, and presenting a distinctly striated appearance. A small portion under the microscope, or the juice scraped from the cut surface, will show the peculiar cancer cell, with granular matter.

Encephaloid or medullary cancer, may be developed upon or within the fibrous form, or it may occur primarily as knotty tumors projecting through the mucous membrane. The miscroscopic appearance is much the same as in the fibrous variety, except that the cells are not so closely packed, but are loosely held together by an abundant, soft, or liquid substance.

The *colloid* form of the disease, may originate either in the mucous membrane itself, or in the submucous tissue. It is known by its presenting a tough, fibrous-looking, white tissue, which, arranged in intersecting bands, incloses irregular spaces, which are filled with a clear, soft, or semi-liquid material, the proper colloid substance.

The *villous cancer*, Dr. Brinton describes as arising in the basement membrane of the mucous coat, and as but a modification of the epithelial cancer of other parts of the body.

The mucous membrane covering cancerous growths, is subject to a variety of changes. It may become converted

into a sort of fungoid growth, which at points suppurates, showing the submucous scirrhus tissue; or it gradually softens, giving rise to hæmorrhages.

The cancerous mass itself, may also soften or suppurate, resulting perhaps in perforation and peritonitis; or adhesions may take place, followed by extension of the disease to the liver, spleen, pancreas, kidneys, etc.

Cancer of the stomach, in the great majority of cases, occurs in persons between fifty and sixty years, although it may appear as early as forty, or as late as sixty. Males appear to be more subject to the disease than females, in the proportion of four to three.

The *obstruction* which the presence of cancer of the stomach is liable to produce, may result in one or more of the following conditions:

First, *hypertrophy* of the muscular coat. From increased nutrition, the muscular fibres of the stomach may become considerably increased in size and darker in color, thus better enabling them to overcome the obstruction, which in some cases, amounts almost to occlusion.

Second, *dilatation.* This condition frequently attends the former, and indeed is seldom seen alone. It is confined to those cases where the cancer is at the pylorus, and is more noticeable at the fundus of the organ.

Third, *contraction.* This is seldom seen in connection with hypertrophy, and is far less common than dilatation. Generally found in connection with cancer at the cardiac orifice, it may be looked upon as the result of the constant regurgitation which the obstruction produces, preventing thus the cavity of the organ from undergoing its normal distension, by the presence of any quantity of food.

Tumors. With the exception of cancerous growths, tumors of the stomach are by no means common.

Fatty tumors are sometimes met with, originating in the

submucous tissues, and as they increase in size, they may crowd either inwards towards the gastric cavity, or outwards towards the peritoneum.

Fibroid tumors, are also occasionally met with in the submucous tissues, generally in the line of the lesser curve, and about the cardiac orifice.

Polypoid growths may also be found springing from the mucous surface, presenting the character of those formations usually.

Section 2. THE INTESTINES.

[**Notice** in examination:—1. *External characters*—displacements, as in hernia; amount and condition of involved bowel. *Invaginations*—number, position and size; dilatations or contraction of intestines; apparent cause of. *Peritoneal coat*—inflamed or not; adhesions; their position, strength; perforations, etc. 2. *Contents*—gas; mucus; blood; pus; fæcal matter; foreign substances, etc.; particulars in regard to each. *Entozoa*—number and character. 3. *Mucous membrane*—general condition; congested, inflamed, ulcerated. Orifice of bile duct. *Brunner's glands*—inflamed, enlarged or ulcerated. *Peyer's patches*—number, situation, general condition, ulceration, etc. 4. *Cœcum* with *appendix vermiformis*—length, contents, ulcers, perforations, etc. 5. *Rectum*—prolapsus, hæmorrhoids, fistulæ.]

Malformations. The intestine is sometimes defective in some part of its course, most usually near its lower extremity, and generally accompanied with an imperforate condition of the anus, (*atresia ani.*) This latter may be of various degrees, consisting sometimes in a simple closure of the anus by a continuation of the integument over it; in other cases the rectum terminates in a blind pouch at a greater or less distance from the anus.

Sometimes the intestine is unusually short, without any distinction as to size between the large and small intestines.

It may terminate at the umbilicus, or in a cloaca common to it and the genito-urinary organs.

Finally, it may consist of several detached cœcal portions.

Andral notes the following malformations:—A single

straight canal from the termination of the œsophagus to the commencement of the rectum; a double duodenum; two colons; an unusually large, and at same time, double appendix vermiformis.

Diverticula are not unfrequent. They are cœcal appendages, resembling the finger of a glove, one or more in number, varying in length from a few lines to several inches, and giving off at various points. Like the appendix vermiformis, they may become a source of danger by affording a lodgement for indigestible matters.

In very rare instances the position of the intestines has been found completely transposed, with a corresponding transposition of all the abdominal viscera, or of only one organ.

Inflammation. Vascular injection by itself cannot be taken as a decisive proof of the existence of inflammation. Obstruction to the free return of blood by the veins, during life, and the gravitation of blood to the most dependent parts, after death, especially after fevers, can and do produce this very marked injection. In general, however, the smaller and more isolated the patch of injection is, the more likely it is to be inflammatory in its origin.

Catarrhal inflammation may be either acute or chronic, and may either attack the mucous membrane uniformly, or be developed mainly in the villi and follicles.

In the *acute* form: "There is more or less intense redness and injection of the mucous membrane, affecting its entire surface, or appearing as punctiform reddening from affection of the villi, or as a vascular halo surrounding the follicles; relaxation of the tissue, and intumescence of the mucous membrane, equally affecting the entire surface, or only the villi and follicles; opacity of the mucous membrane and its epithelium, from infiltration of the former and softening of the latter; friability and softening of the mucous

membrane. The submucous cellular tissue is injected, relaxed and infiltrated with a watery opaque fluid; the secretion is at first copious and serous; as the affection increases in intensity it becomes opaque, viscid and puriform."

In the *chronic* form, besides the above signs, we have also a dark, rusty, livid discoloration, sometimes pervading the entire mucous membrane; the mucous membrane and its follicles are swollen, the tissue has become more dense, and the surface covered with an opaque, grayish-white, or puriform mucus. Polypoid excrescences are sometimes found upon the mucous membrane.

Both the large and the small intestines may be affected by catarrhal inflammation, although the chronic form seems to occur more frequently in the large.

The muscular coat of the intestines is also sometimes the seat of inflammation, rarely if ever, however, as a primary disease, but by extension from the serous covering or mucous lining.

Croupous Inflammation. The mucous membrane is also subject to a chronic or sub-acute form of inflammation resulting in the production of an exudation much resembling that of croup. Sometimes it forms in a layer of some thickness, pretty uniformly over the surface, or appearing in the stools as tubular casts of the intestines; sometimes it is very thin, or consists of mere shreds. The anatomical changes observed will be similar to those just noticed.

Perityphlitis is an inflammation of the loose areolar tissue around the cœcum, occurring primarily or in consequence of typhlitis. If not checked, it ends in the formation of abscess in the right iliac fossa, which may discharge either into the neighboring viscera, or externally through the abdominal walls, mostly near Poupart's ligament.

Peripractitis is an inflammation of the areolar tissue around the rectum. The resulting abscess discharges either externally, back of the anus, or in the perineal region, or

internally into the rectum, or more rarely into the bladder, the vagina, the uterus, or into some other part of the intestines. Fistula in ano, frequently originates in this manner.

Ulceration. Ulceration may occur as the result of inflammations both catarrhal and croupous, and whether commencing in the mucous or the muscular layer, the ulcers may perforate the intestinal walls and give rise to an escape of the contents; or the ulcers may cicatrize with the formation of the usual fibroid tissue, which, by subsequent contraction, may give rise to puckering or obstruction.

In follicular ulceration of the colon, after lientery or tedious diarrhœa, the follicles are at first tumefied, and project as smaller or larger, round, conical nodules on the internal surface of the intestine, surrounded by a dark-red vascular halo. Ulceration takes place in their interior; an abscess with red, spongy walls appears; the follicle is eaten away, and an ulcer of the size of a pea or lentil is formed. The mucous membrane is extensively destroyed, and with great rapidity. The disease is always confined to the colon, but when it runs a very rapid course, it may be accompanied with catarrhal inflammation of the small intestines.

Typhus ulcers. In continued fevers where the disease especially attacks the intestines, we find an ulceration of Peyer's patches and the solitary glands, which is called *typhus ulceration* by Rokitansky, and is thus described by him:—"After a preceding hyperæmia around the solitary follicles, and in and around Peyer's patches, there is an enlargement of the glandular structures, followed by a softening and breaking down of the glandular mass. The cavity remaining on the mucous membrane after the discharge of this mass constitutes the typhus ulcer. Its form is elliptical, if a large patch has been destroyed; round, if a smaller patch or a solitary gland has been destroyed.

Partial destruction of a patch will produce an ulcer of irregular shape. The size varies also, according to the amount of ulceration."

The margin of the ulcer is invariably formed by a well-defined fringe of mucous membrane, which is a line or more wide, detached, freely movable, of a bluish-red, and subsequently of a slaty or blackish-blue color. The base of the ulcer is formed by a delicate layer of submucous tissue, which covers the muscular coat. The lower third of the small intestine is most liable to be involved in the ulcerative process, the number and size of the ulcers increasing as they advance toward the ileo-cœcal valve.

Dysentery may also produce extensive ulceration of the colon, with considerable loss of substance. This loss may be repaired by cicatrization. In some cases, the cicatrix tissue, condensed into fibrous bands, forms projections into the cavity of the intestine, and not unfrequently encroaches upon its calibre in the shape of valvular or annular folds, giving rise to stricture of the colon.

Dilatation. Disease of the nervous centres, inflammation of its serous tissue, or simple atony of the muscular fibres, may be the cause of inaction of the intestine and consequent distension. Stricture will also produce distension above itself, by an accumulation of the contents of the intestine. In these latter cases, the dilatation is often enormous.

Contraction of the intestines may occur throughout a considerable extent, or in a very small part.

In the former case, it results from the canal having been for some time empty, and is most likely to occur below a stricture. It can hardly be considered in itself a morbid condition.

The second kind of contraction or constriction, is generally

morbid, and may result either from external pressure by tumor or otherwise, or from a disease of the tissue itself. The cicatrices of ulcers which have assumed an annular shape, are the most frequent causes of stricture originating in the intestine itself.

Displacements. The most common of these constitute the various forms of hernia.

1. *Inguinal Hernia.* Here the intestines escape by the inguinal canal, and it is *Scrotal* in man, when they descend into the scrotum, and *Pudendal* or *Vulvar* in woman, when into the labia majora.

2. *Crural* or *Femoral Hernia;* when the intestines escape by the crural canal.

3. *Hernia at the Foramen Ovalis;* when the viscera escape through the opening which gives passage to the obturator vessels.

4. *Ischiatic* or *Sciatic Hernia;* when it takes place through the sacro-sciatic notch.

5. *Umbilical Hernia;* when it occurs at or near the umbilicus.

6. *Epigastric Hernia;* occurring through the linea alba, above the umbilicus.

7. *Hypogastric Hernia;* when it occurs through the linea alba, below the umbilicus.

8. *Perineal Hernia;* when it occurs through the levator-ani and appears at the perineum.

9. *Vaginal Hernia;* occurring through the parietes of the vagina.

10. *Diaphragmatic Hernia;* when it passes through the diaphragm.

A more detailed description of hernia belongs to works on surgery.

A hernia, if not reducible, may, by becoming strangulated, give rise to constipation, hiccough, vomiting, and all

the signs of violent inflammation. Gangrene supervenes, with alteration of the features, small pulse, cold extremities, and death.

Incarceration, is a form of mechanical obstruction of the bowels, differing from hernia, in there being no escape of the intestine from the abdominal cavity, as in the latter case. It may arise in various ways, but the most frequent form is that in which a portion of intestine becomes constricted by means of fibrous bands which have formed as a result of peritoneal inflammation. Passing from one portion of the intestines to another, or from the intestines to the abdominal walls, a loop of bowel may slip beneath or between these bands, and become so compressed, as to interfere with the passage of the contents, and result in great dilatation of the gut above the point of stricture. Complete strangulation may finally result, and the patient die with symptoms of mechanical obstruction.

Another, but less frequent form of incarceration, is where a portion of intestine slips through the foramen of Winslow, or through a congenital opening in the mesentery, as in the following

CASE:—*Death from Strangulation of the Bowel, from becoming Incarcerated in an opening in the omentum.*

Mary H——, aged five years, was taken suddenly with great pain in the bowels at 2 o'clock A. M., having retired the night before in perfect health. Vomiting soon set in, accompanied with great thirst, and the whole body became bathed in a profuse cold perspiration. The severe pain continued, and the vomited matter became stercoraceous. I saw the case at 10 o'clock A. M., and then found the child in a moribund condition. The breathing was rapid; pulse very small and frequent; skin pale, damp and cold; eyes sunken and nose pinched. Rapidly sinking, she died at 12 M.

Autopsy twenty-four hours after death. Upon opening the abdominal cavity, a large portion of the intestines was found of a dark purple or black color, while the remainder was perfectly natural in color.

Upon lifting the bowels and exposing the mesentery, there was found an opening in the latter, of sufficient size to receive the thumb, and through which a large portion of the small intestines had become crowded, producing such a twist in the border of the mesentery as to have produced complete strangulation of the bowel, which had rapidly passed into a gangrenous state, resulting in violent shock and death in less than twelve hours.

The opening was situated at about one inch from the intestinal border of the mesentery, and was plainly congenital in its origin, as indicated by its smooth and rounded edges.*

Another form of obstruction is sometimes found, and known as

Volvulus, in which a loop of bowel, generally of the small intestines, becomes twisted upon itself, the constriction at the base of the loop, finally resulting in complete closure.

Intussusception, or invagination of the bowels, consists in the slipping of a portion of intestine into itself, and generally from above downwards. Either the large or small intestines may be found in this condition, but it is much more frequent in the lower portion of the small bowels. From a few inches to a foot or more of the bowel may thus become slipped into itself, and it may be found at more than one point.

From the constriction which must necessarily attend such a displacement, congestion with hæmorrhage may result, or peritoneal inflammation, gangrene, and death, with symptoms of mechanical obstruction. In some rare cases, the inner or invaginated portion of the bowel sloughs off, adhesion takes place at the point of commencement of the intussusception, and the patient recovers.

This form of displacement may be found in both children

* See No. 1506, College Museum.

and adults, where the appearance of the parts are such as to render it apparent that it had not been a source of trouble during life.

Rupture of the intestines may result from severe injury by blows, or from a crushing force applied to the abdominal walls.

Penetrating wounds of the bowels may be followed by escape of the intestinal contents into the peritoneal cavity, acute peritonitis, and death. If the bowel be empty at the time, adhesions may form between the adjoining parts, the wound thus closed, and recovery follow.

Prolapsus of the rectum consists in a protrusion of the mucous membrane or entire walls from the anus. The only post-mortem change that may be detected is a relaxed condition of the coats of the bowel, with congestion of the mucous membrane.

Diseases of the Anus. These include *ulcer and fissure* of the *anus*, *fistula in ano*, and *hæmorrhoids.*

Ulcer, and fissure of the anus, usually accompany each other, though either may exist alone. The ulcer, when present, is found just within the anus, while the fissure extends from this across the edge of the sphincter. While these affections are trifling in their post-mortem appearance, they are of great importance from the local trouble and constitutional irritation which they may produce during life.

Fistula in ano, consists in the presence of a false passage along side the rectum, usually the result of a small abscess in the ischio-rectal fossa. It is said to be *complete* when it opens at one end into the bowel, and at the other through the integument near the anus; and *incomplete*, when it has but one opening, whether that be on the surface or in the rectum.

Hæmorrhoids will be noticed under the head of

Morbid Growths.

Cancer, in its various forms, may be found in connection with the intestines, where it is usually primary in its origin. The scirrhus form is more frequently met with in the rectum, and is likely to involve the whole circumference of the passage. From the tendency which this form has to contract the parts, stricture of the rectum is likely to result, which may become a source of great suffering, and finally of death. Other forms of cancer may be found in any portion of the intestines; the colon and rectum, however, being their more frequent location.

Cancer of the intestines is very liable to extend to the surrounding tissues and organs, and in many cases, perforations of the bowel, or fistulous communications between the rectum and bladder in the male, or uterus or vagina in the female, may result.

Tubercles, generally of the miliary form, may be found within the coats of the intestines, principally confined to the peritoneal covering however. They may occasionally be found in the mucous coat, and in the walls of follicular ulcers of that membrane.

Tumors of various kinds may be found in connection with the intestine.

Fatty tumors may originate within the mucous membrane, and project as polypoid growths into the cavity of the bowel; or they may commence in the appendices epiploicæ, and degenerate into a cystic tumor with fluid contents, or become infiltrated with calcareous matter; or the pedicle may become atrophied and the tumor detached, and found free in the peritoneal cavity.

Adenoid tumors may result from hypertrophy of the several forms of glands of the intestines, and appear as soft,

rounded, and perhaps pedunculated tumors, which are liable to become ulcerated.

Fibroid tumors of small size and polypoid form, may be found in any part of the intestines, and are generally considered as a result of chronic inflammation.

Hæmorrhoids or piles, consist in a dilatation of the veins of the lower portion of the rectum, with a thickening of their walls, and increase of surrounding fibrous tissue. They may be internal or external. The contained blood may coagulate forming a thrombus. The walls may rupture, giving rise to hæmorrhages, or become inflamed and suppurate.

Abnormal contents. The normal contents of the bowels may be found mixed with the various products of inflammation, including mucus, serum, blood and pus.

Biliary calculi and foreign bodies of various kinds, may be found, which may have produced no effects, or they may have served as nuclei, around which the salts of lime, bile, mucus, fæcal matter, etc., may have accumulated, producing intestinal concretions.

Parasites. The intestinal canal is infested by several forms of entozoa, among which may be found the following:

Ascaris lumbricoides; the common round worm, six to ten inches in length. It may be single or in large numbers.

Oxyuris vermicularis; a small white worm, measuring from two to four lines in length, and found only in the large intestines, and mainly in the lower part of the rectum, where they may be present in large numbers.

Trichina spiralis. This parasite is found in the small intestine, and only in its adult form. It measures from less than a line, to two lines in length. The embryos penetrate the walls of the intestine, and finally locate in the muscles, where they remain encapsulated. If a portion of this muscle is eaten by another animal, the larvæ again become active,

and acquiring the mature sexual form, reproduce, the young embryos again migrating to the muscles.

Tricocephalus dispar. Found only in the head of the colon, and measures one and a-half to two inches in length; neck long, and body of male covered with wart-like appendages on one side.

Distoma lanceolatum. Flat, lancet-shaped, and transparent, a-half inch long, one-quarter wide. Rarely found in upper portion of small intestines, natural habitat appearing to be in the bile passages.

Of tapeworms, the following varieties may be found:

Tænia solium. Head about the size of a pin-head, and furnished with sucking disk and double row of hooks; neck long and narrow; body flat and jointed, each segment about a-half inch in length; body may be from ten to fifty or more feet in length.

Tænia mediocanellata. Head truncated and destitute of hooks; body jointed and of great length.

Tænia flavopuncta. Very rare. Yellow spot at the middle of each joint.

Bothriocephalus latus, (broad tapeworm.) Head long, unarmed; neck inconspicuous; body composed of about two thousand joints; mature joints broader than long.

Section IV. THE PANCREAS.

[**Notice** in examination:—1. *External characters*—malformations; position; size; form; adhesions. 2. *Substance*—color; consistence; wounds; abscess; tubercular deposits; cancer; cysts. 3. *Ducts*—calibre; contents; pus or blood, etc.]

Anomalies of the pancreas are not common. It is wanting only in very imperfect monstrosities. Excess of development is very rare.

Sometimes the duct is double, up to the point of its entrance into the duodenum.

Hypertrophy and Atrophy. The former, when it does occur, which is rarely the case, affects chiefly the cellular tissue which is interwoven with the glandular tissue.

Atrophy often occurs spontaneously in old age, or it may result from chronic inflammation or fatty degeneration. The organ may be soft, or of a leathery consistence.

Inflammation. The acute form rarely occurs, and is marked by the same signs of inflammation as are observed in inflammation of similar organs.

"Chronic inflammation induces condensation, induration of the cellular tissue, obliteration of the acini, and either permanent enlargement, or subsequent atrophy of the gland."

Fatty Degeneration is of frequent occurrence in drunkards, associated with fatty liver, but due to the intrusion of the surrounding adipose tissue on the wasting organ.

Dilatation of the ducts of the pancreas occurs from an obstruction of its outlets by pressure of a tumor, or by the presence of calcareous concretions. The dilatation may be uniform or saculated, forming cysts which may attain a considerable size.

Cancer, only in the forms of scirrhus and encephaloid, affects generally the head of the pancreas. It may occur primarily or secondarily. The ductus choledochus is frequently obstructed by the pressure of the tumor, and jaundice produced. The disease may extend to the duodenum, the omentum, the mesentery, liver, and even the suprarenal capsules and kidneys. As secondary cancer, it is most frequently an extension from a scirrhus pylorus.

Section V. THE SPLEEN.

[**Notice** in examination: 1. *External characters*—color, size, weight, form, adhesions; surface smooth or rough; capsule thickened, etc. 2. *Substance*—color; consistence; wounds; rupture; abscesses; tubercle; cancer; degenerations; tumors, etc.]

Congenital Anomalies. In acephalous monsters the spleen is generally absent. Occasionally in subjects otherwise well developed, it is wanting, together with the stomach or the fundus of the stomach.

Congenital displacements have been met with.

Supernumerary spleens, varying in number and small in size, are frequently met with.

Hypertrophy and Atrophy. Probably no organ of the body is as liable to such great variations in size as the spleen. The normal spleen in the adult, in whom it attains its greatest size, is usually about five inches in length, three to four in breadth, and an inch or an inch and a-half in thickness, and weighs about seven ounces. Its size is increased during and after digestion, and varies considerably according to the state of nutrition of the body. In typhus the spleen is enlarged, the parenchyma exceedingly soft, its color a dirty red, of different shades. In leukæmia it is also found greatly enlarged, but of a denser consistence. Rokitansky states that the spleen not unfrequently measures sixteen inches in length, seven in breadth, and four inches in thickness, and its weight may amount to twelve or fourteen pounds, or, according to others, to twenty or even forty pounds. (Huschke.)

Most of the hypertrophies of the spleen are accompanied not only by an engorgement of the very numerous vessels, but by an alteration and increase of the red, pulpy parenchyma.

Atrophy may reduce the spleen to the size of a hen's egg or a walnut. It takes place normally in advanced age.

Displacements. Some of these are congenital: thus it has been found by the side of the bladder; in the right side of the thorax; in the left thoracic cavity when the diaphragm was absent; and external to the abdomen in large umbilical herniæ, or where the abdominal walls had not closed.

Other displacements are the result of disease. The enlargement or distension of adjacent parts, or increase in its own size with laxity of its ligaments, causes it frequently to be displaced, and even to descend into the pelvis.

Rupture occasionally happens as the result of injuries. Spontaneous rupture in intense congestions during typhus, cholera, and the cold stage of ague, has occurred. This always proves fatal.

Inflammation. *Primary* inflammation of the spleen is comparatively rare. Unless it ends in resolution, it gives rise to the formation of laudable pus or fibrin, which may either be contained in a circumscribed abscess, and thence become obsolete, or the cavity may enlarge until the pus penetrates into the left thoracic cavity, the stomach, the transverse colon, or the peritoneum.

Secondary splenitis is regarded as identical with pyæmic deposits. The deposits are well defined, always at the periphery, cuneiform in shape, the apex directed inwards. Their color is darker than the surrounding tissue, and their consistence firmer. They are either converted into a cellulo-fibrous callus, which contracts and causes a cicatrix in the surface; or "into a puriform, creamy mass; or into a sanious greenish, greenish-brown, or chocolate-colored pulp." There are also fibrinous deposits frequently found in the parenchyma of the spleen, classed by some among the phenomena of secondary splenitis, but regarded by others as a simple exudation of fibrin, from an excess of this in the blood.

These deposits appear as a circumscribed yellowish mass, with a margin of darker or lighter red congestion of increased consistence, easily recognized when handling the part, "and showing under the microscope a confused mass of granular with more or less oily matter infiltrated among the remains of the parenchyma. They very commonly undergo fatty degeneration."

Chronic Thickening of the Capsule of the spleen is of frequent occurrence. It seems to take place at the expense of the parenchyma of the organ, and may proceed to a very great extent. It is usually pretty uniform. Ossification of the thickened fibroid layers is rare, except in old persons.

Amyloid Degeneration of the Spleen. The disease may be limited to the Malpighian corpuscles, constituting the so-called "sago spleen," or it may extend and implicate the pulpy parenchyma between the corpuscles.

The sago spleen is more or less enlarged; its weight and density are increased. On section, the surface appears smooth, dry, and studded with glistening sago-like bodies, varying in size. An iodine solution gives them a reddish-brown color.

In the more advanced stage, where the pulp is infiltrated with the new material, the organ generally is much larger than in the sago spleen. It is hard and firm; the capsule tense and transparent. The cut surface is dry, homogeneous, translucent, bloodless, of a uniform dark, reddish-brown color. The organ can be cut like wax. The corpuscles are obscured by the surrounding pulp.

Morbid Growths.

Tuberculous matter is commonly deposited in the spleen, only in connection with general tuberculosis. It appears in

the form of gray granulations, miliary crude tubercles, or yellowish cheesy masses of various sizes.

Cysts have been observed in the capsule of the spleen. They are small, of conical shape, and lightish red color, containing numerous granular cells, floating in a transparent liquid.

Hydatid cysts may be found in the spleen alone, or at the same time with one in the liver.

Cancer is rare. The encephaloid is the only form met with, and generally only with similar disease in the liver, stomach or omentum.

Section VI. OF THE LIVER.

[**Notice**: 1. *External characters*—relation to other organs and extent uncovered by cartilages of ribs; *adhesions*—their extent, position, firmness, etc. 2. *After removal*—weight; measurements; form; color; puckerings; rough or smooth; granulations; tubercles; cysts, etc. *Capsule*—thickness, transparency; facility of removal; appearance of liver substance beneath. 3. *Internal structure*—appearance of cut and fractured surfaces; fluids expressible; appearance of lobules; abscesses; fistulæ; calcareous deposits; tubercles; growths; cysts; wounds; rupture, etc. 4. *Gall-bladder*—absent; size; shape; adhesions. *Cavity*—obliterated. *Contents*—bile; quantity, color, consistence; mucus; pus, etc. *Gall-stones*—number, size, form, color, internal character. *Walls*—thickness; deposits; adipose or calcareous; abscess; tubercle; cancer; wounds; rupture. *Ducts*—calibre; dilated or contracted; impervious; from what cause? contents; condition of walls and mucous membrane.]

The liver, in its *normal state* in the adult, will measure from ten to twelve inches in its transverse diameter, from six to seven in breadth at its widest part, and about three inches thick at the posterior border of the right lobe; its weight being from three to four pounds. The gland is much larger in infants in proportion to the size of the body. In the adult, the average weight of the liver is but one-fortieth of that of the entire body, while in infancy, it may be as much as one-thirtieth or even one-twentieth.

The natural color of the liver may be described as a reddish-brown or mahogany color, yet the *shade* may vary to a considerable degree in different cases.

In studying the *morbid anatomy* of this organ, we shall notice *first*, changes peculiar to the liver itself, and *secondly*, those connected with the gall-bladder and gall-ducts.

1. Diseases of the Liver.

Congestion. From the large size and extensive distribution of vessels through the liver, this gland is capable of containing a large amount of blood, and in cases of retarded circulation in other parts, as in the recession of blood from the cutaneous vessels in a chill, the vessels of the liver may become greatly distended, constituting what is known as *congestion*. Although the gland is closely invested with the capsule of Glisson, yet, the elasticity of this membrane will admit of considerable distension, and hence the great enlargement attending this condition of the gland. Congestion of the liver may be partial, confined to one or more lobes; or general, involving the whole gland. It may also be *active* or *passive*.

Active congestion of the liver may result from blows or injuries over the region of the gland, from suppression of hæmorrhoid discharges, or suppression of the menses in the female. It will then be found presenting a deep red color, may be greatly increased in size, is more firm, and before opening the body, may be frequently felt below the margin of the ribs on the right side.

One of the most frequent causes of *passive congestion* of the liver, is organic disease of the heart, accompanied with obstruction in the circulation through the lungs, giving rise thus to difficulty in emptying of the right side of the heart, and of the venous system generally. A chronic form of congestion of the liver may result from emphysema

of the lungs, large pleuritic effusions, or tumors within the chest, and is frequently found in persons of sedentary habits who have been "high livers," or in those who have used large quantities of alcoholic or fermented liquors, or in the residents of hot climates or malarial districts.

Temporary congestion of the liver, although very extreme, does not result in structural change; but when arising from a permanent cause, as disease of the heart, etc., it produces the following effects:—"The distended capillaries of the portal-hepatic plexus press on the intervening cells; these become in part atrophied or stunted; in extreme cases almost destroyed; in part they are gorged with yellow matter to such a degree that they appear as opaque masses. The quantity of yellow matter thus formed is far greater than any that exists in a healthy state of the organ, and as some of it is doubtless absorbed and carried into the blood, we find in this circumstance some explanation of the icteric hue which is so often observed in such patients. Whether long continued congestion produces still further changes is not yet made out clearly."*

Extreme congestion of the liver may sometimes result in

Hæmorrhagic Effusion, the blood being either poured out near the surface, and dissecting up the capsule, or more deeply in the substance of the gland; or, rupturing the capsule, it may escape into the peritoneal cavity. Such effusions may be found in new-born children after protracted and difficult labors, or as a result of external violence, and sometimes attend malignant fevers, scurvy, and purpura.

Perihepatitis. The peritoneal covering of the liver, very frequently in post-mortem examinations, presents appearances of having been attacked by inflammation, in

* Jones and Sieveking's Pathological Anatomy.

the presence of bands of adhesion connecting different portions of the surface of the gland to adjoining organs. The whole of the upper surface will sometimes be found closely united in this manner, to the diaphragm. Such appearances are sure indications of the existence at one time, of an attack of peritoneal inflammation. In a cirrhosed condition of the gland, and over the seat of abscesses of the liver, such adhesions almost universally form.

Inflammation of the peritoneal covering of the *under surface* of the liver, may result from an extension of the disease from an inflamed stomach or duodenum, or from the presence of a biliary calculus impacted in some of the ducts; such inflammation resulting in more or less extensive adhesion of the parts in contact. The presence of hydatid or cancerous masses, are not usually attended with these evidences of inflammation.

Scar-like Marks, are not uncommonly found on the surface of the liver. The peritoneum at these points seems drawn into the substance of the gland, at the centre of the mark, while radiating ridges extend in various directions, to the distance of a-half to three-fourths of an inch. The cause of these appearances is evidently inflammation of the peritoneum, extending to the subserous tissue, and perhaps to the liver substance.

Hepatitis. Inflammation of the liver may be *acute* or *chronic.*

Acute inflammation of the liver, though a frequent occurrence in hot climates, is seldom met with in cold or temperate. The gland in this condition, is found more or less swollen and enlarged, and the tissues somewhat softened. This condition may be confined to one or more lobes, or involve the whole gland. Where a section is made, the turgid swollen tissue rises above the peritoneal covering,

along the edges of the incision. As the disease advances to a later stage, the deep red color changes to a brownish or grayish-red, patches of these being mingled with others of a yellowish-red or pale yellow.

Acute inflammation of the liver may terminate in resolution, when there will be a gradual restoration to a normal condition, or in suppuration, and the formation of an *abscess;* the latter result being much more common.

Abscess of the liver may involve the greater portion of the right or left lobe. The substance of the gland immediately around the abscess, will appear unusually red, and perhaps a little hardened, while other portions may present the appearance of health. In some instances, from a complete destruction of the hepatic tissue, the peritoneal covering will form the only protection to the contained matter. The quantity of purulent matter contained in these abscesses may vary from half a pint or less, to one or two quarts.

The inflammation attending the formation of an hepatic abscess, will usually extend to the peritoneum, resulting in the formation of adhesions to the adjoining organs, and thus preventing the abscess, in many instances, from discharging into the peritoneal cavity, as it otherwise would be likely to do. Abscesses thus formed, may discharge: 1st, by the adhesive process through the diaphragm into the chest, and if adhesions had previously taken place between the diaphragm and lung, by an extension of the ulcerative process, the matter may find its way into the bronchial tubes, and thus be discharged by expectoration; 2d, by a similar process into the stomach, duodenum or colon; 3d, upon the surface of the body; and 4th, within the peritoneal cavity. In the latter case, death is inevitable; in the others recovery is possible. The following case illustrates discharge and recovery by the first method:

CASE.—*Abscess of the Left Lobe of the Liver, discharging through the diaphragm, a portion of the matter expectorated, the balance discharged upon the surface of the body—Recovery.*

In the winter of 1856-7, I was called to see Mrs. B——, aged 40, of Broad street. She had been given up by the physicians previously in attendance. Found her greatly emaciated, suffering from a terrible cough, and expectorating great quantities of excessively offensive matter. Diarrhœa, hectic fever, night sweats, with occasional chills, completed the picture, and appeared to render the case perfectly hopeless. Upon inquiry, learned that she had been taken ill some months previously, with what the attending physician had pronounced as acute hepatitis. After the usual acute symptoms, the formation of an abscess became evident from the fulness in the region of the left lobe, accompanied with chills, hectic, etc. A violent cough, with evidences of inflammation in the left lung, accompanying the other symptoms, the case was supposed to be complicated with tuberculosis. The expectoration finally became greenish, thick and exceedingly offensive, indicating that the abscess had worked its way into the bronchial tubes. In examining the chest, after the case had been under my care a few days, I noticed between the ninth and tenth ribs a fulness and slight redness. After the application of poultices for a few days, a distinct "pointing" appeared, from which, after the use of the lance, came a most copious discharge of the same green, offensive matter, as was being discharged by expectoration. From this time, a slight improvement was noticed in the patient. The external opening was carefully kept from closing. The cough gradually improved. Little or none of the offensive matter was raised after the establishment of the external opening. In six months the health was fully restored, and now, fifteen years after, she is a stout, healthy woman.

In the progress of formation of an abscess in the liver, as branches of the portal or hepatic veins are reached, inflammation of their coats is excited, which results in their obliteration, thus generally preventing the admission of pus into the venous system. But as the enlarging abscess encroaches upon the hepatic ducts, instead of these becoming closed by inflammation, they ulcerate through, and thus establish a communication between these vessels and the cavity of the abscess. Hence the pus contained in these abscesses, is very likely to be mingled with more or less bile; while at

the same time, a portion of the contents may be discharged through the common duct into the bowels.

Abscess of the liver may result from inflammation and ulceration of the bile ducts, from the irritation of impacted calculi, or from the presence of intestinal worms that have entered by the ductus communis; or from the lodgment of emboli in some branch of the portal vein or hepatic artery.

Secondary, Pyæmic or Metastatic Abscess. The liver is occasionally the seat of abscesses forming as a result of *pyæmia*, induced by absorption of pus from some wound of a joint, vein, or bone; or from a diffused abscess or erysipelas of the skin. These abscesses usually contain a somewhat thin and oily-looking pus. They also differ from ordinary abscesses in the rapidity with which they form, a few days generally sufficing to give them a large size. The insidious manner in which they form—the tissues breaking down, as it were, without any inflammation—constitutes a distinguishing feature of these collections. Pyæmic abscesses of the liver are usually many in number, and varying in size from a pea to that of a walnut. The gland is usually enlarged at the same time, and in some cases to such an extent as to reach quite to the umbilicus. This form of abscess is not confined to the liver, but may be found in the lungs, spleen, in the joints, or in the serous cavities, and sometimes diffused through the connective tissues and muscles of the limbs or trunk.

Degenerations of the Liver.

Waxy, Lardaceous, or Amaloyd Liver. In this form of disease, the liver undergoes greater enlargement than in any other disease excepting cancer. The enlargement is uniform in every direction, so that the form of the gland is unchanged. Pain and tenderness are never promi-

nent symptoms of this disease, hence the liver may be manipulated during life with impunity, the patient complaining only of weight and tightness in the right hypochondrium.

The progress of the disease is usually slow, extending, in most cases, over several years. The spleen, kidneys and intestines will frequently be found presenting this change at the same time.

The tissue of the gland in these cases is very firm, so that the organ generally retains its form when laid with its convex surface on the table. The external surface is smooth and free from adhesions. When cut, a peculiar translucent substance is found infiltrated through the tissues, giving it a firm, glistening appearance, known as waxy, lardaceous, amaloyd, albuminous, or sometimes scrofulous liver. This substance is stained a deep red by the action of a weak solution of iodine.

The change appears to commence first, in the small blood-vessels, finally extending to the lobules, appearing first in the centre, and ultimately involving the whole lobule.

The disease is more common in males than females, and is frequently caused by constitutional syphilis. In some instances, it would appear to be produced by a tubercular diathesis, and co-exists with some local form of scrofulous disease, or by a long exposure to malarial influences.

Fatty Liver. This form of disease we find in drunkards; in persons who have been large eaters and sedentary in habit; in several wasting diseases, as in chronic diarrhœa, and especially in phthisis pulmonalis. There is a moderate degree of enlargement which affects all portions of the gland. The consistency is softer, and the resistance less than in waxy liver, giving it a doughy feel. The color varies, but is usually lighter than normal, approaching a yellow, and more or less mottled. When cut, the substance presents a deci-

dedly oily appearance, both to the feel and sight. The disease is unaccompanied with pain from first to last; neither is its function materially interfered with, hence jaundice is not usually a symptom of the disease.

A microscopic examination shows the lobules of the liver filled with fat globules, which appear to have originated in the hepatic cells. The change appears to commence at the circumference of the lobule, the centre remaining normal in color, thus giving a mottled appearance to the cut surface.

Other organs are very liable to be affected at the same time by this form of disease, as the heart, kidneys, etc., the symptoms which the case presents, such as albuminous urine, tendency to dropsy, dyspnœa, etc., arising from these organs, rather than from the fatty liver.

Pigmentary Degeneration. In cases of malarial poisoning, we sometimes find the liver with other organs of the body, as the spleen, lungs, brain, kidneys, etc., presenting a peculiar dark color, the result of the presence of a black or brown pigment in the blood, filling the vessels of these organs. The pigment appears to be formed of small granules either free or contained in irregular cells. In the liver, this pigment is found most abundant in the blood of the portal vein, but may be present in the hepatic artery, and in all the venous capillaries.

The liver may be normal in size, or it may be atrophied or hypertrophied, or may have undergone fatty or waxy degenerations.

Granular Degeneration. A peculiar change in the liver substance is sometimes found after death from various acute or infectious diseases, as the exanthemata, pyæmia, septicæmia, erysipelas, typhus, typhoid, and yellow fever, etc.; or from thrombosis of the portal vein, abscesses or

cirrhosis, as well as in poisoning by arsenic, phosphorus or antimony.

The change in the early stage consists in an accumulation in the liver cells, of a fine granular substance, soluble in alkalies, and apparently of an albuminous nature; and, at a later stage, of coarser shining particles of a fatty character, and soluble in æther or alcohol.

Atrophy of the liver may be divided into the following forms:

I. Simple Atrophy.
II. Acute or Yellow Atrophy.
III. Chronic Atrophy, or Cirrhosis.

Simple Atrophy. By this, we understand a diminution in the size of the liver, without any alteration in its structure. In this state, the liver may be reduced to one-half its normal weight and bulk. It is found to occur:

1. *Old age.* Hence this form of atrophy is sometimes called "*senile atrophy.*" With the loss of adipose tissue in advancing years, there is also a tendency either to *degeneration* or *wasting* (atrophy) of many of the organs, and especially of the liver. In this manner, the liver may be reduced to one-half its normal size and weight without any change of structure.

2. *Inanition*, arising either from an insufficient supply of food, or from diseases which interfere with the assimilation of food, may result in simple atrophy of the liver.

3. *External pressure* may also produce the same result, as from tight lacing, pleuritic, pericardial, or peritoneal effusions, or from enlargement of organs, or presence of tumors near the liver.

Simple atrophy is rarely attended with jaundice unless pressure upon the bile ducts has been such as to obstruct the flow of that fluid.

Acute, or Yellow Atrophy. In this somewhat rare form of disease, the liver becomes rapidly atrophied, accompanied with jaundice and cerebral symptoms. After death, the organ is found greatly reduced in size, extremely soft and yellow, with no appearance of lobules, and upon microscopic examination, the secreting cells found more or less changed into granular matter and oil globules. The weight of the gland in these cases, may be reduced from three to four pounds, the average normal weight, to less than two pounds.

This form of disease is frequently attended with hæmorrhages, particularly of the stomach and bowels, and in some instances, from the uterus or nose.

Pregnant females suffering from this affection usually abort.

Among the causes of this form of disease of the liver may be mentioned pregnancy, dissipation, constitutional syphilis, malaria, and the blood-poisoning of typhus fever.

Females appear much more liable to the disease than males, and most persons attacked are under middle age.

Chronic Atrophy, Cirrhosis or Hob-nail Liver. The form of atrophy of the liver which we now have to consider, is slow in its progress, and is usually associated with abdominal dropsy. The appearance and density of the gland varies to a considerable extent in different cases of chronic atrophy, yet the usual appearance is that seen in what is known as cirrhosis,* or "hob-nail liver," also sometimes called "gin-drinker's liver." Here the liver has

* Cirrhosis, as applied to this condition of the liver, has reference to the yellow color, due to the presence of large quantities of yellow pigment contained in the secreting cells; hence the application of the term to diseases of the lungs, kidneys, etc., which resemble cirrhosis of the liver, not in color, but in density of the tissues, is obviously inappropriate.

become reduced in size, from a slow destruction of the secreting tissue, while, at the same time, the fibrous tissue of Glisson's capsule has become thickened and hardened, from a chronic inflammatory action, often due to the use of spirituous liquors. The outer surface presents a granular or nodulated character, which has given rise to the term "hob-nail," as applied to this disease; while, upon section, the interior presents firm fibrous bands, surrounding yellow patches of secreting tissue. While, in the majority of cases, this disease is plainly owing to an abuse of spirituous liquors, in others, it is found associated with disease of the heart, or with constitutional syphilis, where the patient has been strictly temperate.

The increased density, in connection with the diminution of size, and granulated character of the surface, renders the disease readily recognizable in a post-mortem examination.

The early stage of this disease appears to be accompanied with a degree of enlargement of the gland, resulting from the congestion attending the inflammation of the fibrous structure. As this structure increases in density, by pressure it causes a gradual absorption of the secreting lobules, and thus results in a reduction in the size and weight of the organ.

The secreting cells of the lobules of the liver, may undergo fatty change, or they may become entirely destroyed. Thrombi may be found in the portal vein. The hepatic artery and its branches become increased in size, while the interlobular hepatic veins become quite destroyed. The obstruction to the circulation through the liver, resulting from these changes, gives rise to the dropsical effusions usually found in this disease.

Prominent among the symptoms attending this disease, during life, may be mentioned:—1st. Diminished area of hepatic dulness. 2d. Ascites, particularly in advanced stages of the disease, although patients may die before

dropsy sets in. 3d. Enlargement of the spleen—this being present at least in about one-half the cases. 4th. Enlargements of the superficial veins of the abdomen, from obstructed flow of the portal blood, or from pressure upon the vena cava, from abdominal distension. 5th. Hæmorrhoids, epistaxis, hæmatemesis, etc. 6th. The rare occurrence of decided jaundice. 7th. In all cases, the advance of the disease is marked by progressive emaciation and debility, the patient usually dying of exhaustion, although in some cases death is due to an attack of pneumonia, œdema of the lungs, or acute peritonitis.

Hypertrophy. We sometimes find an evident increase in the size of the liver, without any alteration of structure, or the presence of any prominent symptoms. Such cases may be considered as instances of *simple hypertrophy.* This condition has been observed in cases of leukæmia, and in some exceptional cases of saccharine diabetes, heart disease and phthisis.

Morbid Growths.

Cancer of the Liver. Every variety of cancer may be found in the liver, though the scirrhus or medullary forms are more common. The disease is invariably accompanied with enlargement, and in some instances the increase is enormous. The progress of the disease is rapid, a few weeks in many instances, a few months at the longest, being required to fully develop the disease. The enlargement is not uniform. The surface becomes irregular and uneven, nodules of various size are found projecting from its surface and borders, which are usually harder than those of the surrounding portions. The disease is nearly always accompanied with pain, and considerable tenderness is felt upon touch.

Jaundice is present in many cases, but in ninety-one cases collected by Frerichs, fifty-two showed no symptoms of jaundice. Abdominal dropsy to any considerable extent, rarely attends the disease, although usually a small quantity of fluid will be found in the peritoneal cavity. These characters will usually enable us to make a correct diagnosis of these cases during life.

The post-mortem examination, discloses, in the majority of cases, a greater or less number of irregular, rounded masses, projecting from the surface of the liver, and varying in size from a kernel of corn to an orange. Through the peritoneum, these bodies present a light, straw-colored appearance, and when divided, the interior is found of a whitish-gray color, and of the consistence of tallow or cheese. Examined very carefully, the substance has the appearance of infinitely minute granules, aggregated together.

These masses may be confined to one of the lobes, or involve the whole organ; they are of an irregularly rounded or globular form, and in some cases two or three appear to have coalesced into one mass.

In other, and more rare cases, the cancerous matter, instead of being collected in masses, is found more or less infiltrated through the liver substance, as in Case I.

They may soften, and form cysts filled with a thin serous fluid; or they may undergo a form of fatty degeneration.

In such cases the disease is liable to be mistaken for waxy degeneration. In both, there is a uniform hard enlargement, but in the waxy enlargement, the progress is slow, and without pain, and there is usually enlargement of the spleen, with albuminuria, and a syphilitic taint; while in cancer there is no enlargement of the spleen, or albuminuria, and the course of the disease is rapid; there is pain, cachexia, and often signs of cancer elsewhere.

Cancer of the liver, in the majority of instances, is

secondary to cancer of some other part, as of the stomach, rectum, or female breast. In more than one-third of the cases, it is said to be secondary to cancer of the stomach.

Cases are rare where the liver is primarily affected with cancer. Before thirty-five or forty years of age, secondary cancer seldom occurs.

The following cases will serve to illustrate the two forms of cancer of the liver:

CASE I.—*Primary Cancer of the Liver, with great enlargement—Rupture of Stomach from post-mortem softening.*

Mrs. K——, aged 38, light complexion, short and fleshy, commenced complaining about New Year's, 1868, of pain in the "stomach," as she expressed it, with loss of appetite, restlessness at night, accompanied with weakness and prostration. These symptoms continued for a couple of weeks, when she commenced to complain of soreness in stooping, and inability to wear her clothes tight. This led to an inspection of the abdomen in bed. I then found projecting below the margin of the chest on the right side, a hard rounded tumor, nearly of the size of the fist, somewhat sensitive to the touch, and evidently springing from the liver. The pain daily increased in severity, and coming on as it did, in paroxysms, resembled much the pain attending the passage of biliary calculi.

After she took to her bed, which was in the latter part of January, there was a rapid increase in the size of the liver, with a marked aggravation of all the symptoms. The pain was most agonizing; slight chills occurred from day to day; the flesh rapidly wasted, and the outline of the lower border of the liver could be distinctly traced through the abdominal walls. There were no symptoms of jaundice. The skin was pale and waxen in hue. In the latter part of February, frequent epistaxis, and bleeding of the gums set in, while from the pressure upwards upon the diaphragm, the lungs were so embarrassed as to give rise to great dyspnœa. Rapidly sinking, she died on the first of March.

Autopsy, made thirteen hours after death. Anterior portion of the body pale; posterior dark from gravitation of the blood. Rigor mortis scarcely noticeable. Upon opening the abdomen, found four to six ounces of serum in the peritoneal cavity.

The liver was enormously enlarged, filling a great portion of the abdominal cavity, pushing the diaphragm high up into the chest, and

giving the lungs less than half their normal amount of room for expansion. The upper surface of the right lobe was found adhered to the under surface of the diaphragm, and to the anterior abdominal walls, and the under surface to the stomach, duodenum and transverse colon.

The surface of the liver was dark, mottled, and somewhat nodulated. The whole gland was quite firm, yet evidently just entering upon a softened stage at numerous points. No trace of an abscess forming at any point.

Upon lifting the left lobe of the liver, a dark, brownish fluid appeared behind the stomach, the origin of which was not at first apparent. The removal of the liver, however, completely exposing the stomach, showed the posterior wall at the large end, *softened and ruptured.* This softening was evidently a post-mortem action of the gastric juice; the rupture resulting from the tension upon the same, in tearing away the adhesions between the stomach and liver.

Upon the removal of the liver, found it to weigh eighteen pounds. The gall-bladder was empty and contracted. The only portion of the gland not involved in the disease, was one of the small lobes, the *lobus Spigelii,* and a portion of the left lobe. Incisions, showed the interior presenting a similar mottled appearance as the surface; dark, almost black spots, intermixed with spots of brown and gray. The blood-vessels of the liver were enlarged, and filled with dark defibrinated blood. No trace of coagulated blood, in any of the blood-vessels of the body.

Microscopic examination. An examination of a small portion taken from the right lobe, with a power of 350 diameters, showed innumerable cells of an irregular outline, and varying in size; oil globules, and granular matter. The action of acetic acid, rendered the nuclei of the cells faintly visible. Many cells of a large size were found filled with a growth of smaller ones. All other organs of the body normal.*

CASE II.—*Cancer of the Liver, secondary to Cancer of the Rectum, with diffused Abscess in the Neck.*

Mr. A——, of Doylestown, Pa., aged 60, had been suffering for some months with symptoms of disease of the rectum, with also inflammation of the bladder. His passages were painful, and accompanied with more or less bloody, purulent matter. His urine was thick, at first from presence of large quantities of mucus, later of pus. His appetite and digestion were poor; his color pale and cachectic.

Some six months previous to death, he commenced passing with his

* See No. 1495, College Museum.

urine, small quantities of seeds of berries, tomatoes, etc. These gradually increased in quantity, until, for some weeks previous to death, there was a free discharge of feculent matter from the bladder, and at the same time much urine passed per rectum. A few days before death, there appeared a diffused swelling upon the front of the neck, extending from the clavicles as high as the upper portion of the larynx. There was no discoloration of the surface. The swelling presented a boggy feel, without any positive fluctuation.

On the 15th of July, 1871, I was called by Dr. George Wright, who had been treating the case for the past year, and from whom I learned the above facts, to make a post-mortem examination, the patient having died the day before.

Found the body very thin, surface pale. No serum in the peritoneal cavity. Upon lifting the small intestines from the cavity of the pelvis, found the rectum closely adhered to the posterior surface of the bladder, completely obliterating the recto-vesical *cul-de-sac*. Considerable dense scirrhus matter, was found upon either side of the rectum and bladder.

Upon removing the rectum and bladder, a large opening (one inch in diameter) was found communicating between the two. The edges of this opening were thick and ragged. The walls of the bladder and rectum generally, were thick and hard from scirrhus deposits. The bladder contained considerable purulent and feculent matter, with also a cherry-stone. Upon examining the liver, found upon the under side of the left lobe, a large cancerous mass, imbedded in the substance, but projecting from the surface, and quite as large as a goose egg. Other portions of the liver healthy.*

The lungs were healthy. The muscular walls of the heart were pale and soft, while each of the cavities contained soft, imperfectly formed fibrinous clots.

The right pleural cavity contained nearly a pint of serum, while the pleura presented a red, inflamed appearance.

In removing the sternum from its position, noticed purulent matter beneath the upper end, which appeared to come down from the neck. Upon carrying an incision upwards to the hyoid bone, found the whole region of the neck infiltrated with pus, without being confined by any limiting membrane or sac, and evidently metastatic in its origin.

Tubercles. The peritoneum covering the liver, like other portions of this membrane, will sometimes (more

* See No. 1496½, College Museum.

frequently with children) be found filled with numerous minute tubercular particles, the presence of which are liable to give rise to appearances of inflammation, such as redness, roughness, and perhaps adhesions.

Fibroid and Cartilaginous Tumors are of extreme rarity in the liver. When present, they exhibit the characters of those growths in other parts.

Adenoid Tumors have been detected in this gland. They vary in size and number, but are usually enclosed in a fibrous capsule, and appear to be made up of glandular cells, resembling the hepatic cells, but of larger size and greater density.

Vascular Tumors are sometimes found in the liver, consisting apparently of a compact, irregular network of dilated veins, held together by connective tissues. Of a dark, almost black color, they vary in size from a few lines to two or three inches in diameter, and are very irregular in their outline.

Cysts of small size are occasionally found, developed either in the connective tissues, or from a dilatation of bile ducts. They may be found filled with serum, or colored mucus and epithelial cells.

Syphilitic Tumors, from the size of a pin's head to that of the fist, may be found in the liver. They are of a gray, whitish or yellow color, made up of cells of an irregular form, which show a tendency to cheesy degeneration, or to such softening as to give the appearance of an abscess.

Blood-vessels of the Liver.

The hepatic artery is sometimes found with aneurismal enlargements, and rarely contains an embolus.

The portal vein is frequently found containing a fibrinous clot, constituting thrombosis. Such clots may result from pressure on the vein from the presence of some morbid growth in the liver, or from a tumor in the mesentery or some other part, obstructing the portal vein below the liver; or from suppurative disease or ulceration of the several organs from which the portal vein arises. They may be a cause, or result, of phlebitis, and may give rise to jaundice, and sometimes to abscess of the liver.

Dilatation of the portal vein may result from obstruction of the capillaries of the liver in chronic atrophy or cirrhosis; or from the presence of thrombi, or pressure by various morbid growths.

Calcification, not only of the portal vein within the liver, but of its various branches of origin within the mesentery, omentum, etc., may occasionally be met with.*

The hepatic veins may be found presenting the same abnormal conditions as the portal vessels.

Animal Parasites.

The liver has long been known as a favorite resort for different parasitical animals, the most common of which, is that of the larval form of one of the tapeworms—*the Tænia echinococus*—constituting when developed in the liver, what is known as an *acephalocyst* or *hydatid.*

Hydatid Tumors of the liver, arise in the following manner:—The several tapeworms pass through three stages of development, these never being completed however in the same animal. The Tænia echinococus, acquires its adult

* See report of case of "Ossification of Veins," by James Kitchen, M. D., in American Journal of Homœopathic Materia Medica for December, 1871, page 143.

form, only in the intestines of the dog or wolf. The mature segments, each of which are filled with vast numbers of eggs, are voided with the fæces, into which the eggs are discharged. These soon develop into a minute embryo, with one extremity provided with numerous little hooks. If taken into the stomach of an herbivorous animal or man, this embryo pierces the walls of the intestines, enters a blood-vessel, and finally lodges in some of the tissues or organs, more frequently the liver, where it develops into a sac-like body, known as a *cysticercus* or *hydatid*, the second larval form. When the embryo is taken into the stomach of other animals, no further development takes place.

While in the hydatid, or second larval form, by a peculiar process known as alternate generation, there may be a reproduction of cysts to an almost endless extent within the parent cyst, or secondarily in other parts.

The adult or third stage of development, can only be attained within the intestinal canal of the dog or wolf. These animals devouring a sheep or other ruminant, or in some rare case perhaps a human being, within which the hydatid has been formed, the cysts thus taken into the stomach, develop into the perfect worm, from which segments containing the eggs are again discharged.

It would appear almost impossible for the embryo from these eggs, to ever enter the human stomach, but it is not difficult to understand that the fæces of the dog containing the ova, may enter a spring or stream, from which the minute embryo may be taken with the water, by either man or a lower animal; or, by attaching themselves to water-cresses, etc., they may be eaten with these by the same.

Hydatid tumors of the liver, may vary, greatly, in size, according to their age. From an extremely minute cyst, they may acquire such a size as to fill and distend the abdominal cavity, crowding the several viscera from their position.

There may be one or several. They may be confined to the liver, or secondary cysts may appear in other organs.

When opened, the interior is generally filled with numerous smaller cysts of various sizes, each filled with a gelatinous fluid of varying degrees of density and color, and within which, by a careful microscopic examination, may be detected—many times, not always—numerous hooklets, which have been detached from the minute heads. The walls of the parent cyst may become greatly thickened, or even calcified. The contents may degenerate into a purulent mass, with which may be mingled blood or bile.

The development of these tumors is usually slow, and unattended with pain, or functional disturbance of the liver. After they have acquired a large size, they may induce peritonitis, resulting in extensive adhesions.

Rupture of these hydatids sometimes take place, this accident being followed by death, or recovery, according to the point at which the rupture takes place. They may burst in the following directions:

1. Through the diaphragm into the pleural cavity, or into the substance of the lungs.
2. Rarely into the pericardium.
3. Into the peritoneal cavity, resulting in acute peritonitis.
4. Through the abdominal walls, when recovery is possible.
5. Into the stomach or intestines; this being the most favorable point of rupture. In fifteen cases of rupture into the intestines, fourteen recovered.
6. Into the biliary passages or large blood-vessels.

CASE.—*Large Hydatid Tumor of the Liver—Death from Exhaustion.*

Mr. O——, of this city, aged 75 years, noticed some two years previous to his death that his abdomen was enlarging. An examination disclosed the presence of a large tumor descending from the region of

the liver. It was slightly fluctuating, and unattended with pain or soreness. He complained of nothing but weakness with vertigo. All the functions of the body were natural.

A gradual increase of size took place, with occasional attacks of inflammation, until the abdomen acquired the dimensions of that of a woman at full term. The oppression now became so great, from the crowding of the lungs, that I decided to resort to paracentisis. Some two quarts of a thick, gelatinous fluid were drawn off from the tumor, with several quarts of ascitic fluid from the peritoneal cavity. The operation was followed by great relief. Rapidly refilling, the oppression again became severe, and the operation was repeated a few months later with similar results. Death finally followed from exhaustion.

The post-mortem revealed an immense tumor, filling the abdominal cavity with extensive, firm adhesions, and crowding the lungs into the upper part of the chest. The walls of the sac were thick and semi-cartilaginous, and the interior divided into numerous compartments by septa passing in various directions. These compartments were filled with a gelatinous fluid, in which were innumerable cysts of various sizes, each filled with a similar fluid as that with which they were surrounded. The microscope showed the presence of numerous cholesterine scales in this fluid.

The weight of the entire tumor was over fifty pounds. A portion was preserved and deposited in the College Museum.*

The following parasites are also sometimes found in the human liver, or its ducts:

Distoma hepaticum, or liver fluke. Common in the bile passages of lower animals, rare in that of man. It is flat, oval, from two to four lines long, and a-half to one line broad. Its presence in the hepatic ducts, may give rise to enlargement, some degree of obstruction, or calcification.

Distoma lanceolatum. This parasite, something smaller than the above, is still more rare in the bile passages of man.

Pentastoma denticulatum. This animal is found as a small cyst, with calcified walls, and containing fatty and calcareous matter, with the remains of the dead parasite.

---

*See No. 1500, College Museum.

It is considered as the larval form of a worm sometimes found in the nasal cavity of the dog, and some other animals.

The Ascaris lumbricoides may be found in some of the bile passages, it having entered by the opening of the common duct into the intestine.

2. Affections of the Gall-bladder and Ducts.

The gall-bladder is sometimes wanting, this being the normal condition in the horse and some other animals. When thus absent, the hepatic ducts are so increased in size, as to be able to contain the accumulating bile in the intervals of digestion.

Inflammation of the gall-bladder and common duct, involving their mucous lining, is not uncommon. Such inflammation may be either *catarrhal* or *suppurative.*

Catarrhal inflammation may result in thickening or calcification of the lining membrane of the ducts and bladder, with the accumulation of such quantities of thick tenaceous mucus, as to become a source of impediment to the flow of the bile, and thus give rise to jaundice. Such inflammation becoming chronic in the common duct, may result in great dilatation of the gall-bladder, from the accumulation of bile.

In many cases, this form of inflammation would seem to have originated in the duodenum, reaching the biliary passages by extension through the opening of the duct into the intestine. It may also result from the presence of calculi or parasites in the passages, or from inflammation of the liver.

Suppurative inflammation may attend different forms of fevers, or result from the presence of calculi. The gall-bladder, with the bile ducts, in such cases, may be filled

with a purulent fluid, or the same may be found infiltrated through their walls.

Perforation of the walls of the gall-bladder may result from this form of inflammation, with escape of contents into the peritoneal cavity, inducing thus fatal peritonitis. Fistulous communication may also form between the bladder and colon, duodenum or stomach, or through the abdominal walls, adhesions having first taken place between these parts.

Dilatation, both of the bladder and ducts, may occur as a result of obstruction of the gall-ducts. That of the former may be very great, giving rise to a tumor that may be plainly felt through the abdominal walls. Dilatation of the ducts may involve either the common, or large hepatic ducts, or the smaller branches within the liver. Such dilatations may be sacculated in form, or general, involving the whole tube.

Morbid Growths.

Cancer of the walls of the gall-bladder is not unfrequent, and may be either primary or secondary. The cavity of the bladder may in this way become obliterated, and the common duct obstructed, thus inducing jaundice.

In a case examined for the Drs. Pettingill, the gall-bladder was as large as the fist, from scirrhus cancer; its cavity obliterated; adhered to the pylorus to which the disease had extended; and the bile ducts greatly dilated and filled with a large quantity of puriform fluid. The patient had been for many months extremely jaundiced.

Fibroid tumors are very rarely observed in connection with the gall-bladder.

Tubercular deposits may be found beneath its peritoneal covering.

Biliary Calculi. The presence of biliary calculi, or gall-

stones in the gall-bladder, or some of the ducts, is a very common occurrence. These bodies are composed of the elements of the bile, largely however of cholesterine, sometimes in an almost pure state, in others, more or less mixed with inspissated bile. In many cases, a nucleus of nearly pure cholesterine will be surrounded by a deposit of biliary matter mixed also with scales of cholesterine.

Cholesterine is a peculiar spermaceti, or fatty-like substance, found not only in the bile, but also in the nervous tissues, insoluble in water, but soluble in æther or boiling alcohol. When found in a pure state, it is of a yellowish-white color, with the particles arranged in the form of shining thrombic scales.

Gall-stones may occur of all sizes, from a pin's head to that of a hen's egg. When small, they are generally numerous; in some instances fifty to one hundred being found in the gall-bladder at one time. When several are present in the bladder, they will be more or less angular or polyhedral in form from contact and attrition with one another. Where there are but one or two, the size may be considerable, while the form will be rounded, oblong or pear-shaped, and more or less regular.

These bodies, when first removed, are usually heavier than water, but, after being dried, become considerably lighter. They are inflammable, and may be reduced to almost pure charcoal by burning. After having being exposed to the air for some time, they are very liable to crumble more or less completely.

Position. 1. *Gall-stones may be confined to the gall-bladder.* This is the position in which they are more frequently found. There is every reason to believe that they may remain there for a long time without giving rise to any uncomfortable symptoms. We frequently find them after death in the gall-bladder of persons who, during life, exhibited no symptons of their presence. They are liable,

however, when present, and particularly if numerous or large, to give rise to a sense of weight and dragging in the part, and to occasional attacks of pain, derangement of the stomach and vomiting; and may also excite inflammation and ulceration of the walls of the bladder.

The presence of gall-stones, when in large numbers, may frequently be detected through the abdominal walls, as a hard resisting tumor, which, by grasping, may be made to elicit a rattling sensation, like pebbles in a bag.

2. *Gall-stones may become impacted in the neck, or cystic duct of the gall-bladder.* In this case, it is likely to give rise to an attack of biliary colic, with vomiting, etc. As long as it remains in this position there will be no jaundice. Their presence, however, may excite inflammation; yet we sometimes, in post-mortem examinations, find the neck of the gall-bladder blocked up by a calculus, when no symptoms of such an obstruction existed during life.

3. *Gall-stones may form in some of the branches of the hepatic ducts within the liver.* This is not a common point for the formation of these bodies. They are sometimes found, however, in cases of obstruction of the ductus communis. The concretions may be small and rounded, or branching casts of the tubes, resembling pieces of coral.

4. *Gall-stones may be lodged in the ductus communis choledochus.* This is one of the most common situations for these bodies, and they may reach the point, either from the gall-bladder, or from the ducts from the liver. While in this position, the calculus is likely to give rise to jaundice with paroxysms of severe pain, which will be repeated from time to time, until it passes into the intestines.

Effects. As already intimated, gall-stones may remain for an indefinite period in the gall-bladder or ducts, without giving rise to any symptoms. In many instances, also, they may undoubtedly pass the ductus communis when small, and be discharged by the bowels, without the knowledge of

the patient. More frequently, however, the passage of these bodies is accompanied with paroxysms of severe pain, the location and character of which will usually serve to indicate the true cause. Where, however, the body is too large to pass, its presence in the gall-bladder or any of the gall-ducts, may excite inflammation and ulceration in those parts, and thus lead to perforation and discharge of contents into the peritoneal cavity.

CASE.—*Rupture of the Gall-bladder, with discharge of contents into the peritoneal cavity, followed by peritonitis and death.*

Mr. De K. T——, of this city, aged about 60, had suffered from several attacks of severe pain in the region of the gall-bladder, which I had diagnosed as biliary colic, induced by the presence of a calculus. One morning in June, 1863, while working in his garden, he felt a sensation of something giving away in his side, which was immediately followed by an attack of severe pain. A chill and fever soon succeeded; and, in twenty-four hours, a violent peritonitis set in, resulting in death in four days.

Autopsy, thirty-six hours after death. Upon opening the cavity of the abdomen, the peritoneal membrane was found intensely inflamed at all points, and containing nearly a quart of greenish sero-purulent fluid. Slight plastic adhesions were found at various points, uniting the intestines to the abdominal walls, while old, firm and extensive adhesions were found between the same and the liver and gall-bladder. There were evidences that the latter had been largely distended, yet, through a distinct opening, the contents had escaped into the peritoneal cavity, leaving behind a single calculus of a regular oval form, and one inch of its long diameter.*

From the appearance of the part, it would seem that the calculus had excited inflammation and ulceration in the walls of the gall-bladder, destroying the latter so completely, that the fluid contents were kept from escaping into the abdominal cavity, only by the adhesions that had formed, and that these had been probably torn away by the exercise of digging with the spade.

In many cases, the adhesions which are induced by the

*Specimen No. 1329, College Museum.

inflammation, will secure a more fortunate result, favoring the working of the calculus, by the ulcerative process, either into the duodenum or colon, and thus, in most cases, securing its passage per anum. In such instances, should an opportunity be had of examining the parts after death, traces will be found remaining, sufficient to indicate the point at which the escape into the bowel was effected.

In some rare instances, gall-stones have been vomited from the stomach. While it might be possible for such bodies to be carried from the duodenum into the stomach by a reversed peristaltic action, it is more probable that, in such cases, the calculus has found its way into the stomach by a direct fistulous communication with the gall-bladder.

Fistulous communications of a permanent character are sometimes left, after an ulcerative discharge of a gall-stone into some portion of the intestinal canal.

Gall-stones, after entering the intestinal canal, may become impacted, thus producing intestinal obstruction. Many fatal cases of this character have been reported. An interesting case of intestinal obstruction from this cause, was reported by Dr. Frieze, of Harrisburg, at the meeting of the American Institute of Homœopathy, in Philadelphia, in June, 1871. A lady sixty-five years of age, had been suffering severe pain in the bowels for over a week, with symptoms of obstruction, when, after a persevering use of injections, she passed a calculus of a cylindrical form, one and three-quarter inches in length, and four and one-half inches in circumference, and weighing four hundred and thirty-seven and one-half grains.*

Gall-stones have, in a number of cases, been discharged upon the surface of the body, while in some rarer instances, by the ulcerative process they have worked into the ureter, and even into the vena cava and portal vein.

---

* See No. 1336½, College Museum.

CHAPTER II.

THE URINARY APPARATUS.

Section I. THE KIDNEYS.

[**Notice**:—Absence of either kidney, or other abnormalities. Of each kidney, note 1. Form, size, weight, wounds, etc. 2. *Capsule*—thickness; transparency; facility of removal. 3. *Surface of kidney after removal of capsule*—color; smooth or lobulated, size of lobules; puckerings; granulations; cysts, etc. 4. *Substance of kidney*—consistence; flaccidity, etc.; fracture, granular or not? wounds, rupture. 5. *Cut surface*—color of pyramidal and cortical portions; proportion of each; amount of blood exuding from; thickness of cortical portion; color; Malpighian corpuscles; their degree of visibility, color, etc.; appearance of striæ in pyramidal portion, color, etc. 6. *Abnormal growths and deposits*—cysts; fibrinous masses; tubercle; cancer; chalky masses; abscesses, etc. 7. *Pelvis of kidney*—peculiarity of form; contents; fluid, quantity, quality, purulent, etc. *Calculi*—their size, position, etc. *Walls of pelvis*—their thickness; transparency; fistulous openings; wounds, etc. 8. *Ureters*—size, contents, etc. 9. *Microscopic examination*—make section with Valentine knife, from convex border through cortical portion, and from base to apex of cone, parallel with tubules; place on slide and examine with varying powers, from 100 to 500 diameters. *Note condition of tubules*—contents; blood, oily particles, fibrinous, waxy, epithelial or other casts; or denuded of epithelium and empty. *Malpighian tufts*—gorged, ruptured, filled with granular or oily matter, or obliterated. Are crystals of any kind present, as uric acid, oxalate of lime, etc., minute cysts, purulent infiltration, tubercular, cancerous or other deposits?]

In the normal state, in the adult, each kidney will be found to be about four inches in length, two inches in breadth, and one inch in thickness, of a firm consistency, and of a deep, red color. The weight of the kidney varies from four ounces to six ounces, being somewhat lighter in the female than in the male. The left kidney is generally somewhat longer, thinner and heavier than the right. The fibrous capsule in which each kidney is enveloped is thin, smooth, and in a state of health is easily removed from the surface of the gland.

Congenital Anomalies. Although the absence of both kidneys is of rare occurrence, it is not uncommon to find only one. This may occupy its usual position, and differ from the natural kidney only in being larger—the *unsymmetrical* kidney of Rokitansky. In other cases, we find a more or less complete fusion of the two organs together—the *solitary* kidney.* Either the lower parts of each are connected by a band of renal substance passing across the vetebral column, constituting the horse-shoe kidney; or there is only a single disk-like gland, lying in the median line, and situated much lower down, even as far as the concavity of the sacrum.

Congestion. This, and its consequences, are the main features of hyperæmia of the kidneys, which is of frequent occurrence. This condition is almost always the result of some prior general affection, such as the scarlatinal poison, the suppression of perspiration, or obstructive diseases of the heart.

In a simple congestion, with perfect integrity of the renal tissue, we find the kidney enlarged, and its weight often doubled; of a dark, red color, and dripping with blood when cut into. The cortical substance is somewhat softened, of a dark, red color, presenting in many cases small dark, red spots, the result of hæmorrhagic effusion into and between the tubercles. The Malpighian tufts are distinctly visible on the cut surface, as minute, reddish, semi-transparent grains. In the medullary cones, the congested vessels form long dark-red streaks. If the congestions have occurred in an otherwise healthy kidney, the capsule can be readily peeled off.

A microscopic examination shows the Malpighian and other capillaries loaded with blood, extravasation sometimes

* See No. 1259, College Museum.

taking place into the capsule of the latter, and often into the channel of the fibres.

In extreme cases of hyperæmia and congestion, a fibrinous exudation takes place, which will be found coagulated in the tubes, forming casts of their interior, and consisting of a granular or homogeneous material, entangling blood-globules, and often some particles of detached epithelium.

Hæmorrhage. As a result of acute congestion, or from injury from falls, blows, or wounds of the kidneys, blood may be effused, either beneath its capsule, or within the sinus, constituting hæmorrhage of the kidney.

Nephritis. This differs in no material respect from common inflammation of other parts, and like it, often passes into suppuration.

Its most common causes are:—Excess in the use of irritating and alcoholic drinks; abuse of diuretics; blows or falls on the loins; the presence of renal calculi; and, according to some authors, a peculiar morbid state of the blood, such as gives rise to carbuncles.

This disease can be distinguished from the inflammatory form of Bright's Disease, during life, by its generally affecting only one kidney, by the much greater pain and tenderness in the lumbar region, by the retracting of the testicles, and the higher degrees of febrile excitement. Then, too, the deeply-colored urine which is voided, contains little or no albumen.

In a case of nephritis, unattended with the formation of pus, a *post-mortem* would probably fail to distinguish it from the condition of congestion just considered. Where suppuration was about taking place, the microscope shows the cortical tubes so distended and crowded together by infarcted epithelium, as to be scarcely distinguishable; in some parts the basement membrane gone, and their contents

a uniform mass of nuclei and granular matter. The medullary tubes are also infarcted and opaque.

Pyelitis. Inflammation of the walls of the sinus of the kidney, is thus designated. It may exist alone, or in company with inflammation of the kidney, constituting *Pyelonephritis.* It appears to originate, in many cases at least, secondarily to an attack of cystitis, and would seem metastatic in its nature, the ureter connecting the two inflamed organs, escaping the disease. It is a very serious, and often rapidly fatal disease.

Where the inflammation extends to the kidney tissue, suppuration is likely to follow, resulting thus in the formation of an abscess.

Abscesses. Renal abscesses are found bordered by a red injected halo, which gives rise to a friable product, thus leading to an extension of the abscess. The mucous membrane of the calices and the pelvis, especially when a calculus is present, is softened and inflamed, and secretes a purulent fluid.

The process of suppuration may continue until the whole organ is converted into a pouch of pus. Then, or even before the organ is quite destroyed, the abscess may make its way by the usual process of absorption, and discharge its contents into the calices, to be carried off by the urinary passages; into the ascending or descending colon, or the duodenum, to be passed with the fæcal evacuations; or, after perforating the diaphragm, into the bronchi, whence they are removed by coughing; or through the lumbar muscles; or it may burst into the peritoneal cavity and cause rapid death.

This disease rarely attacks more than one kidney, and the other healthy kidney generally enlarges and becomes capable of performing a double amount of work.

It is well to remember, that a mass of softened fibrinous exudation, bordered by a red halo, may sometimes so far simulate an abscess, that only the microscope can distinguish the one from the other.

Inflammation of the Capsule may take place and cause fibroid thickening, more or less induration, atrophy, and obliteration of the organ. The cortical substance generally suffers most, and the surface is sometimes overspread with purulent matter, while the tissue itself becomes sloughy or gangrenous, or is only congested and softened.

Morbus Brightii. *Bright's Disease. Degenerative disease of the kidneys. Desquamative and un-desquamative nephritis.*

In view of the impossibility of accurately defining the term *Bright's Disease*, we will describe it in general as including those diseases of the kidneys which, in some stage or other of their course, are accompanied by albuminuria, or dropsy, or both. And as it would be foreign to the object of this work, to enter into an examination of the respective merits of the theories, in reference to the nature and course of this disease, we will adopt that classification which seems best adapted to our purpose, and proceed to consider the morbid anatomy of Bright's Disease in its various forms and stages as first suggested by Virchow in his Cellular Pathology, and adopted and developed by Stewart.*

He distinguishes three forms—(1) *the inflammatory*, (2) *the waxy*, (3) *the cirrhotic or contracting;* the first originating in the tubules, the second in the vessels, and the third in the connective tissue of the organ.

1. *The Inflammatory Form.* This has three stages: that

* Bright's Disease, by T. Grainger Stewart.

of inflammation, that of fatty transformation, and that of atrophy. The disease may prove fatal at any stage of its course. In the first stage, an exudation is poured out, and a destruction of the epithelium takes place. This exudation, affecting a large number of tubules, leads to enlargement of the organ, and also to fatty degeneration of the epithelium; its absorption or removal, leads to ultimate atrophy. There is also a *fatty degeneration*, to which we will refer later, which is unattended either with albuminuria or with dropsy, and which does not, therefore, belong to this category.

In this stage of inflammation, the organ is of the natural size, or slightly enlarged; its capsule is unaltered, and can be peeled off readily; its surface is smooth, more or less congested, often pink, sometimes of a dark purplish color, sometimes mottled, pale and purple. On section, the cortical substance is found relatively enlarged, and often congested. The Malpighian bodies stand out prominently from the surrounding tissues, the congested vessels, separated by a varying amount of white (somewhat opaque) deposit, composed of the altered tubules. The vascular spaces between the cones and the cortical substance are uniformly distended with blood. The cones are usually redder than the cortical substances, and from the engorgement of their vessels and the altered condition of their tubules, they present a series of alternating red and white lines, converging to the apex of the cone, at which point the white distinctly predominates. The pelvis of the kidney is natural.

Examination with the higher powers of the microscope shows the Malpighian bodies dense and granular. The tubules are more bulky than natural, and their epithelium is swollen, granular and dense, while within them is frequently seen a transparent homogeneous exuded material, binding into one mass, the epithelium of the tubules. Blood corpuscles are frequently found incorporated in this exuded material.

In the stage of fatty transformation, the organ is enlarged; its capsule natural; its surface smooth or slightly lobulated. It is pale and fatty in color, and on its surface stellate vessels are frequently seen. On section, the cortical substance is pale, of a yellowish-white color, and increased in volume, while the cones are pink, and of natural color and size. The Malpighian bodies do not project prominently as in the first stage.

Under the microscope we find the tubules to be irregularly distended with fatty granules, contained for the most part within the walls of the epithelial cells, which again are imbedded in a material that blocks up the tubules. In the Malpighian bodies, oil globules and fatty cells are of frequent occurrence, but the capillary tuft is natural.

In the last stage of this form, that of atrophy, both the bulk and weight of the organ are diminished, its capsule although natural, is less easily torn off than in health, and on its removal the surface of the gland is found to be uneven, with numerous depressions and elevations. The color is, as in the second stage, mottled. On section we find that, while the cones have remained nearly of their natural size, the cortical substance is small and atrophied, and that which intervenes between the cones is greatly diminished. In the cortical substance, the Malpighian bodies are not prominent, while the vessels, and especially the arteries, are thicker and more prominent.

The pathological distinction between this stage of the inflammatory form, and the cirrhotic or contracting kidney, depends mainly upon the condition of the tubules and the relative amount of connective tissue. When the atrophy is a consequence of inflammation, many of the tubules show evidences of inflammatory action, being blocked up with exudation and epithelium in process of fatty degeneration, while in the cirrhotic there is little or none of this. Again, in the cirrhotic the fibrous stroma is very greatly increased,

which is not the case in the inflammatory form. In the latter, too, the capsule is more easily stripped off, and the occurrence of cysts is less frequent than in the former.

The form of Bright's Disease, of which we are treating, is often complicated with hypertrophy of the heart, affections of the lungs and bronchi, inflammation of serous membranes, derangements of the alimentary tract, diseases of the brain, affections of the eye, liver and spleen.

2. *The Waxy or Amyloid Form.* This also has three stages: that of simple degeneration of the vessels; that in which a secondary alteration of the tubules is suspended; and that of atrophy. An increased secretion of urine characterizes this form from its earliest stages. In all stages the vessels present to the naked eye more or less distinctly the appearance of boiled starch or sago, while a little of the liquor iodi poured over the surface, produces everywhere a yellowish color, but the degenerated parts assume a reddish-brown, mahogany-red, or orange-red hue, and stand out very conspicuously.

In the first stage, the organs are of normal size, weight and color, the latter being however, in some cases, a little paler than usual. Their capsule is easily stripped off, and their surface is smooth. The waxy degeneration begins in the capillary tufts of the Malpighian bodies, and in the transverse fibres of the middle coat of the small arteries. On these there are thickenings here and there, presenting the same sago-like translucency as is seen in the tufts.

In the second stage, the kidneys are increased in bulk and weight; the capsule is easily stripped off, and the surface smooth and pale. The cortex is thick and white, and presents much the appearance of white beeswax. Under the microscope, we see the Malpighian bodies and arteries degenerated as just described, and in addition many of the tubules full of matter, not dense and opaque as in the inflammatory form, but tolerably transparent, consisting of

hyaline tube casts. Their epithelium is swollen, and their basement membrane may also be waxy. It is to this form of disease that the term "waxy kidney" is most applicable.

In the third stage, that of atrophy, the organ is reduced in bulk, from about the natural size to a fourth or even less. Its weight is also diminished. The capsule may be torn off without much difficulty. The surface is rough, granular, and of a pale, waxy color. On section the cortical substance is found much diminished, while the cones are nearly natural. The Malpighian bodies are large and closely grouped together; the smaller arteries dilated and their walls thickened. A few tubules remain distended, but most are collapsed, and are represented only by fibrous tissues.

3. *The Cirrhotic or Contracting Form.* This consists of an hypertrophy of the connective tissue of the organ, and a consequent atrophy of all the other structures. It has been termed also "gouty kidney," "intertubular or interstitial nephritis," and "granular kidney."

In the commencement of the process there is but little diminution in the size of the organ, but the capsule is thickened and more adherent than natural, and the surface is rough and granular. The color is pale or reddish. On section, the cortical substance is found relatively diminished, the diminution being most marked towards the surface. The arteries are prominent, their walls thickened and their cavities often dilated. Even to the naked eye, and to the touch, the increased density and fibrousness of structure are evident. On the surface, and in the substance, cysts are frequently seen. Some are produced by dilatation of the Malpighian capsules, some by dilatation of the tubes, and others from morbid growth of epithelial elements. The tubes are compressed and atrophied by the new fibrous tissue. They contain little of the opaque matter found in inflammatory cases, but translucent hyaline matter is common. All these characteristics become more marked as the disease progresses. In the more ad-

vanced stages, both the kidneys are much reduced in size, but one may be more atrophied than the other. Throughout the whole course of the disease the cones are but little affected.

In gouty cases a deposit of chalk-like substance is occasionally found, composed of needle-like crystals of urate of soda, situated in the stroma of the organ, as well as in the tubules.

In distinguishing a cirrhotic kidney from one in the third stage of the inflammatory or of the waxy disease, besides the characteristic iodine test in the one case, the following points of comparison will be useful:—In the cirrhotic, the capsule is more thickened and more adherent than in the other two forms. In the cirrhotic, the surface is very uneven, frequently studded with cysts, and presents little or no sebaceous-looking material; in the inflammatory and the waxy, the surface is less uneven, cysts are much less common, and in both, particularly the inflammatory, sebaceous-looking material is very abundant. In the cirrhotic, the stroma is greatly increased, especially towards the surface; in the inflammatory and waxy, the stroma, although increased relatively to the other tissues, is not absolutely above the normal amount.

It must also be borne in mind, that both the waxy and contracting forms may be secondarily affected with the inflammatory disease.

Simple Fatty Degeneration of the Kidneys. We occasionally find, along with fatty degeneration of the liver and of the muscular substance of the heart, a fatty degeneration of the kidney, without any trace of inflammation. The kidneys are of about the normal size; the surface smooth, and the capsule not adherent. The organ is more soft and flexible than natural, and the surface is pale, and mottled with sebaceous-looking deposits. On section, we find the

abundant deposition of sebaceous-looking material to be mainly in the tubules of the cortical substance, but also to be found in those of the cones. The microscope shows that the deposit is not in the free cavity of the tubes, but within the epithelial cells.

We may have the simple fatty degeneration in connection with exhausting disease, old age, or with excess of fatty food.

The adipose tissue in which the kidney lies embedded, may increase to such a degree as to penetrate by the hilus into the substance of the organ, impede its nutrition, and induce a kind of atrophy. Rokitansky states that, in the highest degree of this change, the kidney presents the appearance of a mere mass of fat, without the slightest trace of renal organization; the urinary passages at the same time being atrophied and obliterated.

Dislocated Kidney. As a result of over-exertion, tight lacing, or perhaps pregnancy, the kidney sometimes becomes detached from its connections to the surrounding structures, permitting of a change of position, and constituting what is known as *movable* or *dislocated kidney*. The right kidney is said to be more frequently affected in this manner, and the condition is more common with females than males.

Morbid Growths.

Tubercular Disease, though not of frequent occurrence, does sometimes occur in the kidneys. In most cases we find a deposit of tubercle in other organs, especially in the lungs, and often in various parts of the genito-urinary apparatus.

This disease is most liable to occur in the middle period of life. It is found sometimes in the miliary form, sometimes in larger masses.

In a very decided tubercular dyscrasia, we find associated with the miliary granulations a considerable amount of hyperæmia of the organ; but where the deposit is more chronic, the surrounding tissue is quite pale. The large masses are remarkably bloodless. When the tubercular deposits extend to the renal tissue from the mucous membrane of the calices and the pelvis, these cavities become remarkably enlarged, and the whole organ is increased in size, and appears rather pale. The epithelial lining of the tubes is more or less opaque and granular, or of an oily aspect. By the softening and breaking down of the tuberculous deposits, large cavities are formed, containing a mixture of tuberculous detritus and pus. Fibrinous casts are sometimes found in great numbers in the tubes.

Cancer. Secondary, is of more frequent occurrence than primary cancer. The scirrhus and colloid varieties are rarely, if ever, found. Encephaloid growths, especially in children, attain in the kidneys an enormous size.

Cancer of the liver and right kidney, or of the adjacent parts of the stomach, or descending colon and left kidney, frequently coexist according to the observations of M. Rayer and Dr. Walshe. The period of life between fifty and seventy is most liable to cancer of the kidneys.

The natural character of the urine excreted by cancerous kidneys is seldom changed until the encephaloid growth softens and breaks down, when blood, puriform matter and detritus may appear.

Cystic Tumors, supposed to originate from a dilatation of the Malpighian capsules, are sometimes found. The cysts vary in size from a pin's head to a small bird's egg. They may be few or many in number, and are filled either with a clear watery fluid, or with a gelatinous or pigmentary substance. The walls of the cysts are thin and smooth, partly

divided into compartments by imperfect septa. They are confined to the cortical portion of the gland, and may be imbedded in that substance, or project from the surface. The kidney may be unchanged in size, or considerably enlarged. The clinical symptoms of these cysts are very obscure, and of the cause of their formation, little is known.*

Cysts of a congenital origin, are sometimes found in the kidney at birth. They may be of great size, and vast number, and appear to result from a dilatation of the uriniferous tubes, and Malpighian capsules.

Fibroid and *Adenoid* tumors of small size are rarely found in the kidneys; the former within the tubular, the latter within the cortical portions.

Parasites.

Entozoa are occasionally found within the kidneys, among which may be mentioned the *hydatid*, or larval form of the Tænia echinococus.

Cysticercus cellulosæ. The larval form of the Tænia solium.

Eustrongylus gigas. A small cylindrical worm, with the body tinged with red. Male—ten to fourteen inches long, three lines wide. Female—three feet long, six lines wide.

Pentastoma denticulatum. Supposed to be the larval form of a worm found in the nasal cavities of some animals, and consisting of a small sac, with calcified walls.

The Ureters.

As a congenital defect, we find the ureter terminating in a *cul-de-sac*, either in the vicinity of the kidney, or of the bladder. Sometimes they are double or even triple, but they generally unite before their vesical termination.

---

* See No. 1507, College Museum.

Dilatation. When the opening into or from the bladder has, from some cause or other, become greatly narrowed or obliterated, the obstacle to the passage of the urine causes a *dilatation of the ureters.** The sinus and calices at the same time, dilate at the expense of the renal tissue, so that we frequently find but a thin layer of cortical substance compressed against the investing capsule, and the kidney converted into a number of pouches, separated by the remains of the medullary cones. The surface of the kidney is markedly lobulated.

The distention of the ureters may reach such a degree, that they resemble a portion of small intestines, their walls being at the same time somewhat thickened.

From an increase in length sometimes met with, the ureters no longer lie straight, but are thrown into coils or flexures. With dilatation of the ureters, we not unfrequently find coexisting a state of

Inflammation. The mucous membrane is then found swollen and injected, of a villous aspect, and covered with a muco-purulent fluid. Sloughing may ensue with consequent perforation of the ureters and infiltration of the urine into the adjacent tissues, producing an extension of the sloughing process or circumscribed abscesses. The inflammation rarely exists as a primary disease; its most frequent causes, are the irritation from calculi, or the extension of vesical disease. It may extend to the sinus of the kidney, constituting pyelitis.

Morbid Growths.

Cancer of the urinary passages but seldom occurs, and only when found elsewhere at the same time.

---

* Specimen No. 1260, College Museum.

Tubercles may occur in the ureters, even when the kidneys are healthy, but most frequently where they are involved at the same time. These usually coexist with tuberculosis of some important organ. "The deposit takes place in the submucous tissue, and forms, when its progress is chronic, gray granulations, which become yellow, soften, and give rise to small circular ulcers. When the disease is more acute, larger patches of deposit are formed, or the mucous membrane becomes infiltrated throughout with the tubercular product of inflammation, which is at once detached as a cheesy, purulent mass."

Cysts, containing a glutinous or hard matter, about the size of millet-seeds or peas, are occasionally found developed under the mucous membrane of the urinary passages.

The Suprarenal Capsules.

These bodies are sometimes entirely absent. Where one of the kidneys is absent or displaced, the capsule may still be found in its normal position.

Inflammation and Degeneration. Inflammation of the bodies, either acute or chronic, appears to result in the following changes:

First, the organs become slightly enlarged and infiltrated with a semi-translucent material, of a grayish color, soft, homogeneous, or slightly fibrillated, or containing a few imperfect cells. The substance resembles what is often seen in scrofulous disease of the lymphatic glands.

At a later period, this substance gradually changes into a soft, putty-like substance, or into chalky concretions scattered through the body. The whole substance of the organ

may thus be destroyed. It may, at the same time, be found more closely adherent to the surrounding organs.

Dr. Addison has associated with these changes in the suprarenal capsules, a peculiar bronzed condition of the skin sometimes seen, and named from him "Addison's Disease."

Hæmorrhage occasionally occurs within the substance of the capsule, forming a kind of cyst filled with blood. It is more frequent with young children, but is sometimes seen in adults.

Morbid Growths.

Cancer. Primary cancer of these bodies is rare; the secondary form may appear in connection with the same disease in the kidneys, stomach or liver.

Tubercles of the miliary form are rarely seen.

Cysts, both single and multiple, and with varying contents, may be found, generally connected with the enclosing membrane.

Section II. THE URINARY BLADDER.

[**Notice**: 1. *External Characters*—malformations: adhesions; size; wounds, etc. 2. *Walls*—their thickness; condition of several coats; morbid growths, cancer, tumors, tubercles, perforations; sinuses; rupture; wounds. 3. *Contents*—urine, its quantity and characters; blood, its amount and source; pus; calculi, number, size, position, etc.]

Malformations. Among the most common of these, may be mentioned *extroversion*, where there is an absence of the anterior walls of the bladder, with a deficiency in the corresponding portion of the abdominal parietes. From the pressure of the abdominal viscera, the posterior walls of the bladder will be crowded forward, and protrude as a rounded tumor, covered by a vascular mucous membrane, while near the lower portion may be seen the orifices of the ureters,

through which the urine will be more or less constantly flowing.

Malformations of the external organs of generation, are liable to accompany those of the bladder.

The Urachus sometimes fails to close before birth, leaving thus an open passage from the fundus of the bladder to the umbilicus, through which the urine may be noticed flowing after division of the cord.

Dilatation. This is of not unfrequent occurrence, and is the result either of a paralysis of the muscular coat, or of some obstacle to the outflow of the urine. The dilatation may be uniform, or we may find diverticula, formed by a protrusion of the mucous membrane between the fasciculi of muscular fibres. Such partial distensions occur most frequently in the lateral portions, the posterior surface, or the neighborhood of the fundus, and as we should be led to expect from the manner of their formation, are generally destitute of a muscular tunic, or have but a few scattered fibres. Calculi are sometimes found in these pouches after death, the presence of which had escaped notice during life from their concealed position.

Hypertrophy of the muscular coat of the bladder, will generally be found attending cases of obstruction to the escape of the urine, either from an enlarged prostate, stricture of the urethra, or from the presence of a calculus. The muscular coat in these cases is greatly thickened, the interlacing bundles of fibres appearing with great distinctness upon the inner surface.

As a result of this condition, we usually find the bladder greatly contracted, its capacity in some cases being reduced to one or two ounces. Inflammation of the mucous coat, with dilatation of the ureters, will also generally attend hypertrophy of the muscular walls.

Contraction of the bladder is met with, as the result either of irritation of the mucous membrane, or hypertrophy of the muscular coat.

Inflammation of the bladder is generally seen in its chronic form.

The appearances in *acute cystitis* are "strong vascular injection of the mucous lining, with brownish patches in the vicinity of the neck and fundus; more or less thickening of the membrane, with exudation of fibrin or pus on the surface, or foci of the latter in its substance. The mucous tissue may be ulcerated at several points, softened or affected by commencing gangrene. Abscesses may form in the substance of the parietes, and open either into the cavity of the bladder, or upon its external surface. Sometimes the mucous membrane is almost completely destroyed, a few shreds or filaments being the only traces remaining, while the muscular tunic is left as if cleanly dissected. This is probably the result of phagedenic ulceration." The inflammation may spread from the mucous membrane to the muscular coat, but it very rarely reaches the peritoneal covering. In some cases it extends back along the ureters, and even to the kidneys. The morbid action is not often of idiopathic origin, it is more frequently due to the extension of an attack of gonorrhœa, to disease of the prostate, to traumatic causes, to protracted retention of urine, or to the irritation produced by medicines or stimulating drinks. It is sometimes owing to the constitutional poison of rheumatism or gout. It is met with oftener in men than women, and in adults than in children.

Chronic cystitis, called also catarrh of the bladder, is very common in advanced age. The morbid process is excited by some obstacle to the emission of the urine, either paralysis of the viscus, or a stricture, or by presence of a stone in the bladder, or by enlargement of the prostate gland. It may

also result from successive attacks of the acute form, or from extension of urethral inflammation.

Various degrees of vascular injection are presented, with dark-reddish, slate-colored or bluish-black discoloration, more or less thickened induration of the parietes, which assume an homogeneous, lardaceous appearance. An acute attack may supervene upon a state of chronic inflammation, leading to ulceration, suppuration, perforation and extravasation of urine, as in the case of primary acute cystitis.

Chronic or sub-acute inflammation is often attendant upon paraplegia, and proves the immediate cause of death.

Morbid Growths.

Cancer as a *primary* disease, is but rarely met with. Encephaloid, forming nodulated prominences or cauliflower-like excrescences, is the form which vesical cancer usually assumes. They are developed in the submucous tissue, but as they grow, the mucous membrane is also destroyed, and either an ulcer is produced or a soft luxuriant fungous mass.

Tubercle in the form of separate granulations are sometimes met with about the fundus and neck of the bladder in the male, and usually are accompanied with similar deposits in the testes, prostate, kidneys, etc. They are surrounded by more or less hyperæmia, and by softening give rise to circular ulcers of the mucous membrane covering them.*

Tumors. *Polypoid growths*, both of a *fibrous* and *adenoid* character, may be found in the neck of the bladder, both in children and adults. They vary in size from that of a pea to a cherry.

---

* See No. 1261, College Museum.

Cystic tumors of small size are sometimes found within the mucous membrane.

Parasites.

The Sarcina ventriculus, a vegetable parasite, is sometimes found in the bladder, in cases of chronic cystitis.

Of animal parasites, the Eustrongylus, Echinococus, and Ascarides, have found their way into this organ from other parts.

Of the Urethra.

Malformations. As congenital malformation, we need mention only *Epispadias*, fissure on the upper, and *Hypospadias*, on the lower surface, from arrest of development, and complete closure of the opening, *Atresia urethræ*.

Inflammation of the urethra, of the catarrhal kind, the so-called gonorrhœa, commencing at the anterior extremity, may, in severe cases, extend backwards, even into the bladder. The lining membrane becomes swollen, injected, and covered with mucus or muco-purulent secretion, at first thin, then thicker, and then, as the inflammation subsides, thin and pale again. When a chancre coexists with gonorrhœa, "the discharge has usually a grayish or reddish tint, or sanious aspect." From an extension of the inflammation deeper into the fibrous structure of the corpus spungiosum, results, sometimes, an exudation of fibrin in the venous cells, suppuration and abscess. Cowper's gland, the prostate, the vesiculæ seminales, and the testicles, may also be affected by an extension of the inflammation along the continuous mucous lining.

The contact of unhealthy vaginal secretions, whether specific or not, is the most frequent cause of urethritis.

Dilatation and Contraction. *Dilatation* is most frequently the consequence of obstruction to the flow of urine. It occurs generally in the membranous portion, which is expanded into a pouch, occasionally as large as a small orange. The mucous lining of these pouches appears "injected and thickened, presenting fungous vegetations, and occasionally coated with lymph."

Contraction may result from inflammation of the mucous membrane, and finally end in stricture.

Stricture is a very frequent result of inflammation of the urethra. It usually is found in the anterior part of the membranous portion. Contusions and wounds also, often produce stricture.

The simplest form of stricture is, where the canal is partially closed by a fold of membrane passing across it, leaving either a crescentric, or annular opening. In the most common kind of stricture the urethra is narrowed in a much greater extent of its course, sometimes for an inch, or more. When the obstruction occasioned by a stricture is very great, the urethra behind is dilated, often inflamed and sometimes ulcerated, so as to give rise to urinary fistula or effusion of urine.

Rupture of the urethra may result from severe contusions, or fracture of the bones of the pelvis, and being followed by extravasation of blood and urine, inflammation, suppuration or gangrene may supervene, or fistulous openings may be thus established.

Morbid Growths.

Warty growths sometimes appear within the urethra near the meatus. They are generally quite vascular, and may cause considerable obstruction.

Fracture of the Penis has occurred from the giving way of the erectile tissue during coition, in consequence of the state of hyperæmia of the penis. The organ appears broken, and cannot assume the erect condition beyond the part injured.

Paraphymosis, by the strangulation of the glans in front of a tight prepuce, may, if not relieved, lead to inflammation, and even gangrene.

Balanitis commonly occurs as the result of local irritation, not unfrequently set up by a gonorrhœa. The prepuce is much swollen, infiltrated and reddened. The inflammaation is generally complicated with inflammation of the internal lamina of the foreskin, and the mucous membrane of the glans (posthitis), giving rise to excoriation, exudation of coagulable lymph, adhesion of the prepuce to the glans, suppuration and ulceration. "When chronic, it induces exuberant formation of epidermis; and if the deeper parts of the parenchyma of the glans are involved, obliteration, cartilaginous induration and atrophy follow."

Herpes of the Glans and Prepuce, is characterized by the formation of small vesicles or excoriated points upon the mucous membrane of this region, chiefly occurring in persons of a gouty habit of body, with an irritable mucous membrane.

Psoriasis of the prepuce, produces a red, thickened, and fissured condition of the part. Phymosis is apt to occur as a consequence.

Chancres. These specific ulcerations form usually upon the glans, although they may be found in the internal surface of the prepuce, the frænum, and near the meatus within the urethra.

The *Hunterian* or *hard chancre*, is nearly circular, deep and excavated; base and edges are as hard as cartilage, but the hardness is circumscribed; its color is livid or tawny. It may occur upon the integument, the glans, or the body of the penis.

The *non-indurated* or *soft chancre* is more frequently found on the inner surface of the prepuce. It appears as a foul, yellowish, or tawny sore. Indolent fungous granulations are subsequently thrown out, unless it be situated upon the glans.

Phagedenic chancres are of irregular shape, their edges ragged or undermined, their surface yellow and dotted with red streaks. The surrounding margin of skin usually looks pulpy and œdematous; but is sometimes firm and of a vivid red.

The cicatrices left by chancres which have healed, are whitish, more or less hard, striated and depressed.

Morbid Growths.

Warts, belonging to the class of epithelial tumors, sometimes form on the glans, or on the inside of the prepuce. They are commonly the result of repeated inflammations.

Cancer of the penis is of two distinct kinds, occurring as scirrhus or as epithelioma. According to Dr. Walshe, the disease may originate as a warty excrescence, or as a pimple, which discharges an excoriating fluid, scabs, and breaks out afresh, while induration, followed by ulceration, advances at its base. Or it may infiltrate the glans, so as to convert that part into an indurated mass; or venereal ulcers may take on cancerous action.

When of the *scirrhus* form, it usually springs from the ulcers behind the glans, and may thence invade the neighboring parts of the organ.

Epithelioma, commencing as a tubercle in the prepuce,

may after a time give rise to a large, irregular, and sprouting mass, having a granular fungous appearance. In other cases, it commences as a hard scirrhus mass, of a pale, reddish-white color, situated on the glans, or between the prepuce and the glans. This increases in size, cracks, and allows the exudation of a serous fetid discharge. Ulceration then rapidly takes place.

Secondary cancers, except in the adjacent glands, are not a common occurrence. Phymosis and the irritation caused by the retained secretion, seem to act as an exciting, and advancing age as a predisposing cause of cancer.

Encysted tumors, *nævus* and *fibro-plastic* tumors, situated about the prepuce, may also occur.

Section II. OF THE SCROTUM.

[**Notice:** General condition; relaxed or contracted; œdema; cancer; tumors, etc.]

Hypertrophy. *Common hypertrophy* of the integument of the corium sometimes occurs; in this there is no alteration of the subcutaneous tissue.

In *Elephantiasis* of the scrotum, however, the epidermis, the corium, and the subcutaneous areolar tissue, are all, especially the latter, greatly hypertrophied. The areolar tissue is converted into a large mass of fibrous material, infiltrated with an albuminous and fibrinous fluid. "When the disease is confined to the scrotum, and the enlargement becomes great, the penis becomes drawn in and ultimately disappears, while the elongated prepuce is continuous at a navel-like opening in the skin of the surface of the tumor." The enlargement sometimes is enormous, such a mass having been known to weigh two hundred pounds, more than the weight of the rest of the body.

Inflammatory Œdema of the scrotum is an erysipelatous inflammation of this region, giving rise to great effusion into and swelling of the areolar tissue, with a tendency to the rapid formation of a slough, by which the integument may become so affected as to leave the testes and cords entirely denuded. A peculiar form of this disease occurs as a sequence of small-pox and scarlet-fever. Here there is a tendency to speedy gangrenous disorganization of the areolar tissue, and of the covering of the generative organs.

Morbid Growths.

Cancer. Epithelial cancer is the common form under which it attacks the scrotum. This disease has appropriately been called *chimney-sweeper's cancer*, as it appears to arise from the irritation of the soot lodging in the folds of the scrotum. It commonly commences as a tubercle or wart, which, after a time, cracks or ulcerates. It spreads rapidly, involving at last the greater part of the scrotum, and sometimes invading the testes, even extending to the groin and thigh, destroying life by perforating the coats of some of the large vessels. The glands of the groin are not always affected.

Melanotic cancer of the scrotum has been observed.

Fibrous tumors are sometimes developed in this part, and may form a large mass when several are grouped together.

Section III. OF THE TESTICLES.

[**Notice:** Malformations; position, in scrotum, inguinal canals, or abdomen. Size; consistence; condition of coats. *Tunica vaginalis*—contents; serum, blood; adhesions. Abscesses; cysts; tumors; cancer; tubercle, etc.]

Congenital Anomalies. There is no sufficient evidence of the presence of more than two testicles. They are

both absent when the entire sexual apparatus is wanting, and in some rare cases they are imperfectly developed, or only one may exist.

It not unfrequently happens that at birth there is an apparent absence of one or both glands from an arrest or delay in their descent, so that they lie in the groin, the inguinal canal, or the lower part of the abdomen. Sometimes they wander into other situations, *e. g.*, into the perineum close by the anus, and through the crural canal. If the descent does not take place within twelve months after birth it is rarely perfectly completed afterwards without being accompanied by hernia.

The organ is sometimes retroverted, so that the epididymis is placed in front.

The vas deferens may be absent to a greater or less extent, and even the epididymis has been found in great part deficient.

The vas deferens frequently terminates in a blind extremity before reaching the vesicula seminalis.

Hypertrophy and Atrophy. True hypertrophy of the testicles does not occur but when attacked with inflammation, or when the seat of morbid growths the glands may become greatly enlarged. Atrophy, congenital or acquired, is not unfrequent. The effect of old age is very gradual, the gland being often but very little diminished in size.

"The testicle atrophied from disease is not only of diminished size and weight, but is altered in shape, being uneven and irregular, and sometimes of an elongated form. There is little or no trace of the proper glandular structure, the organ being converted into fibrous tissue of a firm texture.

"The testicle in an advanced stage of wasting, not arising from disease of the gland, usually preserves its shape, but feels soft, having lost its elasticity and firmness. Its texture is pale, and exhibits few blood-vessels; the lobuli and septa

dividing the lobes are indistinct, and the former cannot be so readily drawn out into shreds as before. The epididymis does not usually waste so soon, nor in the same degree as the body of the testicle. Fatty matter is also found in the glandular substance of atrophied testicles."

Inflammation. The serous covering of the testes, the *tunica vaginalis*, is liable to acute inflammation, and is then affected as other serous membranes. It becomes thickened and injected with blood, and is coated with a variable quantity of fibrinous exudation. Serum is, at same time, effused into the cavity, and rendered turbid by flakes of fibrin. Adhesions between the opposing surfaces commonly form. The epididymis is apt to partake of the inflammation of the tunica vaginalis, and *vice versa.*

Orchitis and Epididymitis, may be acute or chronic, primary or secondary. In *acute* cases, the testis is congested, and of a darker hue than natural, although not much enlarged. The epididymis, especially its lower part, is much enlarged, and feels thick, firm and indurated. "The coats of the vas deferens are thickened, and the adjacent vessels injected. The tunica vaginalis is inflamed, and its cavity contains the usual effusions."

Suppuration may occur more frequently in primary orchitis, rarely in the secondary form. The pus is liable to burrow and disorganize the tissue of the gland. By a subsequent absorption of the fluid part of the pus, there is often left a whitish mass resembling tubercular deposit, but distinguished from this by being contained in a cyst, and by the altered condition of the adjacent gland tissue. The epididymis not unfrequently remains enlarged, presenting a hard, knotty swelling at its lower part. "In old cases the epididymis acquires the density and consistence of cartilage, and sometimes even of bone."

Atrophy of the gland is a frequent result of inflammation.

Chronic orchitis is characterized by the effusion of a yellowish, homogeneous-looking matter, in the substance of the testicle, within the tubuli. This deposit may shrink and contract, inducing gradual atrophy of the testis, or, by adhesions and ulcerative absorption, a fungous protrusion of the affected tissue may take place.

Hydrocele. *Simple Hydrocele* is a dropsy of the tunica vaginalis. The fluid is usually clear, and of a straw color, sometimes turbid, with albuminous flocculi, and not unfrequently contains shining particles of cholesterine. In old or very large hydrocele, it is often dark-brown or chocolate colored from disintegrated blood. Its quantity is sometimes very considerable. The position of the testicle may be altered by adhesions formed between the two layers of the tunica vaginalis; these latter may also produce a multilocular hydrocele. Simple hydrocele may occur with some of the other varieties to be mentioned, and also with inguinal hernia.

When serous effusion in the tunica vaginalis, is associated with chronic orchitis or other diseases of the gland, we have *hydro-sarcocele.*

In *congenital hydrocele*, the dropsical tunica vaginalis retains its fœtal communication with the peritoneal cavity.

Encysted Hydrocele. In this variety the fluid is contained in cysts, which may be situated (1) beneath the visceral portion of the tunica vaginalis, investing the epididymis; (2) between the testicular portion of the tunica vaginalis and the tunica albuginea, which are thus separated from each other; (3) between the layers of the loose or reflected portion of the tunica vaginalis. The two last mentioned varieties are of rare occurrence. The cysts have thin fibrous walls, a lining of tessellated epithelium, and contents usually clear, although sometimes mixed with various exudations of fibrin or even blood. Spermatozoa are very frequently found in

the fluid of these cysts. Their presence is undoubtedly due, as pointed out by Cushing, to the rupture of a neighboring seminal duct. They are but rarely found in the fluid of common hydrocele.

Diffused Hydrocele of the Cord, gives rise to an oval or oblong, irregular, circumscribed tumor, extending below and into the inguinal canal. "It consists in the enlargement of the cells of the areolar tissue, and their distension with a white or yellowish serous fluid. The inclosing fascial sheath is condensed and thickened, and at the lower part of the swelling, which is always the largest, separates it completely from the tunica vaginalis."

Encysted Hydrocele of the Cord forms a tumor of oval shape, loosely attached to the vessels of the cord which pass behind it. Instead of a single cyst, there may be a number, forming a series along the cord.

Hæmatocele, is a tumor formed by an effusion of blood from the vessels of the testis or of the spermatic cord, into the cavity of the tunica vaginalis. It may be traumatic or spontaneous, and may attain a large size. Coagula are formed either in separate masses, or in firm layers, as in aneurism. Inflammation may be set up, leading to fibrinous and serous effusion, and to suppuration, or the blood may putrify and gangrene result. The tunica vaginalis is commonly thickened, the testicle unaffected, or in old cases atrophied from pressure.

Diffused Hæmatocele of the Cord results from the rupture of some vessels of the cord, in consequence of which blood is effused within the spermatic fascia. A tumor of enormous size may be formed should the bleeding continue, or recur after having been arrested. The usual cause is some strain or violent exercise.

Varicocele is a morbid dilatation of the spermatic veins.

"The enlarged veins hang down below the testicle, and reach upwards into the inguinal canal; and when very voluminous, conceal the gland, encroach on the septum, and extend to the other side of the scrotum." The left veins are more frequently affected than the right. In an advanced stage of the disease, the coats of the veins are thickened, and do not collapse when cut across. In cases of slight varicocele, the nutrition of the testis is not interfered with, but when large, it produces marked atrophy.

Morbid Growths.

Cancer is most frequently primary, and generally attacks the body of the testis in the first instance, the epididymis remaining for some time unaffected.

The scirrhus variety, characterized by its great induration, is rarely met with.

Encephaloid is the ordinary form; it commences as one or two masses among the tubuli, which it gradually destroys. The tunica albuginea is absorbed by degrees, gives way, and allows the growth to project into the scrotum and there freely vegetate. The scrotum is slow to be involved in the disease, but at first becomes distended, sometimes to the size of a cocoanut, and then gradually ulcerates. The spermatic artery and the accompanying veins become greatly enlarged. The cord may also be attacked with the disease, while secondary cancers spring up in various places. The lymphatic glands in the neighborhood become enlarged, especially those in the iliac fossa. The inguinal glands do not generally become affected until the skin has become involved in the disease.

Intermixed with the encephaloid are commonly found masses of a bright yellow color, supposed by some to be deposits of tuberculous matter, but by others, merely plastic matter undergoing fatty degeneration.

Colloid and melanotic cancers have rarely been observed in the testes.

The tunica vaginalis is said to have been attacked with cancerous disease, the testis remaining healthy.

Cystic Disease of the Testis. The cysts may be but few, or very numerous. The testis is proportionately enlarged, indurated, of a yellowish-white and opaque appearance, and studded with cysts varying in size. The contents are, in the younger cysts, a clear, amber-colored fluid; in the older ones, more thick, viscid, highly albuminous, and of a brownish color. The cysts are sometimes imbedded in solid stroma, probably of fibroid tissue; sometimes small masses of enchondroma are found between them. When of an innocent character, the cystic disease is characterized by the presence of tessellated epithelium in the cysts; when malignant, by the presence of nucleated cancer cells.

"Occasionally cystic tumors of the testicle are met with, in which the substance of the organ is atrophied or absorbed, and its place occupied by one or more large thin-walled sacculi containing fluids of different color and consistence, dark or fatty."

Tubercles are not very unfrequent, and appear sometimes in the body of the gland, but oftener in the epididymis, whence they may spread to the testis. They occur as gray granulations, infiltrated or encysted, and varying in size from a pin's head to a plum-stone. They are commonly found in all stages of development and disintegration in the same organ. Their presence in and between the tubuli produces inflammation, suppuration and disorganization of the structure of the testis, with which they become mixed, so as to form a cheesy mass of a dirty buff color. This may, by ulceration, perforate the scrotum, and protrude as a fungous growth of a pale, reddish-yellow granular mass.

This disease of the testis is frequently found in connection with pulmonary tubercle, or general tuberculosis.

Tubercular syphilitic sarcocele, described by Hamilton, of Dublin, is a variety occurring in an advanced stage of constitutional syphilis.

"*Cretaceous matter* is occasionally met with in the testis, doubtless the residue of tuberculous deposit which has softened and undergone calcareous change."

Tumors. *Fibroid tumors* of small size are sometimes found developed within the visceral layer of the tunica vaginalis, or within the substance of the cord.

Fatty tumors may be found, which have originated within the tunica albuginea, the dartos, or within the fibrous connective tissue of the cord.

Cartilaginous tumors of small size, originate with the substance of the gland, and are frequently associated with cystic disease or cancer.

Section IV. THE SEMINAL VESICLES AND PROSTATE.

[**Notice:** 1. *Seminal vesicles*—present or absent; size; distended or empty; contents. Condition of mucous lining; inflamed, thickened, ulcerated, perforated; tubercular deposits, etc. 2. *Prostate gland*—abnormalities; size; density; enlargement of middle or lateral lobes; color of section; appearance of inflammation; abscess; tumors; cancer; tubercle. *Contents of ducts*—calculi: their position, size, etc.]

Congenital Anomalies. The vesiculæ seminales participate in the defective development of the testes, being absent or imperfect when their related glands are so.

Inflammation. It is not uncommon for these bodies to be attacked with chronic catarrhal inflammation, which causes a swelling of their mucous membrane, the secretion

of unhealthy mucus, dilatation of the cavity, and thickening of its walls. Ulceration, perforation, and the formation of abscess in adjacent parts, may result.

Tubercular Deposits are occasionally met with, chiefly in cases of extensive tuberculosis. "It appears as a thick, yellow, cheesy, lardaceous, fissured, purulent layer, replacing the mucous membrane." It never occurs before puberty.

The Prostate Gland.

Congenital Anomalies. When the organs of generation are imperfectly developed, the prostate gland is generally found to be so too.

Hypertrophy and Atrophy. *Hypertrophy* is of frequent occurrence, especially in connection with old age. All the lobes may be enlarged equally, or nearly so, or one or the other of the lateral lobes alone, or the middle lobe, without any corresponding hypertrophy of the lateral. Hypertrophy of the middle lobe, when considerable, throws the neck of the bladder forward, and increases the depth of its lower region, so that calculi may lodge behind and below the prostate in its cavity. The canal of the urethra becomes lengthened in its prostatic portion, and may be narrowed by compression, or considerably dilated, so that the prostatic sinus may contain two or three ounces of urine. The retained urine decomposing, may cause irritation and inflammation of the bladder.

The texture of the enlarged gland is generally indurated, though sometimes it is found to be looser and softer than natural. On section, the cut surface bulges above the level, and the shades of color are more strongly marked than in health. Frequently single gland-lobules are found hypertrophied. Small cavities, dilatations of the gland-

follicles, are occasionally met with, sometimes empty and sometimes containing a yellow, pus-like fluid, the prostatic secretion in a thickened state.

Atrophy, with consolidated texure, is found with atrophy of the testes.

"*Eccentric atrophy* is occasionally met with; the cavities are dilated and the walls thinned, in consequence of the increase in size of calculous concretions in its follicles. Cases sometimes occur, in which the whole of one lobe, or even the entire organ, is converted into a thin fibrous capsule, the proper substance of the gland being almost wasted."

Inflammation. As a result of suppressed gonorrhœal discharge, the prostate may be attacked with acute inflammation, followed by suppuration, or chronic enlargement, or an irritable state of the gland, with increased secretion.

Abscesses, single or multiple, may occur, and open into the bladder, into the prostatic sinus of the urethra, into the rectum, or, externally through the perineum.

Ulceration rarely occurs.

Morbid Growths.

Cancer of the prostate is rare; encephaloid is almost the only form that occurs. The gland is enlarged and the growth may perforate the mucous membrane of the bladder, and vegetate in its cavity.

Tubercles occasionally occur. Their softening and disintegration give rise to abscesses, which pursue the same course as inflammatory abscesses.

Fibrous tumors, varying in size from that of a pea to a nut, are of frequent occurrence; sometimes but loosely attached to the hypertrophied gland.

Cysts are of extremely rare occurrence, commonly resulting from closure and dilatation of the gland-follicles.

Concretions. "In greater or less numbers, they are of almost constant occurrence in the prostatic cavities; they may often be seen on making a section of the gland, as reddish-yellow grains. Their form varies very much; in the smaller it approaches the oval or circular; in the larger it is more polygonal or triangular. They are not unfrequently pale or colorless. The contents of these semi-organized formations appear to be earthy matter (phosphate, with a little carbonate of lime), tinged by the ordinary yellow pigment which is so often derived from the blood.

It is most probable that, in ordinary healthy states, these concretions undergo solution at an early period of their existence, yielding up their contents to form part of the secretion of the gland. But, if this does not occur, and they go on increasing in size, they become the nuclei, or are developed into *prostatic calculi.* These are not unfrequently very numerous; as many as fifty or sixty have been found in an atrophied, dilated prostate. The calculi sometimes cohere, and form a large mass, projecting into the membranous portion of the urethra, which becomes in consequence much dilated. The smaller calculi often escape into the bladder through the dilated prostatic ducts; if they remain there, they excite irritation of the mucous membrane and deposition of phosphates upon their own surface."

CHAPTER IV.

THE FEMALE GENERATIVE ORGANS.

Section I. THE PUDENDA AND VAGINA.

[**Notice:** 1. Of the *pudenda*—malformations; condition of the labia and clitoris; size; color; abrasions; ulcers; eruptions; tumors; marks of violence, etc. *Orifice of urethra*—growths around, their number and size. *Hymen*—present or absent; entire or lacerated; imperforate.]

1. The Pudenda.

Congenital Anomalies. In rare cases the external organs are entirely absent, more frequently but partially developed.

The nymphæ may be found abnormally enlarged.

The clitoris may be abnormally long, perforated, or cleft.

Many of the cases of so-called hermaphroditism are instances of an undue congenital development of the clitoris, with an irregular development of the other organs of generation, either external or internal, or both.

Hypertrophy. We may find an hypertrophy of the labia, due to a kind of solid œdema, perhaps originally dependent upon a fissure or ulcer of the part. The nymphæ are often abnormally enlarged, not necessarily as the result of an abuse of sexual indulgence. In new-born infants, they normally project beyond the labia majora. The clitoris occasionally is enlarged, elongated and pendulous, and, in some cases, attains an enormous size. A specimen preserved in the Museum of the University of Bonn, is fourteen inches in circumference and weighs eight pounds. There is no necessary connection between an habitual sexual indulgence and an enlarged clitoris.

Varicose swellings of the labia may reach a considerable size, and, although not generally interfering with parturition, have been known to be lacerated at that time with fatal issue.

As the result of external violence, or during parturition, suggillations often occur in the labia, and may give rise to considerable swelling. The tumor presents a tense, smooth surface, of a livid color, thus distinguished from a varicose swelling, with the peculiar vermicular character of its contents.

Inflammation. The cutaneous covering, the mucous lining, the cellular tissue, and the sebaceous and mucous follicles, may be the seat of inflammation, resulting from external or internal causes.

Eczematous and apthous inflammations may result from derangement of the digestive organs, from pregnancy, from a want of cleanliness, or from excessive sexual indulgence, and are of frequent occurrence.

The loose cellular tissue is especially favorable to œdematous swelling, and when the inflammation has a phlegmonous character, extensive sloughing may result. It occasionally occurs as an epidemic among those in early life.

The vulvo-vaginal glands are also liable to inflammation of a catarrhal, herpetic or syphilitic character, resulting in chronic ulceration, or tedious discharges. Young children are frequently liable to a benignant inflammatory affection of these parts, giving rise to much irritation and a muco-purulent secretion.

Morbid Growths.

Warty excrescences, arising from a syphilitic taint, may affect the labia, the entrance of the vagina, and the clitoris. They consist of groups of small pedunculated tumors, producing a sort of mushroom appearance.

Syphilitic mucous tubercles are described as round, flattened tubercles, raised above the surrounding tissues, sometimes becoming elongated, of a reddish-blue color, and frequently ulcerated on the surface.

Cystic tumors are also met with in the labia. They consist of a membranous envelope, containing a transparent, glairy fluid, and often attain a large size.

The mucous membrane surrounding the orifice of the urethra, is liable to an hypertrophy of development, giving rise to small vascular, generally pedunculated tumors, extremely sensitive during life, and liable to become abraded.

Elephantiasis may attack the labia majora, the nymphæ, or the clitoris, and may attain to a great size. It consists of the loose connective tissue of the part, infiltrated with serum, and covered either with the smooth skin, or one which has become roughened by hypertrophy of the papillæ. It may appear as a diffused hypertrophy, or be furnished with a pedicle, and resemble a polypus.

Fibrous, *fatty* and *scirrhus* tumors are also met with in this part of the system.

2. The Vagina.

Congenital Anomalies. The valvular fold of membrane which protects the virgin vagina, the hymen, may be imperforate or much indurated, and of a cartilaginous consistency. It may thus entirely close the vagina. Besides this, we may find the vagina terminating in a cul-de-sac, either with the uterus present or absent, and the ovaries normal or abnormal. The vagina may also be duplicated, by a septum extending the entire length of the canal, or only partially dividing it. There may be at the same time a double uterus. Entire absence of the vagina is also met with, the internal organs of generation being also absent, or but imperfectly developed.

Morbid States. Occlusion or stricture of the vagina sometimes occurs as the result of external injury, or of cicatrization of ulcers.

Dilatation, or lengthening of the vagina, also occurs.

The rigidity or laxness of the walls of the vagina, varies much in different individuals, according to constitution, age, and the effects of cohabitation and child-birth. Prolonged uterine or vesical disease, often produces a very lax condition of the mucous membrane of the vagina. In old women we often meet with this relaxed state, which may amount to a complete prolapsus. The anterior wall is particularly liable to be thus affected.

Laceration and Rupture. External mechanical injuries may produce laceration of the vagina. During parturition, either from unusual rigidity, or from want of care on the part of the attendant, the lower portion of the canal is apt to give way when the labor pains are at their height. The lesion may vary from a mere laceration of the fourchette, to a rupture of the entire perineum, from the vagina to the anus. Lacerations of the upper portions of the vagina also occur with rupture of the uterus, or even independently of it.

Lacerations of the vagina are not necessarily fatal, but may result in vesico-vaginal fistula, where a communication is established between the bladder or urethra, and the vagina; or in recto-vaginal fistula, where the fistula opens into the rectum.

Inflammation. The mucous membrane of the vagina is frequently the seat of inflammation. The commonest form is the *catarrhal*, which may be acute or chronic. In the first stage, the passage is reddened, heated and dry. This is followed by an abundant secretion of white, creamy mucus; or of a more purulent discharge, if the inflammation has anything of a specific character.

Croupous inflammations, in connection with general disease, or a similar disease of the uterus, may occur. They produce a solution of the mucous membrane and the submucous tissue, varying in shape and depth, and not unfrequently resembling gangrenous destruction. (Rokitansky.)

A chronic thickening of the mucous membrane, as the result of inflammation, is occasionally met with.

The follicular, syphilitic and carcinomatous ulcer also affect this part.

Suppurative inflammation may result from injuries, ending in the formation of an abscess in the fibrous structures, which may burrow within the pelvic areolar tissue, or extend into the labia.

Gangrene sometimes results from injuries received during parturition, or from a degeneration of croupous inflammation in a vagina affected with blenorrhœa of a gonorrhœal or syphilitic origin.

Morbid Growths.

Polypi and *cysts* are the varieties most frequently met with in this situation. The polypi may be either fibro-vesicular, or cellulo-vascular, varying greatly in size. The encysted tumors, originate in an obstruction of the follicles of the part, and contain a glairy, transparent, greenish, or dirty-brown albuminous fluid.

Myomatous tumors may be found developed within the muscular coat of the vagina, the posterior wall being their usual position.

Carcinoma may occur primarily, or by an extension of the disease from the cervix uteri.

The form in which it appears is the encephaloid kind, the appearance of which is described in connection with the uterus.

Malignant *epithelial* growths are not met with in the vagina.

Section II. OF THE UTERUS.

[**Notice:** 1. *In situ*—absence or malformations. Size, and relation to surrounding organs and walls of pelvis; high or low in pelvis; versions; flexions; adhesions, etc. 2. *After removal*—os; size and shape, round, oval, irregular, etc. *Lips*—size; form; color; condition of surface; soft or firm; rough or smooth; abrasions; granulations; ulcers; tumors, etc. *External characters of body*—size; measurements; weight; tumors; rupture; consistence, hard or soft. *After section*—thickness of walls; density; condition of blood-vessels; abscesses; tumors, etc. *Uterine cavity*—size and form. Contents; serum; size and condition; blood; mucus; pus; tumors. Condition of mucous lining, cancerous growths, etc.]

According to the measurements of Kilian, the uterus in the virgin adult, varies in length from twenty-four to twenty-six lines; the greatest breadth is eighteen lines; the thickness nine lines; the cervix is from ten to twelve lines long; its breadth from six to eight; its thickness from five to six lines. The length of the uterine cavity is twelve lines, and its breadth nine lines. After one or more births all these measurements increase from one-fifth to one-quarter. The weight of the uterus varies from eight to twelve drachms, and may, after several pregnancies, amount to two ounces.

Congenital Anomalies. The entire absence of the uterus is an exceedingly rare occurrence, and need not affect the health of the individual. A seeming multiplication of the organ is occasionally met in the *bilocular* and *horned* uterus. In the former, a more or less perfect septum extends through the organ in the median line, while in the latter, the uterus is divided into two lateral portions, by a prolongation of the angles or cornua, giving a resemblance thus to a permanent form seen in many of the lower animals.* We may also find the so-called *uterus unicornis*, where only one of the two

* See No. 359, College Museum.

rudimentary bodies from which the normal uterus is developed arrives at maturity.

All these kinds of uteri are capable of becoming impregnated, but parturition, although not necessarily fatal, seriously endangers the life of the patient; owing, according to Rokitansky, partly to the want of the necessary dimensions of the part that undertakes the functions of the entire organ, and partly to the obstacle opposed to the uniform development of the impregnated half by the unimpregnated half. These circumstances favor rupture of the uterine walls.

Hypertrophy and Atrophy. These are in part normal at the periods of puberty and change of life; as a morbid state, the first is of more frequent occurrence than the last. Either may affect the entire organ, or only a part. After the climacteric period the cervix often disappears entirely.

Hydrometra. As the result of inflammatory processes, the os internum or the os externum may become occluded, causing a retention of the secretions from the diseased mucous membrane of the uterus. This secretion gradually changes into a sort of thin serum. The uterus becomes dilated, and we have hydrometra.

Hæmatometra is a condition where the uterus is dilated with serum mixed with blood, or exclusively with retained menstrual blood. This latter state is more frequently the result of congenital than of acquired atresia.

The amount of dilatation may vary greatly.

Malpositions of the Uterus. These may be of two kinds: (1) where the direction of the axis is changed; or (2) the organ becomes altogether displaced, so that its relation to all the pelvic viscera is altered. Of the former class, are ante- and retro-versions, with flexions, and lateral obliquities; of the latter, prolapsus procidentia and inversion.

Inversion may occur spontaneously or as the result of manual interference in the removal of the after-birth. The fundus may pass but a short distance into the cavity of the organ, or the uterus may be turned completely inside out. Inversion may also result in an unimpregnated uterus from the presence of fibrous polypi, growing from the inner surface of the fundus. These growths, when complicating pregnancy, favor inversion by disturbing the regular expulsive contractions.

Hæmorrhages. An effusion of blood into the cavity of the uterus, occurs normally at every period of menstruation; from some morbid condition of the vessels of the uterus, it may at times amount to an hæmorrhage. Attending parturition, it may be due to placenta prævia; or following, to atony or defective contraction of the uterine walls, where we find the uterus maintaining its dilated condition with flabby and soft walls; or to spasm or irregular contraction, to which the term, "hour-glass contraction," has been applied.

The presence of polypoid tumors is frequently attended by hæmorrhages.

Peri- or Retro-uterine Hæmatocele, is an accumulation of menstrual blood, generally in the utero-rectal *cul-de-sac.* It may arise from rupture of a blood-vessel, from defect in the excretion of the menses, or form a morbidly profuse exhalation of blood from the genital organs. The extravasation may be reabsorbed, or may by perforation be discharged by the rectum or vagina, or may lead to suppuration and the formation of an abscess.

Inflammations. The traces of *acute catarrhal* inflammation are but seldom to be discovered. They present the same features as catarrhal inflammations of other mu-

cous membranes, congestion and swelling, with a more or less abundant secretion of muco-pus.

In *chronic catarrhal inflammations*, the membrane is found thickened, of a brownish or slate-gray color, with a more or less purulent secretion, often blood-streaked. The walls of the uterus may be atrophied or hypertrophied.

Catarrhal erosions, and follicular ulcers, the result of the bursting or suppuration of the stopped-up follicles, usually accompany catarrhal inflammations.

Acute Metritis. Here we find the organ swollen and congested, and its substance of a darker color. The mucous membrane shows symptoms of a catarrh, and the peritoneal covering is also congested. Occasionally extravasations of blood are found in the substance or cavity of the uterus. The inflammation may lead to the formation of abscesses within the uterine walls.

In *Chronic Metritis* the organ is generally much enlarged. The walls are remarkably pale and dry, thick and hard. The mucous membrane almost always presents the appearances described under chronic catarrhal inflammation, while the peritoneal covering frequently shows numerous adhesions to the neighboring organs.

Ulcerations may be catarrhal, with superficial erosions or follicular ulcers; or syphilitic, in the form of the hard and soft chancre; or we may, in rare cases, have the corroding ulcer, described by Dr. John Clarke, and differing from genuine carcinoma only in the absence of an indurated deposit.

Morbid Growths.

Fibroid tumors are of most frequent occurrence. They are found either imbedded in the texture of the uterus, or protruding from its inner surface into the cavity, or from some part of its external surface.

Those projecting into the cavity of the uterus, called also *fibrous polypi* or submucous tumors, are most frequently met with. Their pedicles are generally situated just below the openings of the Fallopian tubes, although they spring also from the posterior wall and from the fundus, less frequently from the anterior wall, and still more rarely from the cervix uteri.

Recent investigations go to show that these tumors are to be classed with the homologous, rather than heterologous productions, and that they are developments of true muscular tissue. To the naked eye this structure varies in some respects; at times they present a concentric disposition of fibres, but more commonly an irregular, wavy appearance, without any uniformity of arrangement, and in the latter case, frequently with cavities containing blood, a dark-colored gelatinous fluid, or a clear serum. Under the microscope, a fibrous structure is scarcely perceptible, but elongated nuclei are seen, imbedded in an amorphous stroma.

The vascularity of fibrous tumors varies. The majority are but scantily provided with vessels. The tumors imbedded in the uterine tissue form globular, white, glistening, dense tumors. There may be only one, or they may be numerous, and may vary in size from that of a pin's head to that of a melon. These growths are subject also to secondary changes; thus we may find abscesses in the very centre of fibroid growths, or they may contain encysted melanotic tumors, or a species of calcification may be developed.

Fibrous tumors have not been observed before puberty, but occur, according to Lee and Bayle, most frequently in virgins.

Polypi and Polypoid Growths. These growths—not to be confounded with the fibrous tumors, as is fre-

quently done—are soft and succulent, and project into the cavity of the uterus, or hang into the vagina. They are attached by a pedicle of greater or less width, to the surface from which they spring, and are covered with the mucous membrane of the part. They are essentially a morbid condition of the structures of the surface, the mucous membrane, the follicles, or sebaceous crypts of the different parts of the uterus.*

Polypoid tumors may give rise to hæmorrhages. They may become inflamed, suppuration or even gangrene supervening. In this way the pedicle may be destroyed, and the tumor be expelled.

Cysts and Tubercular Deposits are extremely rare in the uterus. The latter affect primarily the lining membrane, where it occurs in the miliary form, or accumulated in masses, aggregated into nodules, or forming a cheesy layer over the entire surface. The uterine tissue may be secondarily affected, and is then liable to become infiltrated with the morbid product. Traces of the disease are found also in the vagina as spots of ulceration, and in the Fallopian tubes.

Cancer. Carcinoma of the uterus is of frequent occurrence. The period of life in which it is most frequently met with, is that between the fortieth and fiftieth years. Although met with in single women, it is found most frequently among the married.

In general, this disease attacks the cervix first, whereby it is distinguished from fibroid growths.

Many instances of supposed cancers, prove on microscopic examination, to be nothing more than an irregular thickening and induration of the cervix, consequent upon chronic inflammation.

---

* See No. 329, College Museum.

According to Rokitansky, the prevailing form of uterine cancer is the medullary carcinoma, appearing as an infiltration of a white lardaceo-cartilaginous, or loose encephaloid matter, in which the uterine tissue is lost, and giving rise to the characteristic nodulated surface of the cervical portion of the organ.

Of rarer occurrence is the fibrous cancer, consisting of dense, whitish, reticulated fibres, containing in their meshes a pale-yellowish translucent substance. Its limits are not sharply defined, but are lost in the uterine tissue.

Nowhere does the destructive character of the cancerous disease manifest such virulence, as when attacking the uterus. The degeneration spreads more or less rapidly to the adjoining parts, and, in extreme cases, the whole contents of the abdomen are matted together, and present a frightful spectacle of disorganization and destruction.

Cauliflower Excrescence of the cervix, is regarded by both Rokitansky and Renaud, as a modification of encephaloid growth. It appears as an irregular projection, with a base as broad as any other part of it, attached to some part of the cervix. The surface has a granulated feel. On removal from the body it collapses, owing to its vascular character.*

Morbid Conditions following Parturition.

Rupture of the Uterus is not unfrequent as a concomitant of pregnancy in the horned or bilocular malformation of the organ. It is also met with in the normal uterus.† A laceration of the os tincæ occurs at every birth, and so long as it does not extend beyond the circular fibres of the cervix

* See No. 331, College Museum.

† See Nos. 335 and 360, College Museum.

is not dangerous. The result is generally more disastrous when the rupture extends beyond this point. It may penetrate the entire thickness of the organ, so as to allow of the escape of the fœtus into the abdominal cavity, or only one layer of the walls may give way, or only the peritoneal investment may be lacerated, while the uterus itself remains uninjured. Rupture of the uterus may also result from external injury before parturition. It is not necessarily fatal. Primiparæ are more liable to this accident than multiparæ.

Puerperal Inflammations. Where the uterus has itself been the main seat of inflammation, we find that an exudative process has given rise to the formation of a yellowish or greenish, more or less, gelatinoid lining on its internal surface, causing a ragged, patchy appearance. This exudation may be easily detached from the subjacent mucous membrane, which, according to the intensity of the disease, is more or less reddened, tumefied and softened. This condition may penetrate to the deeper tissues, and involve the entire thickness of the uterus, which will then, also, be more or less softened and discolored, infiltrated with a thin sanious product, and even converted into a mere pulp.

The dirty-colored, brownish, flocculent matter that is found investing the inner surface of the uterus soon after delivery, and which is merely the residue of the decidua, must not be mistaken for the product of disease. The ragged appearance of the part to which the placenta was attached, due, according to Dr. John Clarke, to the remains of the maternal portion of the placenta and the coagula of blood left after its separation, is also liable to be the source of error. In both cases, however, if the apparent exudation be scraped off, which can easily be done, we find the *healthy* surface underneath.

In *putrescence*, the lowest form of uterine inflammation,

we find the internal layer of the organ covered with a thin, opaque, or more dense product, varying in color from pale green to dark brown, beneath which the tissue to a greater or less depth is converted into a similar pulp. We sometimes find small abscesses within the muscular tissue without any perceptible change in the surrounding parts; in most cases, however, the structure of the muscular fibre is entirely destroyed.

Metrophlebitis. Inflammation of the venous channels and lymphatics of the uterus, is a very frequent cause of the fatal termination of cases of puerperal fever. Tonnellé found it present in one hundred and thirty-two cases out of two hundred and twenty-two. Besides the appearance of the vessels common to ordinary phlebitis, we find the uterus studded with small abscesses which may be traced to the vessels. The lymphatics may be primarily and coincidently affected, or they may be attacked separately and secondarily; the former is the more frequent. They present the same varicose appearance as the veins, and are thickened and distended with the purulent or sanious products of the inflammation.

Puerperal Peritonitis, is the lesion most commonly associated with puerperal fever. It may be confined to the surface of the organ, particularly to the part surrounding the neck, or may involve more or less entirely the whole sac. In the sthenic forms, the appearances presented, resemble those of ordinary peritonitis. In the low typhoid forms, there is a peculiar absence of congestion and redness. The ordinary character of the exudation, is a copious effusion of an aplastic character, of a dirty-yellow, greenish, or brownish hue, in which flocculent particles of lymph are found floating, while but small patches of a thin, non-coherent exudation, are observed in the peritoneal sac. The smell of the fluid is distinctive, differing from anything found in the human body in health or disease, and after having been once noticed, cannot fail to be recognized.

Extra-uterine Pregnancy.

This species of gestation may be considered under the following varieties, receiving their names according to the part of the passage where the ovule becomes fixed:

1. Abdominal Pregnancy.
2. Tubo-abdominal Pregnancy.
3. Tubal Pregnancy.
4. Interstitial Tubo-uterine Pregnancy.
5. Utero-tubal Pregnancy.

1. *Abdominal Pregnancy.* This includes all cases in which the fecundated ovule fails to engage in the tube. Three varieties may occur. The ovule may remain in the ruptured ovisac and there be developed, giving rise to an *internal ovarian* pregnancy. Should it after escaping from the Graafian vesicle adhere to the surface of the ovary, we have an *external ovarian* pregnancy. Finally, if the ovule, escaping from the ovary, fall into the peritoneal cavity, and there undergo development, a *peritoneal* pregnancy results. In the last class, the points to which the ovule may attach itself are exceedingly numerous. The placenta has been found attached to the peritoneum covering the right or left iliac fossa, sometimes to a part of the small or large intestine, and sometimes to the anterior wall of the abdomen.

2. *Tubo-abdominal Pregnancy.* This name is applied to those cases where the ovule having but just entered the tube, is arrested by an obliteration or constriction of the canal, and there undergoes development. The placenta is attached in the interior of the tube, and the fœtus developed in the abdominal cavity, and both are surrounded by a cyst, the walls of which are partly made up by the walls of the dilated tube. This includes also what has been described as *tubo-ovarian* pregnancy.

3. *Tubal Pregnancy* is the most frequent of all varieties of extra-uterine pregnancy. The ovule is here arrested and developed at some spot within the tube, between its abdominal extremity and the point where it enters the uterine walls. The fibres of the enormously distended tube constitute the envelope of the fœtal cyst.

4. *Interstitial Tubo-uterine Pregnancy.* Here the ovule is arrested in that part of the tube that traverses the thickness of the uterine walls. It may remain, during its development, enclosed by the tube, or it may make its way through these and be developed within the muscular fibres of the womb itself.

5. *Utero-tubal Pregnancy* is a very rare but possible form of extra-uterine pregnancy. The ovule may ingraft itself just at the internal orifice of the canal. "In this variety, the fœtus is found in the abdominal cavity; the cord leaving the umbilicus enters the Fallopian tube, traverses its whole length, and is inserted in the placenta, which is itself attached to the internal surface of the uterus." The tube has evidently been ruptured, allowing the passage of the fœtus into the peritoneum, while the placenta remained in the uterus.

In all these pregnancies, the ovule has originally its proper membranes, the chorion and the amnion. The structure of the walls of the enclosing cyst varies according to the species of extra-uterine pregnancy. As a general rule, the fœtus exhibits nothing peculiar in its development. The most common of the numerous alterations which it may undergo, are putrescent dissolution of its soft parts, and the separation of the various pieces of its skeleton; a complete drying-up or mummification; and transformation of all its tissues into an osseous or cretaceous substance.*

In the tissues of the mother, new or increased vascularity

* See Nos. 325 and 326, College Museum.

of those parts where the ovule is attached will be noticed, while the womb will be found to have sympathized with the development of the fœtus by an hypertrophy of its mucous membrane, which, however, does not last more than a few months. A gelatinous substance, a kind of thick, ropy mucus, is also frequently found in the neck of the uterus. These appearances are generally wanting in the womb, where the pregnancy has advanced beyond term.

Extra-uterine pregnancy generally terminates fatally. In the abdominal form, the pregnancy may progress to the later months of gestation, when, losing its vitality, the fœtus may decompose, producing peritonitis and death, or it may become encapsulated and gradually absorbed; or by the ulcerative process, the remains may be discharged into the intestinal canal, or through the abdominal walls. Where the case has been diagnosed before death, the dead fœtus has been successfully removed by abdominal section.

In the varieties of *tubal* pregnancy, rupture of the tube, and death from hæmorrhage usually takes place in the early months, as in the following case:

CASE.—*Tubal Pregnancy, with Rupture of the Fallopian Tube—Hæmorrhage and Death.*

Mrs. C——, aged thirty-three years, four years married, but childless, had been indisposed for two weeks. Early in the morning of July 9th, she was taken with severe pain in the lower abdomen, nausea and vomiting, rapid prostration, increasing tumidity of the abdomen, and death at 7 o'clock P. M.

Thirty-six hours after death, assisted by the attending physicians, Drs. H. J. Sartain and E. Calvin, I made a post-mortem examination. "A quart of bloody serum was sponged out of the abdominal cavity, then a pint and a-half of black coagula was removed, when the pelvic viscera were exposed. The right Fallopian tube was found *enlarged and ruptured*, within an inch of its connection with the uterus. The ovule had lodged in the tube, about half an inch from its outlet, and there formed its attachments. The oozing blood from the ruptured arterioles and venules of the tube, had destroyed the outline of the

embryo, leaving a sort of granular debris lying in the fragments of the membranes, which were detached from the inner surface of the tube. The nidus measured externally about an inch in length, and three-quarters of an inch in transverse diameter. The walls of the uterus were slightly softened, and the decidua had formed."*

Section III. THE OVARIES AND FALLOPIAN TUBES.

[**Notice:** 1. *External Characters* of ovaries; size; color; consistence; soft and boggy, or firm and hard; surface smooth, or rough, irregular and fissured; cysts beneath the surface, or projecting from same. *Characters on section*—color, density; condition of stroma, consistence, etc. Corpora lutea: number, size, situation; cysts; tumors; abscesses; tubercles; cancer, etc. 2. *Fallopian tubes*—absent or malformed; length; size of canal; thickness of walls; condition of fimbriated extremity; tumors, tubercle, cancer, etc.]

1. The Ovaries.

Malformations and Malpositions. The absence or arrest of development of one or both ovaries is occasionally met with.

The ovaries may be found in the labia majora as a congenital defect, or in the inguinal or crural canal, or in the foramen ovale, as congenital or acquired herniæ.

Inflammation is but rarely met with in post-mortem examinations in an isolated form. It generally is associated with affections of the uterus or its appendages, in connection with the puerperal condition. It does, however, occur as an idiopathic disease, and then generally attacks but one ovary. In the congestive stage there is more or less engorgement with blood, even amounting to extravasation, enlargement and softening of the organ.

Abscesses. As a result of acute inflammation, abscesses

* See No. 1476, College Museum.

may form in the substance of the ovary. These may reach considerable size, and may burst into the peritoneal cavity, resulting in death; or they may discharge into the rectum, vagina or bladder, and end in recovery.

Morbid Growths.

Ovarian Tumors or *Ovarian Dropsy*, are generic terms for a class of affections characterized by the formation of cysts, which have a tendency to excessive development. The disease affects married females more frequently than the single, and the age from thirty to forty years is that most subject to it. According to statistics, the right ovary is more frequently the seat of the malady. Various forms of the disease are met with. The cysts may be simple or unilocular, compound or multilocular, or cancerous.

Simple cysts have but a single, undivided cavity, containing fluid, and enclosed within the ovary or external to it. We may find one or more, varying greatly in size, some being no larger than a pin's head or pea, while others contain several gallons of fluid. The contained fluid also, presents great varieties; it may be clear, straw-colored, highly albuminous, or present a viscid, glairy, more or less opaque character; or we may find it of a coffee color, or greenish, with a large quantity of oily matter floating on the surface. In the latter cases the appearance is due, as shown by the microscope, to the presence of blood corpuscles and cholesterine plates.

These simple cysts may acquire an enormous size, filling the abdominal cavity, and crowding the viscera from their position. In a case examined for Dr. B. Berens, in 1855, a free incision was made through what appeared to be the abdominal walls alone, when the cavity was found filled with a straw-colored, slightly gelatinous fluid, of which several gallons were removed.

Upon extending the incisions and looking into the cavity,

it presented the appearance of an entire absence of all the abdominal viscera; the spinal column projected at the posterior portion, while above was seen what appeared to be the concave, under-surface of the diaphragm, with no trace of liver, stomach, or other viscus. A careful examination of the edges of the incision disclosed the divided walls of the cyst, closely adhered to the abdominal parietes at all points. With a little care, these were gradually torn away, when, behind the tumor, was found the atrophied viscera, crowded and displaced upwards and backward into the smallest possible space.

Pilo-cystic or *Dermoid cysts* may be found containing hair and fatty matters. These appear, in many cases, to be the remains of blighted ova enclosed in the body. They are congenital in their origin, and usually contain some fœtal *debris*, such as portions of bone, teeth, etc.

CASE.—*Ovarian Cystic Disease—fatal termination. Autopsy revealing presence of bone and teeth in small cyst.*

The following interesting case occurred in the practice of Dr. William A. Read, of this city, from whom the appended statement has been received:

Miss ——, aged 42 years, after having been treated by several physicians, came under the care of Dr. Read for the treatment of what was diagnosed as an ovarian tumor. Paracentisis was resorted to, with the result of drawing off a considerable quantity of gelatinous fluid, but without any permanent benefit. The disease pursued the usual course, and the patient finally died of exhaustion.

The autopsy revealed a large multilocular tumor, filling a large portion of the abdominal cavity. Upon removing the same from its pelvic attachments, and opening one of the smaller cysts within the broad ligament, the latter was found filled with a quantity of highly offensive fluid, and containing one large, irregular mass of bone, in which were imbedded two well-formed teeth, a smaller piece with one tooth, and nine detached teeth found in the same sac, making twelve in all.*

The first impression upon the discovery of such remains would natu-

* See Nos. 1340 and 1341, College Museum.

rally be, that the case was one of *extra-uterine pregnancy;* but in this instance, the well known character of the lady was such as to preclude such a theory; while the presence of the unbroken hymen was further evidence of virginity. From the impossibility of conception having been the source of the bony and dental remains found in this and similar cases, the problem can only be solved, by supposing that, two ova had been impregnated when this woman was conceived, one of which, in some manner, became imbedded within the other, so that at her birth this lady had within her abdomen the remains of her *undeveloped twin.* These became encapsulated within the pelvis, and finally induced the local disease, which resulted in death.

That this is the correct explanation of such cases, is confirmed by the fact that similar remains have been found within the bodies of males.

Multilocular cysts disclose, instead of a single cavity, numerous chambers, containing secondary, and even tertiary cystic growths, either sessile or pedunculated, and with varying contents.

By the complicated form, we understand that in which, to some other diseased state of the organ—as hypertrophy, fibrous tumors, or carcinomatous growths—the cyst formation is superadded.

Fibrous growths. These are developed in the tissue of the ovary, and present a globular form, with well defined outline. They may attain an enormous size; the largest one on record, occurred in the practice of Dr. Simpson, and weighed fifty-six pounds. We occasionally meet with proofs of a tendency to so-called ossification, in the presence of calcareous matter, into which a portion of the tissue has been converted.

Malignant disease of the ovary, is by no means a rare affection. It is generally limited to one side, and appears as scirrhus, encephaloid, hæmatoid, melanotic, or alveolar cancer, either as an isolated growth, or in the infiltrated form, and generally as an addition to some other morbid formation. It runs a rapid course, although it has been met with even before puberty; forty-one years was the

average age at death according to the statistics collected by Dr. Walshe.

Cartilaginous tumors are extremely rare in the ovaries.

Tubercles are occasionally found as small, cheesy deposits.

2. The Fallopian Tubes.

Congenital Anomalies. One or both of the tubes may be imperfectly developed, in connection with an unsymmetrical development or total absence of the uterus. The tubes may be occluded by the closure of one or both ends, and the point of insertion into the uterus may be abnormal.

Inflammation. Catarrhal inflammation is of not unfrequent occurrence, and may lead to partial or total, temporary or permanent closure of the channel of the tubes. Thus the fimbriated extremities may become agglutinated to the ovaries, the broad ligament, or the uterus itself; or obliteration may occur at one or more points within the passage.

The continued accumulation of the secretion of the mucous membrane will cause distension, either simulating a cyst formation, or presenting the appearance of several saccular dilatations. The dilatations, containing mucus matter of a more or less purulent character, or fluid of an heterogeneous constitution, are rarely of large size, although an instance is on record in which the distension amounted to five inches in diameter. The morbid contents may be poured into the uterus, or in less favorable cases the sac is ruptured, and the contents are effused into the abdominal cavity.

Morbid Growths.

Cysts of small size frequently affect the fimbriated extremities of the tubes.

We may also find *fibroid growths*, *carcinoma* and *tubercle;* the two latter commonly, although not invariably, secondary to similar diseases of the uterus.

Section III. OF THE MAMMÆ.

[**Notice:** 1. *External Characters*—abnormalities; silvery lines on integument, indicating previous enlargement; sinuses; firm, or soft and flabby. *Nipple*—its size, color, retracted? ulcers; excoriations, etc. *Areola*—size and color. 2. *Appearance on section*—color of substance; consistence of gland and fluids exuding; abscesses; tumors; cysts; cancer, etc.]

Anomalies. Supernumerary mammæ, with the power of secreting milk during lactation, have been observed in a number of instances.

The cases of absence of one or both mammæ are rather to be classed as the result of arrest of development or atrophy.

A too early development of the glands in young children is occasionally met with, where there is a precocious development of the organs of generation.

While the mammary glands in the male usually remain in a rudimentary state during life, cases have occurred where they have acquired an increased size, and have been stimulated to such a functional activity as to permit of the suckling of an infant.

Hypertrophy and Atrophy. When puberty occurs, the breasts naturally enlarge and often become tender; and such a temporary enlargement very commonly accompanies menstruation.

An increase of size, such as normally takes place during pregnancy, between the fourth and ninth months, will occasionally commence at puberty, and go on until the organ attains an enormous size. In some cases the breast has been found, after death, to weigh as much as twenty pounds, the tissue being perfectly normal.

Both breasts are usually affected, although one is commonly more so than the other.

After the cessation of the menses, the breasts normally begin to atrophy.

We may also have an atrophy of the breast following upon lobular hypertrophy, as described by Sir A. Cooper.

Inflammation and Abscess. *Inflammation of the Nipple and Areola*, preceding or following a fissured state of the nipple, usually occurs at an early period of lactation, and especially with the first child. Abscess of the areola is often a consequence.

Inflammation of the Breast, generally terminating in suppuration, may occur in three positions: either in the subcutaneous areolar tissue, *supramammary abscess;* or in the areolar tissue, in which the gland is imbedded, *submammary abscess;* or in the gland itself, *mammary abscess.*

Chronic Abscess of the Breast may be of two kinds: the diffused and the circumscribed or encysted. The former may occur at all ages, and in the single as well as in the married. It usually appears in the submammary areolar tissue, and may acquire a very large size; and by pushing the mammary gland before it, gives the breast a pointed, conical shape.

Chronic encysted abscess, so closely simulates various tumors in this situation, as to render a diagnosis in some cases very difficult during life. It usually commences as a result of pregnancy; sometimes as a consequence of lacteal inflammation; but usually without any injury or other direct local cause. An indolent, indurated swelling forms, and this may gradually soften in the centre, although fluctuation may for a long time be very indistinct, and even absent, owing to the thick wall of plastic matter that is thrown around the collection of pus. It is not unfrequently attended with retraction of the nipple.

Syphilitic ulcers are also found affecting the nipple; while eczematous and erysipelatous inflammation in this situation are of frequent occurrence.

Morbid Growths.

The mammæ are frequently the seat of adventitious growths, presenting the characters of non-malignant and malignant formations. The most common of the benignant tumors is, perhaps, the

Adenoid Tumor or Adenocele. This is most frequently met with in young women under thirty years of age, seldom commencing at a later period than forty. It may remain stationary for years, or it may slowly increase or grow very rapidly to a great size. It has frequently been mistaken for cancer, but the otherwise good health of the patient, the mobility of the mass, the absence of all implication of the skin or glands, the want of hardness and its circumscribed character, are points of diagnostic value.

On removal, it appears irregularly lobulated, is encapsulated, and its cut surface has a bluish or grayish-white color, which, on exposure to the air, assumes a rosy tint. On pressure, drops of thick, creamy fluid will often exude. According to Birkett, the microscope shows it to consist of imperfectly developed hypertrophy of the glandular tissue, the terminal cells of which are filled with epithelial scales. This tumor sometimes simulates malignant disease by its extreme rapidity of growth, especially where it developes later in life. It then, after section, presents a lobulated, glistening appearance, somewhat resembling a mass of rice or sago jelly, often having cysts interspersed throughout its substance containing fluid or semi-solid glandular tissue.

In rare cases, the adenocele may return, even after extirpation of the entire mammary gland.

Cystic Tumors. These may occur as the unilocular cyst, or as the cysto-sarcomatous tumor.

Unilocular cysts usually occur as a small, thin sac, of about the size of a filbert, containing a clear, serous fluid, imbedded in the glandular structure of the breast, and movable under the skin. As they increase in size or become multiple, their contents may assume a greenish-brown or blackish tinge from effused blood. According to Brodie, they are originally formed by a dilatation of the lactiferous tubes.

Unilocular cysts occasionally attain an immense size at the same time that their walls remain thin and supple. In some of these instances, the fluid continues to the last, of a truly serous character; while in others, it becomes more or less glairy or mucilaginous.

Sometimes the walls of the cysts have been found to have undergone calcareous degeneration.

The cysto-sarcoma, occurs as an isolated, globular or oval, and more or less movable cyst; or there are numerous growths of this kind, varying in size from a pin's head to a hen's egg. The inner surface is smooth, or it presents a broad-based, lobulated, cauliflower growth or warty excrescences, and the substance of the surrounding gland is indurated and atrophied. A retraction of the nipple may also be observed. A transverse section shows a double sheath; one proper to the cyst, and the other the result of condensation of the adjoining textures. The contents are either fluid, of a limpid, opalescent, non-albuminous, or a grumous, brownish, highly albuminous character; or solid, approaching the character of a fibroid deposit, composed of a pale, compact substance, traversed by undulating fibrous lines, which imperfectly divide it into lobes of various sizes and shapes.

Hydatid cysts, containing the echinococus, occur in the female breast. The tumor is firm to the touch, and contains a clear fluid, in which the microscope detects the tenacula of

the echinococus, the animalculum itself being attached to the internal wall of the cavity.

Fibrous, cartilaginous and *osseous tumors*, are of doubtful or very rare occurrence.

Carcinoma. Cancer affects the mammæ more frequently than any other organ of the body. The age from forty to fifty years seems most liable to its occurrence. According to Dr. Walshe, the left side is more frequently affected than the right, and both are but rarely involved.

All varieties of carcinoma have been met with in the breast; but scirrhus is by far the most frequent form in which it occurs primarily. The encephaloid variety is generally engrafted upon the scirrhus, although it may also be primary. The colloid form is the most rare.

Scirrhus appears as a hard, lobulated tumor, imbedded in the adipose tissue of the gland, causing adhesion to the skin and retraction of the nipple. Although at first movable, it soon becomes firmly adherent to the subadjacent parts, and involves more or less the gland-tissue, the muscles of the thorax, and the adjoining glands. Instead of an isolated tumor, there may be an infiltration of the various structures of the part from the commencement. It will then have an ill-defined outline, sending out branches into the adjacent tissues, and involving in its mass the lacteal tubes and lymphatics. These become contracted and flattened into many bands, giving a peculiar appearance to this form of mammary cancer not observed in any other.

Ulceration of the skin gradually follows near the nipple; the edges of the sore are raised, everted and puckered. The surface is of a bluish-red color. A purulent, ichorous fluid, of a faint, fetid odor, is secreted; hæmorrhage may ensue, and the patient sinks from exhaustion.

The average time occupied by a scirrhus in reaching its full development is from two to three years. When the

ulcerative stage has once begun, the system is soon broken, and the disease proves fatal in from six months to two years. The older the individual is at the first appearance of scirrhus, the more slowly does it pass through the various stages of its growth.

The axillary lympathic glands are also in most cases found swollen, hard, and infiltrated with cancerous matter.

The pectoral muscles, ribs and costal cartilages are also found more or less involved; and a secondary affection of the pleura and lung is not unfrequent. We may also look for œdema of the extremity on the affected side, caused towards the termination of the disease by direct interference with the venous circulation.

The encephaloid form occurs earlier in life, and commonly runs a more rapid course. Its margin is less defined, the base of the tumor being diffused among the healthy cellular membrane, or other parts where it may be situated. It differs from scirrhus also in this: that the disease may advance to ulceration without any affection of the glands of the axilla.

The Male Mammæ.

The structure of the male mammæ resembles that of the female gland, though in a rudimentary state; hence we may find anomalies and morbid conditions in them similar to those found in the latter.

An increased number of mammæ have been met with.

Hypertrophy sometimes occurs.

There have been well authenticated instances of the secretion of milk by men.

The male breast may be the seat of non-malignant and malignant growths. Cancers, simple cysts, compound cysts, and other tumors occur, but exceptionally.

PART IV.

MISCELLANEOUS SUBJECTS.

CHAPTER I.

OF THE PERIOSTEUM AND BONES.

Section I. OF THE PERIOSTEUM.

[**Notice**: degree of vascularity; thickness; density; detached or adhered; effusions beneath; serum or pus; ulcerative destruction of; condition of bone beneath, etc.]

Inflammation of the periosteum occurs in the vicinity of chronic ulcers; as essential to the reproduction of bone after fractures; in consequence of syphilis or its mercurial treatment; in rheumatism; and as a manifestation of a scrofulous cachexia.

In incipient inflammation, the membrane has a reddish tinge, a humid, succulent appearance, and there is more or less of a serous effusion, causing a slight separation from the bone. As the inflammation advances, the connection between the membrane and the bone becomes more lax, and the effusion assumes a purulent character.

Syphilitic inflammation of the periosteum is apt to appear in detached spots, causing swelling, induration, the formation of new osseous matter and necrosis. The periosteum of the skull, sternum and tibia are most frequently attacked.

A malignant disease of the periosteum, the consequence of long-continued or repeated attacks of inflammation, is described by Stanley. It occurs on the bones of the hips,

and gives rise to the growth of a fungous excrescence upon the membrane. "This is sometimes soft and flocculent on its surface, with a firm, grayish, gelatinous base; at others it consists throughout of a firm, gelatinous substance."

Section II. OF THE BONES.

[**Notice:** 1. *Surface of bone*—smooth or rough, firm and hard or soft; periosteum present or destroyed; caries; necrosis; tumors, etc. 2. *Whole bone*—weight and size increased, or diminished? bent or fractured? 3. *Appearance on section*—density of different portions; condition of cancellated portion; destroyed, or softened; abscesses; caries; necrosis; tumors, etc. 4. *Medulla*—density, color, vascularity, morbid growths.]

Inflammation and Abscess. Acute inflammation rarely takes place except in connection with mechanical injury.

Inflammatory processes in bone, give rise for the most part, to an increase of medullary tissue, and to softening of the osseous structure. Haversian canals and medullary spaces increase in size, and ultimately become confluent by the gradual absorption of the surrounding osseous lamellæ. The results of progressive inflammation are congestion, exudation, suppuration, caries and necrosis. An enlargement of the affected portion is invariably met with.

In case the exudation be absorbed, or the inflammatory process be arrested, the parts may return to their normal condition, or the bone retains a permanently disorganized condition, which may present either an increased condensation and induration, as in gouty bone, or an abnormal rarefaction of the bone, as in the bones of rickety individuals.

The same state of rarefaction, or *osteoporosis*, according to Lobstein, is occasionally met with in advanced life, as an effect of mal-nutrition.

Suppuration, with the formation of *abscess*, may be dif-

fused or circumscribed. In circumscribed abscess, we find a cavity generally in or near the epiphyses, lined with a vascular membrane, and thickening of the adjoining periosteum, and of the surrounding cellular tissue.

Caries. Caries, a process of molecular disintegration, may occur in all bones, and in every part of their structure, though it generally affects the cancellous tissue. The carious bone is porous and fragile, of a gray, brown, or blackish color, partly broken down in softened masses, and partly hollowed out into cells, which contain a reddish-brown and oily fluid. Small portions of dead bone lie detached in the carious cavity. The periosteal and medullary membranes, and the bone around the carious portion, will be found extremely vascular, and in many cases, compact masses of osseous tissue are deposited around the carious cavity.

Caries of bone occurs as a result of inflammation, and corresponds to ulceration of the soft tissues. It frequently results from chronic suppurative arthritis, when, from destruction of the articular cartilages, the disease attacks the cancellated structure of the extremity of the bone.

Necrosis. The death of a portion of osseous tissue, or necrosis, although frequently accompanied with caries, is entirely distinct from it. It attacks principally the compact tissue, and is met with, therefore, most frequently in the shafts of long bones. The necrosed portion is of a dirty, yellowish-white color, and has a dull, opaque look; after exposure to the air, it gradually becomes of a green, deep brown, or black tint. Its boundaries are usually distinct, but sometimes are so imperceptibly lost in the healthy tissue, that it becomes difficult in the dead body to determine its exact limits.

Necrosis results from causes which interfere with the nu-

trition of bone, as from suppurative periostitis, traumatic destruction of the periosteum, or osteitis. Ulcerative destruction of the surrounding soft parts, or the diminished vitality attending certain general diseases, as typhus, etc., may also result in necrosis.

The death of a portion of bone is followed by inflammation at the dividing line, which finally results in the separation of the dead portion or sequestrum. This change is soon followed by the production of new bone, in which process the periosteum and medulla may take part.

Rachitis or Rickets, is essentially a disease of malnutrition, most frequently affecting children between the first and third years, although it does also occasionally occur later. The lower extremities are the first to show the effects of the disease, by a curvature commonly referred to too early attempts at walking. A contortion of the bones of the pelvis, of the spine, the thorax, the upper extremities, and malformations of the skull, may follow in the course of the disease.

The bone on analysis, shows a decided diminution in the quantity of phosphate of lime, and a uniform increase of fatty matter; fluoride of calcium always present in healthy born, is also wanting.

The joints are usually swollen, and the epiphyses of the bones enlarged by the exudation of a reddish serum into the enlarged cancelli and canals, the osseous corpuscles, at the same time, showing a deficiency or entire absence of earthy matter. The periosteum is pulpy and thickened, and more than usually adherent to the bone.

If a reparative process have been set up, the deformity may have been greatly diminished, or even entirely removed; or a new deposit of bone taken place, so as to afford a useful limb during life. "This supplementary ossification is found, on vertical section of a long bone, chiefly on

the concave side, so that this part of the shaft may present double and treble the thickness of the opposite side. The structure, at the same time, is very dense, and of ivory texture."

In flat bones, as in those of the skull—which is commonly unduly large in rickety subjects—there is a uniform thickening. In some cases the thickening affects the capacity of the foramina.

In a peculiar form of disease of the cranium described by Elsasser, the bone is atrophied, soft and porous; numerous openings are found along the lambdoidal suture, and in the body of the bone, with the exception of the occipital protuberance. The perforations are filled up only by the dura mater and pericranium, which are adherent to one another. This disease is commonly met with between the third and sixth months of infant life.

Mollities Ossium, or Osteomalacia, is regarded by some as a form of atrophy, by others as identical with rachitis, except that it attacks adults instead of children, and by others as an essentially distinct osseous disease.

It is of rare occurrence, and consists in perverted nutrition of the skeleton, whereby the earthy phosphates are eliminated from the system by the kidneys, while a deposit of fat takes place in the cartilaginous matrix.

As the bones of the trunk are especially liable to be attacked, the individual affected becomes reduced in size by the collapse of the vertebral column.

It attacks females more frequently than males, and the former chiefly after they have commenced child-bearing.

The disease presents two varieties—the *waxy*, in which the bones, especially those of the pelvis, present a dirty, dark-yellow color, and remain greasy after drying; and the *fragile*, where the bones are of a snowy whiteness, and of

a light, transparent, open texture, and so fragile that they give way under the mere pressure of the finger.

Under the microscope, we find the corpuscles and their canaliculi empty and transparent, and only faintly visible, and the Haversian canals unnaturally enlarged.

Morbid Growths.

Enchondromatous Tumors, are usually found in connection with some of the short bones, more particularly those of the fingers and toes, though the ribs, vertebræ, sternum, tibia and femur are sometimes attacked.

They may originate on the surface of the bone, or within the cancellous tissue. In the former case, they exhibit a lobulated arrangement, and are surrounded by a fibrous sheath; in the latter, the bone gradually expands with the development of the tumor. The rapidity and extent of their growth vary. In their microscopic characters, the enchondroma resembles normal cartilage.

The central variety presents a semi-elastic feel, and, on section, the knife passes through a thin, crackling shell of bone, and then exhibits a white, cartilaginous mass, which is occasionally found to contain some small cells; while in some tumors there is an interlacement of fibrous tissue, in which cartilage is imbedded.

The superficial variety is microscopically and chemically identical with the central form, but has no osseous shell. It is met with chiefly in the pelvis, on the cranium, and on the ribs.

There may be a partial ossification.

The disease is chiefly met with in early life.

Osseous Growths, consisting of true bone, are divided into *exostoses* and *osteophytes*. The surface of the former is smooth; their outline generally a segment of a circle or of

an ellipse; their cause: an idiosyncracy of the individual, not referable to any definite constitutional taint. Of the latter, the surface is rough; they do not form any well-defined *local*, circumscribed tumor; are referable to rheumatic or gouty inflammation, to syphilis or other causes.

Exostoses are of two kinds: the one, hard and compact; the other, softer and more spongy. The *hard* or *ivory exostosis* is extremely dense, and whiter than the bone from which it springs, but possesses a true bony structure. It generally grows from flat bones, and is of small size. It has been known to necrose and to slough away from the parts on which it has been situated.

Spongy exostoses often attain a considerable size, and are very commonly multiple. They differ from the compact variety in being composed of cancelli, containing medullary matter, and surrounded by a shell of bone. They spring from the cancellous, or compact tissue of the bone, and their surface is continuous with that of the latter. In some cases the cavity of the exostosis communicates directly, or is continuous, with the medullary cavity of the bone. Their most common seats are the tibia, fibula and humerus.

The *osteophyte* chiefly affects the more vascular portions of bones, as their articular ends, their rough lines, or, in the skull, the sutural cartilages; being generally the product of an inflammatory process in the superficial part of the bone, and in the periosteum.

Fibrous Growths always develop in the cancellous structure. All the long bones and many of the flat bones are liable to this disease. They present more or less elasticity, are of a gray and opaque appearance, and yield gelatin on boiling. They may attain an enormous size.

Cystic Tumors are of rare occurrence, and are generally met with in adults.

They may be unilocular, usually filled with a solid mass of a fibro-cellular or fibro-cartilaginous character; or multilocular, with thin and serous, sero-sanguinolent, viscid or dark-colored contents, often associated with central, fibrous growths.

Hydatid cysts have been met with. According to Stanley, both the acephalocyst and the cysticercus cellulosæ have been found, but more frequently the former.

Tubercles are occasionally present in bone, as the yellow, opaque tubercles, deposited chiefly in the spongy bones and the cancellous portions of long bones. They may soften or become cretified.

Vascular Tumors are of not very frequent occurrence. They are met with most commonly in the cancellous articular ends of the long bones; although they have also been found in the pelvic bones, the bones of the skull, and in the ribs.

In the most frequent class of cases, a new tissue is developed in the osseous structure, and the tumor partakes of an encephaloid character. A creamy, curdy or brain-like, soft, and very vascular mass, is formed as the essential constituent. This will be found to present every shade of transition, from a purely vascular tissue, of an erectile character, to true encephaloid cancer.

In a second, more rare form of disease, there is developed in the bone a *vascular*, *erectile* growth, closely resembling capillary nævus in its structure, composed of an infinity of blood-vessels, interlacing in every possible way, so as to form a soft, reddish-yellow tumor.

In a third form, a hollow cavity is formed in the bone, scooped out of the cancellous structure and filled with blood, partly liquid and partly coagulated, and having arterial branches freely opening into it. According to the stage of

the disease, the blood is found in cells, intersected by fibres, or laminæ and fibres, the remains of the original osseous structure; or in a more advanced stage, in a single cavity. The shell of bone surrounding the cavity is very thin and expanded, being usually absorbed at one point, where it often becomes at last perforated. This last class constitutes *true aneurism* of bone.

Cephalohæmatoma, met with in infancy on the cranial bones, as a result of pressure during parturition, is an effusion of blood between the pericranium and the bone, commonly occurring on one of the parietal bones, most frequently on the right side. Rare cases of internal cephalohæmatoma have been recorded in which the effusion took place between the dura mater and the bones.

Cancer of bone most frequently occurs in the head of the tibia and the lower end of the thigh bone, occasionally in the humerus and in the jaws, more especially about the antrum.

The encephaloid variety is the most frequent. It is of two distinct forms: in the one, the morbid growth is central, springing from the medullary canal; in the other, it is peripheral, being attached to the compact osseous substance.

In the *central* form, it is usually situated at or about the articular ends, but always affects the whole of the bone by infiltration.

In the *peripheral*, the more common form of cancer of the bone, the osseous tissue is not so completely invaded; for although the disease may be located upon, or in intimate contact with the outer layers of the bone, which are incorporated in it, it does not extend into the cancellous tissue or the medullary canal. In this form, the muscles attached to the affected portion of bone will often be found extensively infiltrated with cancer-cells.

Encephaloid of bone is harder and more fibrous looking

than the same affection elsewhere. The cancer-cell also is not so well marked, and may indeed be absent altogether. Occasionally some colloid, and more rarely melanotic matter, is intermixed, but scirrhus is never found in bone.

Of the Medulla.

"It is yet to be determined in how far the medulla is liable to be primarily affected. It varies in consistency according to the vigor of the individual; while in dropsical and phthisical cases we find it thin and serous, or yellow in icterus, or very scanty in ivory condensation of a bone. It exhibits greater firmness, and a richer pink hue, in habits tending to an inflammatory character. The real seat of inflammation in bone is the membrane that lines its cavities. It is, therefore, fair to infer that, in all diseases dependent upon the state of the vascular system, whether of an ordinary or of a malignant character, the medulla is affected coincidently with, if not previously to, the bony tissue itself."

Morbid growths, of various kinds, may be found within the medulla.

The Cysticercus cellulosæ, and Echinococus, are said to have been detected within the medulla and periosteum.

CHAPTER II.

DISEASES OF THE JOINTS.

Malformations. Cases of congenital anchylosis, the joints being absent, have been met with; also imperfectly developed joints, with a partial or total absence of the ligaments. Supernumerary joints also occur, either with the normal, or with an excessive number of bones.

Morbid Conditions of the Synovial Membrane. *Inflammation* may be acute, subacute or chronic. It usually results from exposure to cold, especially in rheumatic or syphilitic constitutions.

There is at first a congestion and increased vascularity of the membrane, and a loss of its satiny polish; the synovia is increased in quantity, but becomes thin and serous, and at a later period, mixed with plastic material. If the disease progress, the vascularity and swelling of the membrane increase, and it becomes turgid and distended with blood and effused fluids; a thin, purulent-looking fluid, composed of granular corpuscles, floating in a serous liquid, is poured out, and disintegration, with thinning and erosion of the cartilage, ensues; or granulations are thrown out on the looser portions of the membrane, and, becoming injected with blood-vessels, form fringed membranous expansions, in contact with the ulcerating part of the cartilage.

In chronic synovitis, the swelling from the accumulated serous fluid may become so considerable as to constitute a true dropsy of the joints—*hydrarthrosis.* This same accumulation may, however, take place without any evidence of preceding inflammation.

Pulpy Degeneration of the Synovial Membrane is peculiar to the articular lining membranes, nothing analogous having

been found in the serous sacs. The reflected portions of the synovial membrane are first attacked, and converted into a light-brown, pulpy substance, from a quarter to a half, or even a whole inch in thickness, intersected with white membranous lines and red spots, formed by small injected vessels. The membrane of the cartilages are then invaded, ulceration in the cartilages going on at same time, till the ulcerating surfaces of the bone are exposed.

The disease almost always occurs before the middle period of life, frequently can be traced to no cause, but is occasionally the consequence of repeated attacks of inflammation. It generally occurs in the knee, but has been met with in the ankle and in a joint of the finger.

A growth of large villous processes, presenting a shaggy appearance, is sometimes observed. "They have sometimes the form of simple threads or flattened shreds, or their free extremities are split into filaments or have a club shape, or resemble melon-seeds hanging singly, or in clusters from each stalk. In many cases, the healthy texture of the articulation is not materially affected."

Morbid Conditions of Bursæ. "These small synovial sacs are liable to be affected much in the same way as larger ones. They may be attacked by inflammation more or less acute or quite chronic, resulting from rheumatism, the abuse of mercury, or some other constitutional affection; or excited by violence or long-continued pressure. The effusion which takes place may, in cases of a chronic kind, be a simple synovial or serous fluid; but when the inflammation is more acute, it is either a turbid serum, with flakes of fibrinous matter floating in it, or actual pus." The walls of an inflamed bursa sometimes become very much thickened by the organization of layers of fibrinous effusion.

In cases of long-standing inflammation, flat oval bodies, resembling melon-seeds, of a light-brown color, are not unfre-

quently met with. Their origin is no doubt to be traced to the coagulated lymph effused in the beginning of the disease.

In the synovial sheaths surrounding the flexor tendons of the fingers, as they pass under the annular ligament, small bodies, resembling grains of boiled rice, are also occasionally found.

The so-called *ganglions* are small collections of fluid in bursal cavities of new formation, and occur principally on the back of the wrist and forearm. In the sheaths of the tendons of the hand, these synovial accumulations may become so excessive, as to greatly damage the usefulness of the member.

Morbid Conditions of Cartilage. The thickness of cartilage may be greatly increased, while the tissue becomes soft and yielding. In advanced age, the articular cartilages become considerably thinned; ossification of the cartilage occurs, sometimes gradually with advancing years, at others in connection with chronic rheumatic arthritis. In joints apparently not diseased, we sometimes find the cartilages more or less deficient at one or more points, due to pressure and consequent partial atrophy. Sometimes its place is taken by a hard, semi-transparent substance of a gray color, with an irregular granulated surface, the result of a fibrinous exudation.

The free surface of cartilages is occasionally found covered with a thin layer of lithate of soda, as the result of gout.

Loose cartilages may be found in the knee and other large joints; they never contain any of the characteristic cells of cartilage, and appear to consist solely of compressed fibrillating exudation. They vary in size and number, are more or less oval and flattened, with a smooth surface, and are sometimes attached to the synovial membrane by a pedicle of varying length. In the latter case, they are invested by a serous covering. Calcareous deposits are occasionally met with in them.

Ulceration of Cartilage may occur as an acute or subacute affection. The cartilage corpuscles, instead of being of their usual form, will be found larger, rounded or oviform; and instead of two or three nucleated cells in their interior, they contain a mass of them. The cavities of the enlarged corpuscles open on the ulcerated surface, by orifices of various sizes. The texture of the ulcerating cartilage, shows no trace of vascularity. In most cases, a vascular false membrane is found in opposition to the diseased part. The membrane generally adheres with some firmness to the ulcerating surface, in other instances it is loosely applied to it; but in all cases the two surfaces are accurately moulded to each other. If a portion of the false membrane be torn slowly off, the cartilage will be found to be rough and honeycombed, and into each depression on its surface, a nipple-like projection of the vascular membrane will be seen to have penetrated.

Chronic Rheumatic Arthritis is very frequent in the hip, the shoulder, the knee, and the articulations of the hand. The process consists essentially, first, in an hypertrophy of the articular cartilage, generally at the margin, and principally near to the articular surface. Secondly, in the development of true osseous tissue in the hypertrophied cartilage. We will, therefore, find irregular enlargement of the articulating head of the bone; an absence of the articular cartilages, or new osseous growths surrounding their margins; and the synovial sacs presenting evidences of having been the seat of chronic inflammation.

Scrofulous Arthritis, or *White Swelling*, attacks primarily the articular extremities of the bones. They become very vascular and softened, so that they can be readily cut with a knife, while a characteristic transparent and afterwards a yellow, cheesy substance is deposited in their cancelli. As

the disease advances, the cartilage ulcerates, and the osseous tissue gradually wastes and undergoes a true caries. Abscess forms in the joint, and finds its way by ulceration to the external surface, causing numerous and circuitous sinuses in the neighboring soft parts.

In some cases, the disease may commence in the synovial membrane, extending finally to the cartilages and ultimately to the bone.

The disease affects principally the joints of children, and rarely occurs after the age of thirty. The existence of scrofulous disease in other parts, and the deposition of the yellow, cheesy matter within the cancelli, will serve to distinguish this disease from simple caries, resulting from inflammation.

Disease of the Spinal Column. The joints of the vertebræ are liable to nearly the same affections as more perfectly developed articulations.

The scrofulous disease just described may attack the cancellous tissue, causing caries and the deposition of cheesy matter. The first effects are generally perceptible where the intervertebral cartilage is connected with the bone, or in the intervertebral cartilage itself, although ulceration may commence on any part of the surface, or even in the centre of the bone. In some cases, of rarer occurrence, the bodies of the vertebræ are affected with chronic inflammation, with ulceration of the intervertebral cartilages as the consequence.

If not checked, the disease proceeds to the destruction of the bodies of the vertebræ and of the intervertebral cartilages, leaving the posterior parts of the vertebræ unaffected. The necessary consequence is a curvature of the spine forward, and a projection of the spinous processes posteriorly.

Chronic inflammation of the bones sometimes extends to the membranes of the spinal cord; and when the curvature is very great, the cord may be so compressed that it cannot properly discharge its functions." Suppuration

may take place at different stages of the disease, sometimes earlier, sometimes later. "The soft parts in the neighborhood of the abscess become thickened and consolidated, forming a thick capsule, in which the abscess is sometimes retained for several successive years; but from which it ultimately makes its way to the surface, presenting itself in one or another situation, according to circumstances. In the advanced stages of the disease, new bone is often deposited in irregular masses on the surface of the bodies of the neighboring vertebræ; and where recovery takes place, the carious surface of the vertebræ above, coming in contact with that of the vertebræ below, they become united with each other, at first by soft substance, afterwards by bony anchylosis."

Where the bones are affected by scrofula, bony anchylosis does not so readily take place as where they retain their natural texture and hardness. Occasionally, portions of the ulcerated or carious bone lose their vitality, and having become detached, are found lying loose in the cavity of the abscess. The pressure of a large abscess on the surfaces of the contiguous vertebræ may cause an extensive caries far beyond the limits of the original disease.

CHAPTER III.

OF TUMORS.

In giving a brief description of tumors, the following classification has been adopted from Gross, as presenting the most practical and convenient arrangement of the subject:

I. *Benign or Non-Malignant Tumors.*

1. Cystic Tumors.
   - *a.* Simple Cysts; including Serous, Mucous, Synovial, Colloid, Sanguineous, Salivary, Milk, Oil, Seminal, and Dermoid Cysts.
   - *b.* Compound or Proliferous Cysts.
2. Hydatid Tumors.
3. Myxomatous "
4. Lipomatous "
5. Fibrous "
6. Cartilaginous "
7. Osseous "
8. Papillary "
9. Polypoid Tumors.
10. Myomatous "
11. Vascular "
12. Neuromatous "
13. Adenoid "
14. Lymphatic "

II. *Malignant Tumors.*

1. Sarcomatous Tumors.
   - *a.* The Round Celled.
   - *b.* The Spindle Celled.
   - *c.* The Giant Celled.
2. Carcinomatous Tumors.
   - *a.* Scirrhus Tumors.
   - *b.* Encephaloid "
   - *c.* Melanotic "
   - *d.* Colloid Tumors.
   - *e.* Epithelial "

I. Benign or Non-Malignant Tumors.

1. **Cystic Tumors.** These are of very frequent occurrence, and may acquire an extraordinary size. Their struc-

ture may be simple or very complex, and we may accordingly divide them into simple or barren, and compound or proliferous cysts. They may be new formations or, as in most cases, merely hypertrophies. They occur in nearly every organ and tissue of the body, but are most frequently met with in the skin and mucous membranes, the glandular organs, and in the subcutaneous cellular tissue.

A. *Simple Cysts* generally consist of a thin sac or cyst filled with contents, varying according to the structure and function of the affected part. The cyst itself may be solitary or multiple, generally composed of a single layer, its external surface being rough and adherent to the surrounding tissues, while the internal surface is shining or glossy, and in immediate but loose contact with the contents of the tumor.

According to the nature of their contents, we may find the following varieties of simple cysts:

Serous Cysts. Their contents are generally of a thin, watery character, slightly saline in taste, and consisting largely of albuminous material. The walls are thin, and at first translucent; as they grow older they become thicker and denser.

Mucous Cysts generally contain a thick, ropy, glutinous material, intermixed with epithelial matter. Sometimes the contents are thin and clear; occasionally they resemble the fluid contained in a synovial bursa. Such tumors occur chiefly in connection with the mucous membranes, are generally spherical or pyriform in shape, and may attain the size of a fœtal head.

Synovial Cysts are generally small in size, rounded, globular, or hemi-spherical in shape, with contents of a serous, mucus, glutinous, colloid, or of a jelly-like consistence, and of a whitish, opaque appearance. They occur generally in the synovial sheaths of the tendons of the wrist, and on the front of the patella. The most characteristic types of synovial cysts are those known as ganglions and bursæ.

"The inner surface of the parasite is studded with numerous little bodies, resembling diminutive fish-spawn, hardly as large as a grain of sand, of a spherical shape and of a grayish color, each consisting of a delicate cyst, filled with echinococci."

"Each echinococcus consists of a body and a head, the latter being encircled by a row of teeth, naturally concealed in a narrow cleft, but capable of projecting itself. The body, composed of solid, granular matter, has a curiously speckled appearance, due to the presence of numerous ovoid spots immediately beneath its outer coat. The teeth, or hooklets, are spinous, sharp, and perfectly characteristic."

3. **Myxomatous Tumors.** The *Myxomata* or mucous tumor, consists of mucous tissue, a translucent and succulent connective tissue, the intercellular substance of which yields mucin. Their characteristic features are elasticity and softness; the older growths, however, are harder than the more recent ones. They are of a pale, greyish or reddish-white color. They consist of a basement structure, the proper stroma of the tumor, and an intercellular substance, pervaded by distinctly visible blood-vessels. On being cut, they yield, on pressure, the tenacious, mucilaginous, intercellular liquid, in which may be seen the cellular elements of the growth. The majority of the cells, under the microscope, are found to be angular and stellate, with long, anastomosing prolongations and trabeculæ. Others are isolated and fusiform, oval or spherical in shape. They usually possess one, in some cases two distinct nuclei. Fat cells, fibrous tissue, both white and elastic, and cartilage in varying proportions, are often met with in the morbid mass.

They occur chiefly in the subcutaneous and intermuscular cellular tissues, in the mucous cavities, in the hilus of the kidney, and in the nerves and bones. When situated in superficial parts they may become pedunculated. In the

jority of cases, contain the debris of a blighted ovum, such as hairs, teeth and bone. Sebaceous tumors are a variety of dermoid cysts, and contain sebaceous matter, combined with epithelium and even hair, oil or fat.

B. *Compound or Proliferous Cysts* are "characterized by the existence of subordinate cysts, occupied by different organized substances, and giving rise to that peculiar arrangement known as multilocular or polycystic, generally so conspicuous in this class of tumors." When a number of cysts are crowded together, their walls are frequently absorbed, and irregular cavities, varying in size and shape, are thus formed. Their contents are of the most diversified character. The cyst wall is thin at first, but becomes thicker and firmer in a later stage.

Proliferous cysts sometimes take on a malignant character, of the encephaloid or epithelial type, years after their origin. They occur most frequently in the ovary, the mammæ, and the thyroid gland. In the first situation, they not unfrequently attain an enormous size.

2. **Hydatid Tumors.** These tumors occur most frequently in the liver, ovary and uterus. They consist of a distinct sac, enclosing an entozoon, parasite or vesicular worm, "varying in volume between a mustard-seed and a small orange. The entozoon is of a globular figure, of a whitish, semi-opaque appearance, and composed of a vesicle or bladder, filled with serous fluid, and surrounded by a cellulo-fibrous capsule." Generally a number of them are found in a common cyst. "The contents of the animal are of a clear, limpid character, remarkably saline to the taste, but destitute of odor and coagulability. Between the cyst and the parasite there is commonly a soft, pulpy, dirty-looking substance, the precise nature of which is undetermined. Large hydatids sometimes contain several smaller ones, one within the other."

elevations and depressions. They feel heavy and incompressible. Near a free surface they are prone to become pedunculated. They may attain a very great size. Their vascularity is in proportion to the density of their structure, some having but few vessels, while others are highly vascular. A distinct capsule is but seldom met with, although the tissues around the tumors will usually be found a great deal condensed and thickened.

They consist essentially of fibres, resembling those of areolar tissue. "Sometimes the fibres are tolerably distinct and separate, more often so interlaced and blended together, or so imperfectly evolved that they cannot be made out as such. Yellow elastic fibres are not unfrequently mingled with the white."

Growths of this kind are not, in general, liable to any great degree of change. Inflammation, with injection and softening of the part may take place. Cretification may occur, by which either the whole tumor may be converted into a calcareous mass, or only the outer stratum surrounding the rest as a kind of shell.

6. **Cartilaginous Tumors.** The *Enchondromata*, histologically resemble cartilage, and like it consist of cells and an intercellular substance, presenting all the variations observed in the normal tissue. The intercellular substance may be hyaline, fibrous, or mucoid, or as most frequently is the case, all combined. The cells are round, oval, spindle-shaped or stellate, and may be very numerous, or few in proportion to the matrix. They enclose one or more nuclei, and slightly granular contents; sometimes a cell-wall cannot be distinguished.

In addition to the intercellular tissue, the growth is usually divided into several lobes by bands of fibrous tissue. The fibrous tissue in most cases, forms a capsule around the tumor, and separates it from the surrounding structures.

The enchondroma is met with most frequently in early life, and occurs chiefly in connection with the osseous system, principally the metacarpal bones, and phalanges of the fingers, where it may grow either from the periosteum or from the medulla. It is met with also in the parotid and submaxillary glands, in the testicle, mammæ and ovary, and occasionally in the subcutaneous and intermuscular cellular tissue.

They may attain an enormous size. "To the hand, it imparts the sensation of unusual firmness and solidity; it is destitute of elasticity, is generally distinctly circumscribed, and is nearly always strongly adherent to the tissues from which it springs."

Calcification and ossification of these tumors may occur. In rare cases, the skin covering the tumor ulcerates, and a fungating mass protrudes.

Although in general an innocent growth, the enchondroma in some instances, assumes a malignant form, and recurs after extirpation.

7. **Osseous Tumors.** The *Osteomata* are tumors consisting of osseous tissue, met with chiefly as outgrowths of the skeleton, especially of the external and internal surfaces of the skull, and of the thigh bone.

There are three classes, the soft, spongy or cancellous, the compact, and the eburnated osteoma.

The *spongy*, which is the most common, consists of cancellous osseous tissue. The medullary spaces may contain embryonic tissue, a fibrillated tissue, or fat. "In its earlier stages, it is often invested by a layer of cartilage, of a greenish, whitish, slightly bluish, or pearly aspect, and of a hyaline character. Sometimes it is enclosed by a thin, fibrous, or fibro-cellular capsule, a form of synovial bursa, lubricated by serous or sero-oleaginous fluid."

The *compact osteoma* is generally more or less rounded,

with a nodulated surface, and a broad base. It is of a firm, bony consistence, and resembles, as nearly as possible in structure, the compact tissue of the long bones, differing only in the arrangement of the Haversian canals and canaliculi, which is less regular than in normal bone.

The *eburnated osteoma* consists of dense osseous tissue. The lamellæ are arranged concentrically and parallel to the surface of the tumor. Blood-vessels and cancellous tissue are both absent. The tumor is of small size, rounded, globular or hemi-spherical in shape, and generally smooth, or slightly nodulated.

8. **Papillary Tumors.** The *Papillomata* resemble in structure ordinary papillæ, and like these grow from cutaneous and mucous surfaces.

They consist of a basis of connective tissue, supporting blood-vessels, which terminate in a capillary net-work, or in a single capillary loop, the whole being enveloped in a covering of epithelium, varying in character according to the surface from which the new formation springs. These growths are sometimes very vascular.

On the skin we may have these growths as *warts* and *horny* growths. These are commonly firm, with a dense epithelial covering, and are less liable to ulceration and hæmorrhage, than those growing on other parts. But we have, in the *condylomata* and *venereal warts*, occurring around the anus and upon the external male and female genital organs, instances of larger and more vascular forms on cutaneous surfaces.

On the mucous membranes, the papillomata are softer and more vascular, and have a less dense epithelial covering. Many of them constitute so-called mucous polypi. They are met with on the tongue, in the larynx and nose, in the gastro-intestinal mucous membrane, on the cervix uteri, and in the bladder.

9. **Polypoid Tumors.** These growths occur exclusively in the mucous cavities of the body, and may attain a large size.

They occur most frequently in the nose and the uterus, but are also met with in the ear, maxillary sinus, vagina and rectum, while their presence in the larynx and throat is exceedingly rare.

They are usually solitary, varying in size and shape according to the locality which they occupy.

Four varieties are met with, differing essentially in their structure.

The *gelatinoid polypus*, the most common of all, occurs almost exclusively in the nose. It is of a jelly-like appearance, irregularly pyriform in shape, with a narrow pedicle, sometimes nearly an inch in length. It is nourished by a few straggling vessels, which are often of considerable length and thickness.

The structure of the *fibrous polypus* is exceedingly dense and composed of fibres, interlacing with each other in all directions. It is tough, hard and incompressible; of a reddish, purple or livid hue. It is nearly always solitary, may attain a large size, and is usually attached firmly by a broad base, and not by a pedicle. The uterus, nose and maxillary sinus, are its most common sites.

The *granular polypus*, is of rare occurrence. It is met with chiefly in the uterus and in the ear. It is generally small, of a pale, greyish, or whitish color, soft and fragile in consistence, and globular, conical, or ovoidal in shape. Its structure is granular, homogeneous and inelastic.

The *vascular polypus*, attached usually by a narrow base, is of a florid color, of a soft consistence, and not very large in size. On section we find numerous vessels interspersed throughout a fibro-cellular tissue.

Carcinomatous disease is more liable to supervene in the case of the fibrous growths, than in the other of these formations.

10. **Myomatous Tumors.** The *Myomata* are tumors consisting of muscular tissue, either of the striated, or non-striated variety. The former are exceedingly rare and generally congenital, the latter are quite frequent and are never congenital; but occur principally in elderly subjects.

They are met with most frequently in the uterus, where they sometimes attain an immense size. They form either distinctly circumscribed tumors of a globular, conical, or pyriform shape, or ill-defined masses in the uterine walls. When projecting into the cavity of the uterus, or into the abdominal cavity, they assume the shape of polypi, with a narrow pedicle.

Myomata may also occur in the prostate gland, in the œsophagus, stomach and intestines.

"In structure they consist of elongated spindle-shaped cells, more or less isolated, or grouped into fasciculi of various sizes, with a varying amount of connective tissue."

Maceration with dilute nitric acid, is often necessary in order to isolate and display the muscular elements.

11. **Vascular Tumors.** The *Angiomata* are tumors consisting of blood-vessels, held together by a small amount of connective tissue. They include the various forms of nævi, the erectile tumors, and aneurism by anastomosis.

They are generally met with as congenital affections. Their ordinary sites are the skin and mucous membranes, especially about the head, face and tongue.

They are soft and spongy, easily compressible, and very elastic, varying in color according to the nature of their contents, whether venous or arterial, or both combined.

12. **Neuromatous Tumors.** True *Neuromata* are tumors consisting almost entirely of nerve tissue. The term has also been applied to growths of other kinds, found in connection with nerves; these are false or spurious neuro-

mata. True neuromata are of very rare occurrence. They consist mainly of a new growth of nerve fibres. "They resemble in structure the cerebro-spinal nerves, consisting of tubular fibres, with a varying quantity of intertubular connective tissue, and in some cases a few gray, gelatinous fibres." They usually exist as small, single nodules, solid to the touch, firm, inelastic, and developed within the neurilemma of the affected nerve.

The most frequent seat of these growths is the extremities of divided nerves, where they sometimes occur after amputation. They may also exist in the course of the nerves, in any situation, singly, or in great numbers.

13. **Adenoid Tumors.** The *Adenomata* are new formations of gland tissue, resembling in structure the racemose, or tubular glands. "They consist of numerous small saccules or tubes filled with squamous or cylindrical epithelial cells. These are grouped together, being merely separated by a small, though varying amount of connective tissue, in which are contained the blood-vessels." They are essentially local hyperplasias. The new growth may remain in intimate relation with the adjacent gland, or it may gradually become separated from it by the formation of a fibrous capsule.

The adenoma is usually a solitary tumor, of a firm, dense, inelastic consistence, of a whitish, grayish, or pale straw color, seldom larger than a hickory-nut. On section, the cut surface has a glistening appearance, and in recent cases never yields any fluid on pressure.

It occurs in the mammary, thyroid, prostate, and parotid glands, and in the mucous follicles. In mucous surfaces, it gradually projects above the surface of the membrane, so as to form a polypus, and thus constitute the most common form of mucous polypus.

14. **Lymphatic Tumors.** "The *Lymphomata* are new

formations consisting of lymphatic, or as it is more commonly called, *adenoid* tissue. This tissue consists essentially of a delicate reticulum, within the meshes of which are contained the so-called lymph corpuscles. The reticulum is made up of very fine fibrils, which form a close net-work, the meshes of which are only sufficiently large to enclose a few, or even a single corpuscle in each. The fibrils usually present a more or less homogeneous appearance, and amongst them there are a few scattered nuclei."

The lymphatic tumor is most frequently met with in the lymphatic glands of the neck, axilla, groin, and mesentery, and usually consists of several enlarged glands, fused into one common mass of variable size, shape, and consistence. The sectional surface is of a grayish, light pink, or reddish-yellow color, and yields on pressure a whitish, lactescent juice, not unlike that of certain forms of carcinoma, containing cells with one or more nuclei.

II. Malignant Tumors.

1. **Sarcomatous Tumors.** The *Sarcomata* are tumors consisting of embryonic connective tissue. This differs from the fully developed tissue, in consisting almost entirely of cells, which are also larger and rounder than those of mature tissue. Its intercellular substance, instead of being fibrous, is soft and amorphous or only obscurely fibrillated.

The cells of sarcoma are round, spindle-shaped or stellate, and exist either separately or in conjunction in the same tumor. The latter is most frequently the case; but one form generally predominates, and according to the preponderance of one or the other kind of cell, these tumors can be most conveniently classified as round-celled, spindle-celled, and giant-celled sarcomata.

Round cells are found in all sarcomata, and are often very small, scarcely distinguishable from lymphatic cells, or white

blood corpuscles. Others are larger, and contain an indistinct nucleus, with one or more bright nuclei.

The fusiform or spindle-shaped cells are the so-called fibro-plastic cells. They are long, dimly granular, pale bodies, terminating at each end in a fine prolongation. They are slightly granular, and enclose a long, oval nucleus, with or without nucleoli. In size they vary.

The giant or mother cells are the largest of human cells, irregular in shape, though usually more or less spherical. They are finely granular, and contain numerous round or oval nuclei, each with one or more bright nucleoli.

The intercellular substance exists usually in small quantities. "It may be perfectly fluid and homogeneous, or firmer and granular, or, less frequently, more or less fibrillated. Chemically, it yields albumen, gelatin and mucin."

These growths may occur at any period of life, but are most frequently met with between the twentieth and fortieth year. It is most common in the skin and subcutaneous and intermuscular connective tissues of the extremities. The periosteum and bones, particularly the epiphyses of the long bones and the maxillæ, the female breast, the testicles, and the eye, are also liable to be attacked.

They usually arise as nodules, single or multiple, firm or soft, and often attain an enormous size by their characteristic rapidity of growth. They are liable to fatty degeneration, with the production of cyst-like cavities. Calcification, ossification and mucoid degeneration are also common.

Sarcomata are decidedly malignant, and are characterized by their rapid growth, their great tendency to extend locally, and to recur after removal, and by their power of reproducing themselves in internal organs.

The *Round-celled Sarcoma*, called also from its resemblance in many cases to encephaloid, *medullary*, *encephaloid* or *soft* sarcoma, is of a uniform, soft, brain-like consistence, and of a somewhat translucent, greyish, or reddish-white

color. The sectional surface, on being scraped, yields a juice rich in cells. It is exceedingly vascular, with the vessels often dilated and varicose. "It can be distinguished from encephaloid cancer by the absence of a fibrous stroma, by the uniformity in the character of its cells, and by the absence of any invasion of the surrounding structure in their growth other than the connective tissue from which they grow."

The *Spindle-celled Sarcoma*, called also the fibro-plastic and recurring fibroid, is most closely allied to the fibroma. It consists essentially of fusiform cells, with well-marked nuclei and thin processes, sometimes split at the end. They are nearly in close contact, there being but little intercellular substance. The cells are parallel and arranged in bundles, which pass in all directions through the growth. "When cut, this sarcoma grates under the knife, and the surface exhibits a firm, tough, greyish or pale-yellowish appearance, similar to that of ordinary fibrous growth. After removal, they are softer and more succulent when they recur."

They grow from the periosteum, the fasciæ, and from the connective tissue in other parts. They are more frequently enclosed in a capsule than the other varieties.

The *Giant-celled Sarcoma*, called also the *myeloid* sarcoma, most frequently occurs in connection with bone. They consist of large, many nucleated cells, mingled with round or spindle forms, nearly in contact, there being but a sparse intercellular substance. On section, the surface appears smooth, compact, shining, greyish-white or greenish, with blotches of a dark crimson, brownish or pink hue.

The giant-celled sarcoma is not a benign affection, but is the least malignant of the sarcomas.

2. **Carcinomatous Tumors.** "The *Carcinomata* are new formations, consisting of cells of an epithelial type, without any intercellular substance, grouped together ir-

regularly within the alveoli of a fibrous stroma. The cells are characterized by their large size, by the diversity of their forms, and by the magnitude and prominence of their nuclei and nucleoli. In size they vary from $\frac{1}{600}$ to $\frac{1}{1500}$ of an inch in diameter, the majority being about five times as large as a red blood-corpuscle. They are round, oval, fusiform, caudate, polygonal—exhibiting, in short, every diversity of outline. The nuclei, which are large and prominent, are round or oval in shape, and contain one or more bright nucleoli." There is generally but a single nucleus, two, however, are often met with, and they are even still more numerous in the soft varieties of cancer.

The stroma varies in amount. It consists of a fibrillated tissue, forming by their peculiar arrangement, alveoli of various sizes and shapes, in which the cells are grouped. The stroma varies in character according to the rapidity of its growth. Where its growth is rapid, it will contain numerous round and spindle-shaped cells; where it is slow, or has ceased altogether, the tissue will contain but few cells, and will be dense and fibrous in character. The latter condition is most frequently met with.

The blood-vessels are sometimes very numerous, and are always limited to the stroma, and never encroach upon the alveoli. This serves to distinguish the carcinomata from the sarcomata, since in the latter the blood-vessels ramify amongst the cells of the growth.

The carcinomata also possess lymphatics, and it is owing to this that the lymphatic glands are so constantly involved in the disease.

Cancers very rarely become encapsuled, but generally invade the surrounding structures. The epithelial elements are found infiltrating the tissues for some distance around the tumor, so that there is no line of demarcation between it and the normal structures.

Carcinomatous tumors are liable to certain alterations and transformations, like other morbid growths.

Fatty degeneration is the most common of these. This occurs to a greater or less extent in all the varieties of cancer. It produces softening of the growth, which is often reduced to a pulpy, cream-like consistence.

Calcareous degeneration has been occasionally met with in encephaloid, and in carcinoma invading bone.

Inflammation, softening, and consequent ulceration, are not unfrequent.

The varieties of carcinomata are :

(*a.*) *Scirrhus.* Scirrhus, fibrous, hard or chronic cancer, seldom occurs before middle age, and more frequently in the female than male.

The liver, mammæ and uterus, are particularly liable to be attacked. It also occurs in the alimentary canal, and in the skin.

Scirrhus is characterized by the large amount of its stroma, and its slow growth. The tumor is firm, hard and inelastic, of variable shape, and is often depressed in the centre, owing to the contraction of the cicatricial tissue.

On section, especially in the more matured stages, the tumor exhibits a whitish, glistening aspect, intersected with fibrous bands, the remains of normal tissue, changed by disease. It yields on being scraped, a peculiar fluid, the so-called cancer juice, generally of a pale, grayish, turbid appearance, rich in cells, nuclei and granules, sometimes of a whitish, creamy hue. This juice is evidently the result of disintegration, and is hence but sparingly present in recent specimens. It readily mixes with water, and often contains a quantity of free oil.

Scirrhus has but few blood-vessels. Nerves and lymphatics also exist. It has a tendency to ulcerate, and to contract adhesions with the structures surrounding it. The lymphatic glands are also liable to be infected, by the con-

veying of cancer elements to them through the lymphatic vessels situated in the scirrhus mass.

(*b.*) *Encephaloid.* Encephaloid, medullary, soft or acute cancer, differs from the preceding, in the small amount of stroma, the consequent softness of consistence, and its rapid growth.

It is most common in the mammæ, eye, testicle, uterus, liver, lymphatic glands, periosteum and bones. The greatest number of cases occur between the twentieth and fiftieth years.

The cells are exactly similar to those of scirrhus, but far more numerous, while the stroma is not so well marked, and much less fibrous, and does not undergo a similar cicatricial contraction.

Blood-vessels are very abundant.

The tumor varies in size from a pea to that of an adult's head, its shape being generally ovoidal, and its surface more or less lobulated. "It is of a soft, brain-like consistence, the central portions, where fatty degeneration is most advanced, often being completely diffluent. On section, it presents a white, pulpy mass, much resembling brain substance, which is often irregularly stained with extravasated blood."

Occasionally these tumors contain serous cysts of small size, as well as other adventitious products. When ulceration takes place, the sore is characteristic. "Its edges are thin, undermined, jagged, or irregular, while its bottom has a foul, bloody, fungous appearance. The parts around are of a deep red, livid, or purple color."

(*c.*) *Melanosis.* Melanotic, or black cancer, is probably merely the result of a pigmentation of the encephaloid. It occurs most frequently in the eye and skin, and is occasionally met with in the viscera. The melanotic matter occurs in small masses, of a rounded, ovoidal, or irregular shape, with or without a cyst, from the size of a pin's head

CHAPTER IV.

POST-MORTEM APPEARANCES IN DEATH FROM UNNATURAL CAUSES.

1. Death from Poisoning.

In speaking of the lesions produced by poisoning, we will confine our attention to the more common poisonous substances which are given, or taken, either intentionally or by accident, and which may result in death.

Sulphuric Acid. Death from poisoning with this acid, commonly results in from twelve hours to three days, but sometimes life is prolonged for a week or a fortnight, or for months, and sometimes death may take place in an hour.

The morbid appearances met with will vary according to the quantity of the acid taken, and the manner of its administration. The appearances are in general as follows:

On the lips, fingers, or other parts of the skin, spots and streaks of a brownish, or yellowish-brown color are met with, where the acid has disorganized the cuticle.

The mucous membrane of the tongue and fauces is white; the pharynx is only in the rarest cases carbonized like the stomach, is generally hard to cut, as if tanned, and of a gray color; the vascular injections of its mucous membrane may be recognized.

The rima glottidis is sometimes contracted, the epiglottis swelled, and the commencement of the larynx inflamed. The œsophageal membrane is often completely detached, or comes off in shreds, and the passage shows traces of the corroding effects of the poison.

The outer surface of the abdominal viscera is commonly either very vascular or livid.

The stomach, if not perforated, is commonly distended with gases, and contains a quantity of yellowish-brown or black matter, and is sometimes lined with a thick paste, composed of disorganized tissue, blood and mucus. The pylorus is contracted. If the acid has been taken diluted, the mucous membrane is merely excessively injected, with blackness of the vessels, and usually a softening of the rugæ, or actual removal of the villous coat.

If the stomach be perforated, the holes are commonly roundish, with thin, colored and disintegrated margins, and surrounded by vascularity and black extravasations. The inner coat of the duodenum often presents appearances closely resembling those noticed in the stomach. Sometimes, especially in cases which are rapidly fatal, it is not at all affected, probably owing to the spasmodic contraction of the pyloric orifice.

The urinary bladder is commonly empty.

The blood is thickened, and of an acid reaction.

Nitric Acid. The appearances observed in cases of poisoning by this acid, are similar to those noticed under sulphuric acid. A difference of tint in the color produced by nitric acid on the skin, lips and mucous lining of the mouth and œsophagus, being the only distinguishing mark. Whereas in the case of sulphuric acid the color is brownish, in the case of nitric acid, it is most frequently yellow.

Oxalic Acid. This is a poison of great energy, and so more frequently used for committing suicide than for purposes of murder. It has often been taken by accident for Epsom salt, (sulphate of magnesia,) which it greatly resembles in general appearance.

It is the most rapid and unerring of all the common poisons, and produces death generally within an hour, although a large dose may prove fatal in two or three

minutes, and a smaller one may be survived for as long as twenty-three days.

The mucous membrane of the throat and œsophagus look as if scalded, and can easily be scraped off. The stomach contains a thick fluid, commonly dark, like coffee-grounds. The inner coat of the stomach is pulpy, in some points black, in others red.

The mucous membrane of the intestines is usually similarly, but less violently affected. In some cases, the stomach and intestines have been found healthy.

Phosphorus. This substance has frequently, in the form of heads of lucifer matches, been the cause of death; more frequently taken by accident, or with the intention of committing suicide, than with the design of destroying the lives of others.

The symptoms of phosphorus poisoning vary during life, and after death the morbid appearances are not constant, depending much upon the length of time that has elapsed before death.

In cases which have proved rapidly fatal, the main appearances are those of irritation, somewhat similar to those already described, and due to the direct action of the poison. In more protracted cases there is generally jaundice, the blood is found in a state of complete fluidity, non-coagulable, and with very few corpuscles, while ecchymoses and sanguineous effusions appear everywhere.

Sometimes the stomach is distended with gas, which stinks of garlic. The mucous membrane is partly ash-colored, partly of a dark, purplish-red, and exhibits gangrenous ulcers which penetrate deeply into the muscular coat. In recent cases, the whole contents of the stomach shine in the dark, especially when gently warmed.

The liver is greatly altered, an acute fatty degeneration is found to have taken place in its secreting structure. The

acini are sometimes found filled with fat, even to bursting; but more commonly they are wholly destroyed, and oil and fat globules fill their place.

The secreting structures of the kidneys are also found in a state of fatty degeneration, and the ducts are sometimes filled with exudation matter. The heart and the muscles generally also show signs of the same fatty degeneration.

Arsenic. This is the poison most frequently chosen for the purpose of committing both suicide and murder.

Arsenic produces two classes of phenomena, one is purely irritant, by virtue of which it induces inflammation in the alimentary canal and elsewhere; and the other consists in a disorder of parts of organs remote from the seat of its application. It is absorbed by the blood, which in most cases of acute poisoning, is found in a remarkable state of fluidity, and can be detected in the liver, the spleen, and in the urine. It acts with nearly the same energy, whatever be the organ or tissue to which it is applied.

From two to three grains have proved fatal, but an instance is recorded of recovery after a dose of sixty grains. Death may ensue in half an hour, or may be delayed for nearly three weeks; the usual time is perhaps from twelve to forty-eight hours. There are some cases in which little or no morbid appearances are to be seen.

Usually, however, traces of irritation will be discoverable. In the mouth and throat they are often wanting. The inner surface of the stomach may be red and inflamed, or blackish from the extravasation of blood, or softened, or in some cases thickened, with the rugæ raised and corrugated. Ulceration of the coats of the stomach is but rarely met with, unless the patient have survived nearly two days. The mucous secretion is generally increased in quantity, sometimes thin, and viscid, as in its natural state, but sometimes solid, as if coagulated. In the latter case, it

forms either a uniformly attached pedicle, or loose shreds floating among the contents.

A very common appearance, is the presence of a sanguinolent fluid, or even actual blood in the cavity of the stomach.

The poison itself may also be found within the stomach. The intestines may be congested and inflamed throughout their whole length, but most frequently only in the duodenum and rectum.

Within the chest, redness of the pleura, redness and congestion of the lungs, have been noticed.

In general, arsenic retards the process of putrefaction after death.

The forms in which arsenic is most frequently used for the purpose of poisoning, are arsenious acid, and the arsenite of copper, Scheele's green.

Corrosive Sublimate. The appearances observed in the bodies of persons killed by this poison, are very similar to those excited by the irritant poisons already noticed.

The mouth and throat are more frequently affected than by arsenic. The tongue is often shrivelled, and the papillæ at its root greatly enlarged. The mucous membrane is swollen and whitened. The same appearances are generally noticed in the œsophagus. The coats of the stomach and intestines, more particularly the colon and rectum, have been found congested and inflamed, and sometimes destroyed, either by a chemical decomposition of the tissues, or by ulceration.

The bladder is often excessively contracted; the kidneys usually much congested and inflamed. Inflammation of the peritoneum, and effusion into its sac are frequent results of poisoning with corrosive sublimate.

Hydrocyanic Acid. The poisons whose energy depends upon the presence of this acid, surpass almost all others in

rapidity of action, and the minuteness of the quantity in which they operate.

The lesions produced are uncertain. The spine and neck are stiff, the abdomen retracted, the skin usually livid.

The body, generally the blood, serous cavities, stomach and the various tissues usually exhale, for some time after death, the characteristic odor of the acid. Turgescence of the venous system, and emptiness of the arterial system, are commonly remarked throughout the body. The stomach and intestines are congested and red. The liver and lungs are gorged with blood.

Strychnia—Nux vomica. In poisoning with this substance, the rigidity of the body which exists during life, is frequently retained for hours after death. There is congestion of the membranes of the brain and spinal cord.

The stomach is frequently quite natural in appearance, as also the intestines, although occasionally signs of irritation are noticed in both.

Alcohol. In death from alcohol, the body is slow to putrify, and the internal organs exhale no cadaveric odor, but rather that of recent flesh, or in some cases a faint odor of brandy. The appearances constantly found are, hyperæmia of the brain, sometimes cerebral hæmorrhage; hyperæmia of the large abdominal veins, or hyperæmia of the lungs and heart, and always visible fluidity and dark color of the blood.

Carbonic Oxide. This is the poisonous ingredient of illuminating gas, and is generated by burning charcoal. It is usually in one of these forms that it is the cause of death.

The most characteristic appearance after death, is the bright cherry-red color of the heart. There is, also, hyperæmia of the lungs and of the right side of the heart.

Opium. In cases of death from this substance, lividity of the skin is usually present.

Turgescence of the vessels of the brain, and watery effusion into the ventricles are generally met with.

The lungs are sometimes found gorged with blood. The stomach is occasionally red, but decided inflammation is rare. The blood is always fluid, and the body is apt to pass rapidly into putrefaction.

2. Death from Suffocation.

By suffocation is meant that condition in which the system is prevented from receiving the necessary amount of oxygen though the lungs. The term is generally restricted to a condition arising from the obstruction of the air passages, either internally, or from without, or from the breathing of irrespirable gases. (The latter form being attended also by blood-poisoning, which we have already noticed.)

The appearances noticed are the following:

The face may be more or less bluish-red, swollen, with protruding eyes, or differing in no respect from that observed after other kinds of death. Froth is often observed coming out of the mouth.

There is a universal and unusual fluidity and dark color of the blood. Hyperæmia of the right side of the heart, while the left is either entirely empty or contains only a few drachms of blood, hyperæmia of the lungs and congestion of the pulmonary artery, are seldom wanting.

In the case of new-born children, Caspar has noticed capillary ecchymoses, resembling petechiæ, beneath the pulmonary pleura, upon the aorta, or the surface of the heart, and even upon the diaphragm, which gives the parts a spotted appearance.

The mucous membrane of the larynx and trachea are

more or less injected, of a cinnabar-red, either in patches or uniformly over the whole surface. A deposit of soot upon the tracheal membrane, points to suffocation in smoke. There is usually present in the trachea a greater or less amount of fluid, consisting of a mixture of air, mucus, and blood, in the form of frothy vesicles, or colorless, or bloody foam. The more gradual the suffocation has been, the greater the quantity of this fluid. It may exist also in the bronchial tubes, and can be forced out by careful pressure on the lungs. Foreign bodies of every kind may be found in the trachea.

We find also as secondary results of the foregoing, hyperæmia of the abdominal and cranial organs.

3. Death from Hanging, Throttling and Strangling.

In these cases, death may result from simple cerebral congestion (apoplexy), from simple congestion of the thoracic organs (cardiac or pulmonary apoplexy), from a combination of the two (apoplexy and asphyxia), or, as is very frequently the case, from neuro-paralysis (nervous apoplexy).

The internal appearances will therefore vary, or, as in the last case, no lesions can be detected.

The face may in some cases be livid, with protruding eyes and tongue; but in many cases the countenance is like that of any other corpse.

Turgescence of the male and even of the female genitals has been noticed in some cases.

The mark of the cord about the neck may be wanting, and is nearly always more or less interrupted, and presents many varieties of appearance. It may be of a dirty, yellowish-brown color, cutting hard and leathery; or of a bright blue or dirty-reddish color, soft to cut; or it may have little or no color, and also soft to cut. Patches of excoriation are

also sometimes visible, if the cord have been hard and rough. A similar mark of the cord may be produced after death.

In cases of throttling, the marks of fingers may often be recognized, as round or semi-circular, or perfectly irregular patches, of a dirty, brownish-yellow color, hard to cut, and not ecchymosed. Rarely they are of a dirty-bluish color and ecchymosed.

4. Death from Drowning.

Physiologically considered, death from drowning is to be regarded as identical with death from asphyxia or strangling, and hence the results of the dissection, do not differ from those just mentioned. Those drowned may die from cerebral hyperæmia, the rarest form; from pulmonary hyperæmia; from both combined; or from neuro-paralysis. Death from hyperæmia of the thoracic organs, and death from paralysis, are of almost equal frequency in cases of drowning. The countenance is pale, in most cases not swollen, the eyes shut, and when asphyxia has been the cause of death, there is commonly froth over the mouth. If the body has been in the water for two or three days in summer, or eight to ten in winter, the face is rather reddish, or bluish-red—the commencement of putrefaction, which in bodies in water, begins in the head and extends from above downwards, and not in the abdominal coverings.

An almost constant appearance is the cutis anserina, a phenomenon entirely independent of the temperature of the water in which the person has been drowned.

The hands and feet have a livid, grayish-blue color, and the skin is corrugated in longitudinal folds, provided the body has not been taken out of the water within about

eight hours after death. Sand, gravel, mud, etc., are often found under the finger-nails.

Contraction of the penis and scrotum in men who have fallen into the water alive, is an almost constant appearance.

The lungs are greatly increased in volume, completely fill and distend the cavity of the chest, and are not firm and crepitating like healthy lungs, but feel like sponge. The trachea and large bronchial tubes are frequently filled with frothy mucus. The spasmodic closure of the glottis, will prevent the entrance of water into the lungs while life continues, but after death it may enter in small quantities.

In the stomach is often found some of the fluid in which the drowning has taken place.

CHAPTER V.

MEDICO-LEGAL QUESTIONS.

1. Method of Conducting a Medico-Legal Autopsy.

In making medico-legal examinations of human bodies, the greatest care must be taken not to omit the examination and recording of any of the appearances presented; since a point trifling in itself, may, in the course of the subsequent legal process, prove of great importance.

It may sometimes be necessary for the physician to examine the exact spot and the locality in which the body has been found, to ascertain the position in which it was discovered, etc., and also to inspect the clothing.

In cases of suspected poisoning, the utmost precautions are to be used in making the autopsy. All the viscera are to be carefully examined, and the stomach and intestines, with their contents, are to be removed in the manner already described. They are then to be opened, examined in separate vessels, either entirely new, or thoroughly cleansed immediately before being made use of. After a careful examination, they are to be placed in perfectly clean or new glass jars, without the addition of any foreign substance; the jars are then to be securely corked and labelled, and handed over to the chemist for analysis. Should the jars have to remain any time in the hands of the physician, they are to be kept under lock and key, in some place to which none but himself has access. Portions of other organs, especially of the liver, spleen, kidneys and brain, should also be preserved with the same care for future analysis.

The results of the examination are to be taken down on the spot, by an assistant, in ink, and after having been read

through by the physician at the close of the examination, are to be signed by him.

All these precautions will be found of great value, in saving from innumerable petty annoyances, at the hands of the "learned members of the bar," if the case should be brought before court.

In the *external* inspection of the body, we should notice:

1. *The Sex.* Even after the external parts of generation have been completely destroyed, the sex may still be ascertained by a reference to the growth of hair around these parts. A circumscribed arc of hair on the *mons veneris*, is distinctive of the female, while its prolongation, however slight, from this point towards the umbilicus, marks the male.

2. *The Age.* In the case of known bodies this is not of any importance, in unknown bodies it is, however, necessary. The physician can only conjecture from appearances, which, even in the living body, are very deceptive, and he will do well, therefore, to allow tolerably wide limits to this conjecture.

3. *The Size.* The length of the body must be ascertained by actual measurement in a straight line, from the crown of the head to the sole of the heel.

4. *The General Condition of the Body.* Lean or fat, etc.

5. *Color and Condition of the Hair.*

6. *Color of the Eyes*, if still recognizable.

7. *Number and Condition of the Teeth.* In the case of unknown bodies, an accurate description is always advisable, with a view to future identification.

8. *Special Marks or Deformities.* Scars, tattoo-marks, excess or defects of limbs, marks of disease, as ulcers, etc., should all be accurately noted.

9. *Injuries or Wounds*, which appear to have been the cause of death, should be carefully described. In the case

of wounds, their position and direction with reference to the neighboring fixed points of the body, and their exact length and breadth, must be recorded.

10. *Of the Body itself*, the parts deserving of particular examination are the natural openings of the ears, nose, mouth, anus and female genitals; the neck and the hands.

In the *internal* examination or dissection, the three great cavities—the head, thorax and abdomen—should all be opened. In some cases, it may be important to open also the spinal canal.

The first thing to be observed on opening each of these cavities, is the position of the organs they contain; next, whether there be any fluid effusions present; and lastly, the external and internal appearance of each separate organ. In every case, that cavity should be opened first, in which there is the greatest probability of finding the cause of death. In the case of new-born children, however, the abdomen must be first opened in order that the natural position of the diaphragm may be observed undisturbed.

In examining the base of the skull for injuries, we must not omit to remove the periosteum, which might otherwise conceal small fissures.

In examining the thoracic organs, if it be particularly desired to observe the amount of blood contained in them, and we do not wish to apply ligatures, we examine the heart first, leaving it in its natural horizontal position, and opening it by a lateral longitudinal incision on both sides. This gives us a distinct idea of the actual amount of blood in all the cardiac cavities. The lungs are next cut into, and last of all the large blood-vessels. This procedure is to be followed, *e. g.*, in cases of suffocation, where it is of particular importance to determine the amount of blood in these organs, and where the blood is peculiarly fluid.

In determining the amount of blood in the venous trunks, it will be sufficient to examine the *vena cava ascendens.*

In penetrating wounds, the wound is of course to be examined as far as possible before disturbing any of the organs.

The result of the external and internal examinations, thus thoroughly conducted, are to be noted down at the time, and are not to be trusted to memory. It is of the utmost importance that this rule be observed.

In presenting a written or verbal report before court, the physician should be careful to furnish merely a description of the post-mortem appearances, and not to give an opinion as to their probable or possible cause or causes, unless called upon to do so. He should also avoid prolixity and, as much as possible, the use of technical terms, unintelligible to non-professionals.

His answers to direct questions should be concise and decided if possible, but where this is not possible, he should not hesitate to state that the dissection has not afforded him any facts which could enable him to give a positive answer.

2. Questions relating to New-Born Children.

The body of a dead infant is found, and the physician may be called upon to answer the following questions, one or all:—Was the child mature? Was it born alive? If so, what was the cause of its death?

Was the child mature? Among the various signs of fœtal maturity, such as the firm, tense skin, of the usual pale corpse-color, the hair upon the head, the weight and length of the body, the diameters of the head, shoulders and hips, the horny nails reaching to the tips of the fingers, the

absence of the pupillary membrane, etc., the most infallible, is the presence of the centre of ossification of the inferior femoral epiphysis. "The easiest way to find this, is to make a horizontal incision through the skin and superficial tissues over the knee-joint down to the cartilages. The patella is then to be removed, and the end of the femur made to protrude through the incision. Thin horizontal sections are then to be removed from the cartilaginous epiphysis, at first more boldly, but so soon as a colored point is observed in the last section, then very carefully, layer by layer, till the greatest diameter of the osseous nucleus is attained. This appears to the naked eye as a more or less circular bright blood-red spot in the midst of the milk white cartilage, in which vascular convolutions can be distinctly recognized." When there is no visible trace of this centre of ossification, the fœtus can be no more than from thirty-six to thirty-seven weeks old.

In still-born children, the commencement of this nucleus indicates a fœtal age of thirty-seven to thirty-eight weeks; when it possesses a diameter of from three-quarters to three lines, it shows the fœtus must have attained a uterine age of forty weeks. When the osseous nucleus measures more than three lines, we may conclude that the child has lived after birth.

Isolated exceptions are occasionally met with, when, however, concomitant appearances, such as, in the one case, defective ossification of the skull, or in the other, peculiarly advanced development, will guard us against mistakes.

Was the child born alive? or, *Did it live during and after its birth?* and, *If so, how long?*

These questions are intimately connected, and in order to be able to answer them, we must in our examination note the following points:

The position of the diaphragm, is a good diagnostic sign.

The diaphragm will necessarily be higher where there has been no respiration, natural or artificial, than where the child has actually breathed. "Its position is most easily ascertained by making a longitudinal incision through the skin and superficial cellular tissue, from the chin to the pubis, in the mesial line, dissecting these from the thorax on both sides, next carefully opening the abdominal cavity, introducing the finger of one hand into it, and pressing it up to the highest point of the concavity of the diaphragm, and then with one finger of the other hand reckoning off the intercostal spaces from above downwards till both fingers correspond. The rule is, that the highest point of the concavity of the diaphragm in children born dead, is between the fourth and fifth ribs, and in those born alive, between the fifth and sixth." Where respiration has been but transitory, the diaphragm will remain very nearly in its fœtal position.

The lungs, from lying quite posteriorly in the fœtus, come to fill the cavity of the chest, the more perfectly respiration has been established. In the fœtus, the left lung is never found even partially covering the heart. Where respiration has been but transitory and imperfect, the volume of the lungs will not be much increased.

The presence of dark bluish-red, insular patches in the lungs, no matter what may be their ground color, proves that respiration has taken place.

The crepitant spongy consistence of the lungs of a live-born child, is readily distinguished from the compact, resistent liver-like lungs of one still-born.

The hydrostatic test for the presence of air in the lungs, is of all, the surest for deciding whether respiration has taken place. The vessel used should be at least one foot in depth, eight or ten inches in diameter, and filled with pure cold water. The buoyancy of the lungs depends upon the greater or less completeness with which the pulmonary

tissue is permeated by the air. Only one lung may float, generally the right one, or only single lobes, or only a few pieces into which the lung has been and must be divided, in order accurately to apply the test. Artificially inflated fœtal lungs, may be distinguished from those lungs which have respired, by the presence, in the case of the latter, of the bluish-red mottling above referred to, and the escape of bloody froth when the substance of the lungs is cut into, and slight pressure applied.

The general appearance of putrescence in the lungs, will serve to distinguish the buoyancy arising from the gaseous products of putrefaction, from that due to respiration.

Careful attention to the foregoing points, will enable us to answer with certainty whether the child was born alive.

How long did the child live after its birth? The question can be approximately answered with reference to the first few days, by attention to the following points:

If there are no traces of blood, or of that peculiar unctious substance, the *vernix caseosa*, on the body, sufficient time. must have elapsed since its birth, to have afforded leisure and opportunity for cleansing it.

The contraction of the umbilical arteries in living children, does not occur sooner than after eight or ten hours. The mummification of the cord commences after two, three, or even four days, and the putrefaction only after a much longer time. Mummification of the cord takes place as well after death as before, but not in water, nor in the liquor amnii. If the umbilicus has already cicatrized, the child must be at least five days old.

The stomach immediately after birth, contains a small quantity of quite white, transparent, seldom somewhat bloody, inodorous mucus, very tough, or a trifling quantity of the colorless liquor amnii. If milk be found, it shows that some time must have elapsed since the birth.

In the large intestines meconium is still to be found, two, three, or even four days after birth.

The age of a child, evidently older than five or six days, can only be determined by general appearances.

What was the cause of death? We will here refer only to those injuries and kinds of death as can only occur in new-born children, and to those *post-mortem* appearances which might lead to error in regard to them.

During labor, death to the child may result from cerebral hyperæmia, or from injuries to the cranium, which are then unattended by traces of violence on the body, and are frequently due to imperfect ossification of the bones, detected by holding the bones up to the light after removal of the periosteum.

Prolapse and pressure of the cord, and coiling of the cord around the neck, may produce all the appearances of death by suffocation.

The mark of the cord runs uninterruptedly round the neck, is broad, circularly depressed, grooved, never excoriated, and everywhere quite soft. A mummified, parchment-like, unecchymosed depression, with or without excoriations, points to intentional strangulation.

Subsequent to birth, the child may have been killed by falling on its head on the floor, if the birth has been very rapid. The probable results of such a fall, would be rupture of the cord; premature separation of the placenta, with its consequences; concussion of the brain and hyperæmia, or actual hæmorrhage within the skull; and fracture of the skull bones. The fractures are almost exclusively confined to the parietal bones, one or both, chiefly in the region of the vertex.

Comminuted fracture of several bones of the skull, speak against an accidental death by a fall. The absence of any signs of violent usage on other parts of the body, or about

the head, with simple fracture of the skull, speaks for an accidental death.

The child may also have been suffocated by the mother in violent attempts at self-delivery. The visible signs of this will consist merely of scratches and nail-marks upon the face or neck. Very severe injuries are never produced in this way.

We must be careful not to mistake the common blood-coagulum usually found under the aponeurosis on the child's head for the result of violence; nor the folds of the skin, in fat children particularly in winter, produced by the movements of the head, and which remain strongly marked in the solidified fat, for the mark left by the cord in a case of actual strangulation.

3. Supposed Period of Death.

The answer to the question as to the probable time of death, is often of the utmost importance. To be able to determine this, we must have regard to the various appearances following death, previous to putrefaction, and to the chronological succession of the phenomena of external and internal putrescence.

A. *Signs of Death previous to Putrefaction.*

Respiration and circulation have entirely ceased.

The eyes have lost their lustre.

There is no vital reaction to stimulants.

The body grows ashy-white. A particularly florid complexion may retain its color for some days after death.

Neither the red or livid edges of ulcers, nor red, black or blue tattoo-marks disappear after death.

An icteric hue existing at death never becomes white, and

ecchymoses retain in every case, the hue they had at the time of death.

Most bodies become quite cold in from eight to twelve hours. Fat bodies and those of persons killed by lightning, or by suffocation, retain the heat longer than others; in water, bodies cool rapidly.

A general relaxation of the muscular system occurs immediately after death.

A body presenting only the above signs, has been dead from eight to twelve hours at the longest.

In from twelve to eighteen hours the eye-balls become soft and inelastic, and feel flaccid.

The muscles on those parts of the body on which it lies, become flattened by the weight of the body.

In from eight to twelve hours after death, hypostases resulting from the gravitation of the blood in the capillaries, begin to form on all the depending parts of the body.

The most important are the external hypostases—for they are liable to be confounded with ecchymoses, and consequently with traces of violence committed previous to death. An incision into the discolored spot should always be made, when, if it be an hypostasis—a post-mortem stain—there will be no escape of effused fluid or coagulated blood, as there will be if it be an ecchymosis, the result of violence previous to death.

The color of these post-mortem stains varies from a livid or coppery-red to a reddish blue. They are extremely irregular in form, and are never elevated above the surrounding skin. They are formed after every kind of death.

Internal hypostases occur in the brain, in the sinuses and veins of the pia mater of the posterior hemispheres, even after death from hæmorrhage. They must not be confounded with cerebral hyperæmia.

In the lungs, hypostases are of constant occurrence, and

are carefully to be distinguished from the signs of antemortem pulmonary congestion and pneumonia.

In the intestines and kidneys, hypostases are also noticed.

In the heart we find no hypostasis, but clots, or "cardiac polypi," which are the coagulated fibrine of the blood, formed in most cases after death. Their presence proves that coagulation of the blood may take place after death.

The last sign of the earliest stage of death is the *rigor mortis*. It passes from above downwards, beginning on the back of the neck and lower jaw, passing on into the facial muscles, the front of the neck, the chest, the upper extremities, and last of all, the lower extremities. It begins variously after eight, ten, or twenty hours, and may last from one to nine days. In the mature new-born infant it is feeble and very transitory. A low temperature, and the existence of alcoholization, favor the long duration of cadaveric rigidity. A frozen body is stiff as a board from head to foot, whereas in rigor mortis the extremities, particularly at the elbows and knees, preserves a certain amount of mobility. A body in which only the signs thus far mentioned are present, may be presumed to have been dead from two to three days at the longest.

B. *The Process of Putrefaction.* The progress of putrefaction is modified by the following conditions:

By age. The bodies of new-born children putrefy more rapidly than others; those of very aged persons much more slowly.

By the condition of the body. Fat, flabby and lymphatic corpses putrefy more quickly than lean ones, for an abundance of fluid is very favorable to decomposition.

By the kind of death. The process is rapid after death from exhausting diseases, from injuries attended with much mutilation, from suffocation, from narcotic poisons. It is

slower after sudden death in healthy persons, after death from poisoning with phosphorus, sulphuric acid and alcohol.

By the access of atmospheric air. Whatever prevents this, retards decomposition. Thus, bodies buried in the earth, or lying in water, or clothed, putrefy less rapidly than those exposed to the direct influence of the air.

By the quantity of moisture, which in addition to its own, can and does reach the body from without. The more moisture, the more rapid the process.

By the temperature of the air, or of the water in which the body is lying. "At a tolerably similar average of temperature, the degree of putrefaction present in a body after lying in the open air, for one week (or month), corresponds to that found in a body after lying in the water for two weeks (or months), or after lying in the earth in the usual manner for eight weeks (or months.") (Caspar.)

In bodies lying in the air, external putrefaction begins with a greenish coloration of the abdominal coverings, in from twenty-four to seventy-two hours after death, according to the modifying conditions just noticed. (In bodies lying in water, the process of putrefaction begins in the face, head as far as the ears, and the upper part of the neck, with a livid, bluish tinge, rapidly becoming a brick-red, and proceeds downwards in the same relative manner as about to be described.) Within the same period, the eye-ball becomes soft, yielding to the pressure of the finger.

After three to five days from the period of death, the discoloration has spread over the whole abdomen and external genitals, and spots make their appearance on other parts.

In from eight to ten days the discoloration has spread over the whole body, and the peculiar odor is developed. The abdomen is distended with gas; the cornea has fallen in and become concave. The nails are still firm.

In fourteen to twenty days after death, the whole body is

of a bright-green, mixed with red and brown. The epidermis is raised here and there in blisters, and in other parts patches of it are quite stripped off. Maggots cover the body. From the continued development of gas, the whole body is bloated, and has a gigantic appearance. The nails are detached at their roots and lie loose, and are easily separable. The hair is loose and easily pulled out.

Since this stage may continue many weeks or even months, we cannot distinguish a body in this state after one month, from one in the same condition after from three to five months.

After from four to six months, or sooner in the case of bodies that have lain in warm and moist media, the cavities of the body are opened by the continued development of gas; the skull has separated from the neck, and the brain has run out; the orbital cavities are empty; all the soft parts have commenced to break down into a soft pulp, or are partly already broken down and dissolved, leaving entire bones exposed. The bones of the extremities are often separated by the destruction of the fasciæ and ligaments. No trace of a physiognomy is discernible. The doubtful sex of the deceased can only be determined from the external peculiarities of form, or the hair about the pubis, or by the presence of a uterus, which withstands decomposition longer than any other soft organ of the body.

Internally, the process of putrefaction begins in the trachea and larynx. The brain in children up to the end of the first year, is next attacked. Next the stomach, intestines and spleen, and then the omentum and mesentery. The liver is usually compact and firm, even some weeks after death. Putrefaction commences on its convex surface. The brain of the adult follows next in the succession of putrefying organs. Several months usually elapse before putrefaction of the heart has advanced very far. In the lungs decomposition begins about the same time as in the heart,

sometimes earlier. The kidneys, urinary bladder, œsophagus, pancreas, diaphragm and larger arterial trunks then succumb, and last of all the uterus.

4. The Probable Cause of Death.

Although in general, a careful examination of a body found dead, will readily reveal the true cause of death, yet instances frequently occur where attempts at concealing it, or peculiar circumstances in connection with the death, may render the task more difficult.

We confine ourselves here to a brief notice of some of the more important points to be kept in view, in rightly estimating the relative value of post-mortem appearances, and in guarding against possible mistakes.

Rough handling, falls and blows, occurring a short time after death, may produce excoriations and pseudo-ecchymoses, which cannot by sight be distinguished from such as are the result of violence inflicted during life.

Wounds inflicted during life are distinguished from those inflicted after death, by the entire absence in the case of the latter, of any signs of vital reaction, as inflammation, hæmorrhage, suppuration, swelling or cicatrization of the edges of the wound, etc. But in the case of very sudden death from wounding of an important organ, these traces of vital reaction may also be wholly wanting. Again, injuries are often produced on dead bodies, by the instruments used to recover them from the places in which they have been discovered.

Contused wounds seldom represent the exact dimensions of the weapon employed.

Blunt weapons may merely contuse and disfigure, or lacerate, or fracture bones, or produce rupture of internal

organs. Healthy organs never rupture spontaneously, and can only be ruptured by external violence.

The inspection of the position, direction, depth, breadth, and number of wounds, compared with the weapon with which they have been inflicted, often furnish the means of approximately judging of the position of the perpetrator when he committed the deed, and even his object and bodily strength.

In judging whether *fractures* have been produced before or after death, we must remember that it is very difficult to fracture the bones of a dead body. Hence, for example, considerable injuries of the cranial bones, particularly of the base of the skull, have most probably been produced during life. A fracture of the ribs in the dead body is never splintered.

In deciding whether a case is one of *suicide* or *homicide*, besides the previous state of mind of the deceased, the posture and position of the body, hands, etc., the appearance of the clothing, and the character of the wounds or injuries, are the points to be particularly noted, as well as the absence or presence of evidences of robbery.

Gunshot wounds produced upon dead bodies, are never as deep as similar ones would be in a living body; the track of the bullet can be distinctly traced; and the edges of the wound show no appearance of vital reaction. Hence they can readily be distinguished from such as have been produced during life.

Burning of a dead body does not in general produce vesication; by exceedingly intense heat it may, however, be produced. The bullæ, however, last but a few minutes, never contain serum, but only watery vapor, and never exhibit any trace of the bounding line of redness, nor any trace of color on their basis. They are, therefore, easily distinguished from burns inflicted during life.

In distinguishing between spontaneous apoplexy and *cerebral hæmorrhage* the result of injuries, it will be sufficient to note that, in the former case, but a very small amount of blood is effused, so that the discovery of very extensive and considerable extravasation of blood within the cranial cavity, can be regarded as a proof of the application of external violence.

In the case of a dead body found *hanging*, it is in most instances to be regarded as a case of suicide, unless the examination of the body should show external marks of violence, or internal signs of death from another cause.

Where a body has been found in the water, the question may arise whether it was alive or dead when it entered the water. The investigation of the body will reveal the cause of death. The surest sign that the body was alive when it was thrown or fell into the water, is the presence in the stomach of some of the fluid in which it was lying, if this fluid be such as is never voluntarily drank. Whether the drowning was a case of suicide or homicide, it is sometimes impossible to determine. All the various circumstances of time and place, and concomitant appearances, must be minutely investigated, in order to hope to arrive at a probable conclusion.

In the case of *supposed poisoning*, where the fact of the administration of poison has been proved, and the person has died with symptoms attributable to poisoning, and the post-mortem appearances reveal no other cause of death—then the death is to be regarded as the actual results of the poison, whether its existence in the body can be proved by chemical analysis or not. Only such poisons are used by suicides as a general thing, as are known to be *certain* poisons, and such as have a very disagreeable taste are, from this fact, hardly ever used for the purpose of murder, except in the case of very small children, or persons rendered insensible by any means. (Caspar.)

CHAPTER VI.

ON EMBALMING THE DEAD.

From the earliest times, the attention of mankind has been given to the preservation of the bodies of the dead. With the ancient Egyptians, the art was carried to its highest degree of perfection. The motive which led these people to devote so much care to this object, is still conjectural; yet it would seem to have originated, in part at least, as a sanitary measure, for preserving the purity and healthfulness of the atmosphere.

While so little is known of the method by which they produced such wonderful results, as to have placed the process among what have been termed the "Lost Arts," yet, from a careful examination of a large number of mummies, it would appear that the operation consisted:

First. In the removal of the abdominal and thoracic viscera, through an opening in the left side beneath the ribs; and of the brain through the nostrils, by breaking through the crebriform plate of the ethmoid bone; or through the mouth, by boring through the basilar process of the occipital bone.

Second. Subjecting the body for a long time to the action of an alkali, (natron,) after having filled the cavities with various gums and spices, etc., and thus removing the fatty portions.

Third. A rapid desiccation, after further additions of balsams, resins, etc.

Fourth. Enveloping the whole body in numerous bandages saturated with gum or bitumen.

Modern nations, have long practiced evisceration, in connection with the use of various substances for preserving bodies. In the middle ages, the art of embalming con-

sisted in mixing aromatic substances with salt, and filling the bodies with the same. Henry I. of England, is said to have been thus embalmed in 1135. Long and deep incisions were made in various parts of the body, these filled with the composition, and then carefully sewed up, the body afterwards enveloped in a beef's skin, and enclosed in a coffin.

Louis C. Bils, a nobleman of Holland, and Ruysch, a Dutch physician, in the latter part of the seventeenth and beginning of the eighteenth centuries, acquired great celebrity from their success in embalming bodies. Both died, however, without imparting their secrets to others.

The discovery of the preservative properties of corrosive sublimate in 1762, was soon followed by its employment by Chaussier, Beclard and Larrey, in the preserving of bodies. Dr. Franchina of Naples, employed arsenic also, with considerable success; but from the danger to dissectors, where these poisons had been employed, their use after the discovery of the preservative properties of chloride of zinc, was quite discontinued.

The latter substance, with carbolic acid, constitutes the best antiseptis known at the present time, and these are more generally employed than any other for preserving dead bodies.

The objects of the process of embalming at the present day, are threefold: 1st. It permits the delay of burial where this is desirable from the absence of friends; or of the ready transportation of the bodies of those who may have died a long distance from home, and that free from decay and post-mortem change. 2d. As a sanitary measure in large towns and cities, where many bodies are placed in family vaults, instead of being buried in the ground. 3d. For the preservation of bodies for the purpose of anatomical study.

For either of these objects, it is desirable that the process be simple, easy, quick and inexpensive.

Frequently in the large cities, and occasionally in the country, the physician will be called upon to perform this operation, but without some information upon the subject, he will be unable to comply with the request.

The operation at the present time, consists simply in filling the vascular system with a preserving fluid, by injecting the same into some one or more of the arteries; the substance employed being either carbolic acid or chloride of zinc in solution; the latter, from possessing greater preserving power without the disagreeable odor of the carbolic acid, being much more frequently employed.

Preparation of the Zinc. In the large cities, the chloride of zinc may be obtained of the manufacturing chemists ready made; but in the country, the physician may manufacture the solution himself, by the following process:

Place in an open stone jar, ten pounds of muriatic acid, and add to the same, old scrap sheet zinc, *ad libitum.* It should be frequently stirred, and allowed to stand in the open air for from twelve to twenty-four hours, or until the acid has so acted upon the zinc as to have become thoroughly neutralized, forming thus a saturated solution of the chloride of zinc.

The quantity required of this solution to preserve a body, will depend upon the state of the weather, in connection with the size of the body, cause of death, etc.; more being required in hot weather, or in a large body, or in such diseases as are followed by a tendency to rapid putrefaction. In all cases, however, the rule should be to *throw in as much as the vessels will hold,* varying the strength according to the weather, character of the body, etc. With young, thin subjects, and cool weather, the chloride may be diluted one-half with water; but in warmer weather, and with a large body full of fluids, a proportion of two-thirds zinc, or even stronger may be required. It will be well to commence by

throwing in a weaker solution, which, by not constringing the small vessels, will pass more readily into the extremities, and follow by a stronger for filling the large vessels of the trunk.

Dr. Vivodtsef of St. Petersburg, employs a mixture of carbolic acid and alcohol. Taking alcohol of about ninety degrees, he adds one-fifth its weight of carbolic acid; there being required of this mixture, a quantity equal to about one-half the weight of the body to be injected. It may be thrown into the vessels in the same manner as the solution of the chloride of zinc. The high price of alcohol in this country, would constitute an objection to the use of this substance, even if it afford advantages over the zinc, which it probably does not.

Instruments Required. For the satisfactory performance of this operation, there will be required the *anatomical syringe.* This instrument consists of a brass cylinder and piston, of a capacity of twelve to sixteen ounces, with a movable stop-cock, and series of graduated pipes for arteries of different size. Each pipe has a small rim or shoulder at the point to be introduced into the vessel, above which the ligature is applied, which thus holds the pipe more securely in its position.

The absence of the anatomical syringe should not, however, deter the physician from attempting this operation, as, by a little preparation, the common gum-elastic family syringe, of the Mattson or a similar pattern, may be made to answer the purpose. The point of the small or child's rectum pipe may be reduced with a file, and a shoulder prepared, about one-fourth of an inch from the end, for securely holding it when tied in the vessel.

An apparatus of a complicated character, and working by atmospheric pressure, has been devised for this purpose; but

while it possesses very few advantages over the syringe described, it is expensive and not easily managed.

The Operation. In the dissecting-room, it is usual to open the chest and inject through the arch of the aorta; but in other cases, one of the common carotids, and better the right, may be selected. Extend the head, placing thus the muscles upon the stretch, and along the inner border of the right sterno-cleido-mastoid muscle, make an incision two inches in length, through which may be exposed the upper portion of the common carotid artery. After detaching the vessel from the surrounding structures, it should be raised upon the handle of a scalpel and two ligatures passed around, one of which is to be tightly tied, high up, upon the vessel. Below this, a longitudinal slit, one-half inch in length, should be made in the vessel, for receiving the pipe of the syringe, which, when in position, should be securely tied with the second ligature, just above the rim. The stop-cock joint may now be fitted to the pipe.

To permit of the escape of as much of the blood as possible, an opening may be made into the jugular vein, ligatures being passed beneath the vessel—one above and one below the opening—that it may be closed at the proper time.

The antiseptic fluid having been prepared in a convenient vessel, the syringe, after having been carefully examined and found in good working order, should be slowly filled, adjusted to the stop-cock joint, the cock opened, and the syringe slowly discharged. Shutting off the cock, to prevent escape of the fluid, the syringe may now be detached, refilled and again discharged, the process being repeated until the vessels are filled with the fluid, which may be known from the resistance offered to its introduction. After a few syringefuls have been thrown into the vessels, the blood will

be seen flowing more or less freely from the jugular, and which will gradually change to the clear antiseptic fluid; then the vessel may be tied, to prevent any further loss.

To facilitate the flow of the fluid into the vessels of the extremities, free flexion and extension of all the limbs should be made; and after some minutes, another effort made to force in more of the fluid. A successful filling of all the vessels may be known by the distension of the superficial veins of the chest and arms, accompanied with an escape of a dark fluid from the nostrils and, perhaps, mouth, from an oozing of the fluid through the capillary vessels of the mucous membranes of the head.

If the extemporized gum syringe be used, its pipe should be tied in the vessel as in the other case, the opposite end of the tube placed in the vessel of fluid, and the same thrown in by pressure of the ball. The operation being completed, a ligature should be tightly placed around the artery below the pipe, the latter removed and the incision sewed up.

Changes Resulting from the Operation. As the vessels become filled during the operation, the abdomen will gradually swell, the chest become more round and full, the face and eyelids become puffy, while the superficial veins will appear full and dark from the contained blood. In a few hours the skin assumes a pale, ashen hue, with a parchment-like feel, which will be a sure indication of the success of the operation. In a few days the puffed appearance of the face will have disappeared, when no further change will be noticed, until after several weeks the ears, with the tip of the nose, and ends of the fingers, begin to shrivel and dry up.

CHAPTER VII.

PRESERVATION OF SPECIMENS OF MORBID ANATOMY.

Many valuable and interesting pathological specimens are continually being lost, from a want of knowledge, or a careless neglect on the part of the physician. That the fullest benefit may result from a post-mortem examination, any rare or interesting specimen should be carefully preserved. Should the physician feel no interest in forming a cabinet of morbid anatomy for himself, he should then deposit the specimen in the anatomical museum of some medical school, where it may be permanently preserved, and the profession thus benefited.

All specimens of *soft tissues* designed for preservation, should first be soaked in water which is changed daily, until all blood is removed. If the weather be warm, it will be necessary to add to the water each time, either a small proportion of alcohol, or some antiseptic, as carbolic acid, chloride of zinc, corrosive sublimate, or common salt.

After all blood is removed, the specimen may be put into alcohol of a strength proportionate to the size of the specimen, and then allowed to remain until thoroughly "cured." Small specimens are dried up, shrunken and nearly spoiled in many cases, by the use of too strong alcohol, while on the other hand, large ones, by diluting the alcohol with the large amount of water contained, would be likely to spoil in a weak preparation. Large specimens, particularly in warm weather, should have deep incisions made at a few points, for the better penetration of the preserving fluid.

Before being permanently put up, the specimen should be carefully trimmed, and everything interfering with the best display of the essential point removed.

While either of the antiseptics mentioned above will answer for "curing" a specimen, for permanent suspension, there is no substitute for alcohol. Other fluids may preserve, but they will also become turbid, throw down a precipitate, and in cold weather are liable to freeze, while from their high specific gravity, many light specimens will float on or near the surface. If the specimen has been thoroughly "cured" before suspension, very dilute alcohol will answer for that purpose: equal parts of pure water and alcohol of ninety-five degrees, in all except the larger specimens, being abundantly strong. Delicate, light specimens will sometimes float in such a dilution, in which case it should be made stronger.

The best form of anatomical jar is made with ground glass stoppers, with a hook on the under side of the latter for suspending the specimen. Although expensive, these jars, by effectually securing the alcohol from evaporation, as well as from the greater facility with which the spirits may be changed, which will sometimes be required, will give better satisfaction than any other.

Where the common jar without a stopper is used, great care will be required in closing up, to prevent loss by evaporation. There should first be prepared a circular plate of thick sheet lead, to rest on the top of the neck of the jar. The specimen having been suspended by a string, carried through by a large needle, and at two different points, is to be fastened to the disk of lead by means of two holes, punched by an awl, about half an inch apart, near the centre. The portion of string above the lead, with the holes also, should now be carefully covered with sealing-wax, otherwise, by capillary attraction, the alcohol will keep the bladder covering continually wet, and finally rot it out. Over the lead is now to be stretched a piece of moistened bladder, and wound with twine around the neck of the jar. When dry, this is to be covered with a coat of black varnish; this

again when dry, being followed by a second layer of bladder and varnish.

Wet preparations should be kept where they may have a free exposure to sunlight. If placed in a dark closet, they become damaged in texture, and acquire a dark and unpleasant color; this is particularly the case with the ligamentous and nervous tissues.

Dr. Brunetti of Padua, who has invented a new process for preserving certain kinds of specimen, and who received a gold medal some years ago at the Paris Exposition, gives the following particulars of his method:

"The process comprises four several operations, viz.: 1, the washing of the piece to be preserved; 2, the *degraissage*, or eating away of the fatty matter; 3, the tanning, and 4, the desiccation.

"1. To wash the piece M. Brunetti passes a current of pure water through the blood-vessels and the various excretory canals, and then he washes the water out by a current of alcohol.

"2. For destroying the fat he follows the alcohol with ether, which he pushes, of course, through the same blood-vessels and excretory ducts; this part of the operation lasts some hours. The ether penetrates the interstices of the flesh and dissolves all the fat. The piece, at this point of the process, may be preserved any length of time desired, plunging it in ether, before proceeding to the final operations.

"3. For the tanning process M. Brunetti dissolves tannin in boiling distilled water, and then, after washing the ether out of the vessels with distilled water, he throws this solution in.

"4. For the drying process Dr. Brunetti places the pieces in a vase with a double bottom filled with boiling water, and he fills the places of the preceding liquids with warm, dry air. By the aid of a reservoir, in which air is compressed to about two atmospheres, and which communicates

by a stop-cock and a system of tubes, first to a vase containing chloride of calcium, then with another heated, then with the vessels and excretory ducts of the anatomical piece in course of preparation, he establishes a gaseous current which expels in a very little time all the fluids. The operation is now finished.

"The piece remains supple, light, preserves its size, its normal relations, its solid elements, for there are no longer any fluids in it. It may be handled without fear, and will last indefinitely."

For the preservation and hardening of tissues for microscopic examination—as sections of tumors, glands, membranes, spinal cord or brain, etc.—Müller's fluid may be employed, which is prepared as follows: bichromate of potassa, 75 grains; sulphate of soda, 35 grains; dissolved in six ounces of water. The specimen should be suspended in this fluid until sufficiently hardened to permit of a satisfactory examination.

Preparation of Bones.

Pathological specimens of bones, may be prepared either by boiling or maceration. The method by boiling should be employed, however, only where the texture of the specimen is firm and solid, as in cases of united fracture, etc.; and in these cases, care will be required to avoid injuring the specimen by too long exposure to the process. Maceration, however, is the better method for all cases, and the only one to be employed in cases where the bone is softened by caries or necroses.

The specimen having been roughly stripped of the soft tissues, is to be thrown into a vessel of water, the latter being changed every day, as long as it becomes colored by the blood. It is now to be left until the putrefactive pro-

cess has so softened the tissues that they may be easily removed, when, after being thoroughly washed in soda water, it may be dried and mounted. If the weather be cold, it will be absolutely important that the macerating be conducted in a warm room, else the process will be so slow as to convert the tissues into a form of adipocere, quite arresting the putrefactive process, and greatly damaging the specimen in its beauty and value.

In this connection, it may be observed that bones from a subject that has been injected with chloride of zinc, can never be successfully macerated, the zinc having a sort of tanning effect upon the tissues, which enables them to resist the putrefactive process. Boiling is the only method by which such specimens can be cleansed.

Where a bone has been properly macerated and dried, and especially if from a young subject, it will be found white and quite free from grease; but when taken from old subjects, or when prepared by boiling, it may be required to be subjected to a bleaching process for removing the grease and improving the color. By exposure to the sun, with frequent washing in chlorine and soda water, the appearance of the specimen may be greatly improved, or what is still better, by covering the specimen for a few days in sulphuric ether, which will effectually dissolve out all the grease, and then washing and exposing to the sun for a few days, it will be left beautifully white and clean.

For permanent preservation, the specimen should finally be mounted on a block or board, in such a manner as best to expose its interesting points.

INDEX.

PAGE

Abdomen, method of opening.... 127
Abdominal dropsy..... 135
Alcohol, poisoning by..... 299
Anatomical syringe..... 323
Anus, diseases of..... 157
fistula of..... 157
hæmorrhoids..... 159
ulcer in..... 157
Aorta. (See *Arteries.*)
Apoplexy, cerebral..... 41
pulmonary..... 115
Arachnoid, examination of..... 88
Arsenic, poisoning by..... 297
Arthritis, chronic rheumatic..... 271
scrofulous..... 271
Arteries, aneurism of..... 99
calcification of..... 99
examination of..... 98
fatty degeneration of... 99
inflammation of..... 98
ossification of..... 99
rupture of..... 102
Arteries, cerebral.
atheromatous degeneration of..... 60
calcification of..... 60
obstruction of..... 59
position of clot in obstruction of..... 59
Atresia ani..... 149
urethræ..... 212
Autopsy, medico-legal, method of conducting..... 304

Biliary calculi..... 188
effects of..... 190
position of..... 189
Bladder, gall-. (See *Gall-bladder.*)
Bladder, urinary.
contraction of..... 210
catarrh of..... 210
cancer of..... 211
dilatation of..... 209
examination of..... 208
hypertrophy of..... 209
inflammation of..... 210
malformations of..... 208
parasites in..... 212
removal of..... 131

PAGE

Bladder, urinary.
tubercles in..... 211
tumors in..... 211
Bones, abscess of..... 259
cancer of..... 266
caries of..... 260
examination of..... 259
inflammation of..... 259
morbid growths in..... 263
necrosis of..... 260
rickets in..... 261
suppuration of..... 259
tumors in..... 263
tubercles in..... 265
Brain, appearance of, in health... 48
abscess of..... 50
atrophy of..... 53
blood cysts in..... 59
calcareous deposits in..... 56
examination of..... 29
hardening of..... 51
hypertrophy of..... 52
hydatids in..... 57
inflammation of..... 47
membranes of..... 36
removal of..... 29
softening of..... 48
tumors of..... 54
Bright's disease..... 197
cirrhotic or contracting form..... 201
inflammatory form..... 197
waxy or amyloid form.. 200
Bronchial tubes, dilatation of.... 125
examination of..106, 122
inflammation of..... 123
narrowing of..... 124
obliteration of..... 124
Bronchitis..... 123
Buccal cavity, examination of.... 65
Burning, ante-mortem distinguished from post-mortem..... 318

Cancer, of bones..... 266
black..... 291
colloid..... 292
encephaloid..... 291
epithelial..... 293
of gall-bladder..... 188

Cancer, of heart..... 84
hard 299
of intestines..... 158
of kidneys..... 204
of liver..... 177
of lungs..... 120
of mammæ.....256, 257
of mediastinum..... 126
medullary..... 291
melanotic..... 291
of ovaries..... 250
of œsophagus..... 73
of penis..... 217
of prostate gland..... 228
of pancreas..... 161
of peritoneum 136
of spleen..... 165
of suprarenal capsules... 208
of scrotum..... 219
of stomach..... 146
scirrhus 290
of testicles..... 224
of tongue..... 68
of ureters..... 206
of urinary bladder..... 211
of urethra..... 214
of uterus..... 240
of vagina..... 234
Calculi, urinary..... 214
Calvarium, removal of..... 28
Carbonic oxide, poisoning by..... 299
Carditis 76
Cerebral arteries..... 59
Cerebritis 48
Cerebro spinal meningitis..... 61
Chest, examination of..... 65
Children, new-born, medico-legal question relating to..... 307
Chloride of zinc, preservative properties of..... 321
Colon, removal of..... 128
Corrosive sublimate, poisoning by 298
preservative properties of..... 321
Cystitis..... 210

Death, signs of, previous to putrefaction 312
probable cause of 317
Diphtheria, false membranes in.. 71
Disinfectants for instruments..... 24
Dropsy of abdomen 135
of brain..... 40
of chest..... 103
of heart..... 74
of ovaries 248
of testes..... 222
Drowning, death from.....302, 309
Duodenum, removal of..... 129
Dura mater, inflammation of...36, 61
fibrinous clots in..... 37
Dura mater, thickening of..... 37
tubercular deposits in..... 38
tumors in..... 38

Ear, examination of..... 31
removal of..... 29
Embalming, method of, by ancients..... 320
objects of..... 321
instruments required 323
the operation..... 324
changes resulting from 325
Embolism of cerebral arteries..... 59
Endocarditis..... 77
Enteritis..... 149
Epididymitis 221
Epispadias.....212, 215
Exostoses..... 263
Eyes, removal of..... 32

Fallopian tubes, anomalies of..... 251
inflammation of..... 251
morbid growths in.. 251
Fistula in ani..... 157
Fractures, ante-mortem distinguished from post-mortem..... 318

Ganglions 270
Gall-bladder and ducts..... 187
cancer of..... 188
dilatation of..... 188
gall-stones in..... 189
inflammation of..... 187
tumors in 188
tubercles in..... 188
Gastritis 141
catarrhal..... 141
croupous..... 141
phlegmonous..... 141
Gums, examination of..... 65
Gun-shot wounds, ante-mortem distinguished from post-mortem..... 318

Hanging, death from.....301, 319
Hæmatocele 223
Hæmoptysis..... 114
Hæmorrhage, pulmonary..... 114
uterine 237
Hæmorrhoids..... 157
Head, caries of bones of..... 35
examination of..... 27
removal of membranes of brain..... 28
removal of calvarium..... 28
removal of brain..... 29
thickening of bones of..... 35
thinning of bones of..... 35

Heart, atrophy of..... 82
abscess of..... 86
aneurism of..... 86
cancers in..... 84
displacements of..... 87
dilatation of..... 80
ectopia cordis..... 88
examination of.....66, 75
fatty degeneration of..... 82
fatty growth of..... 82
hydatids in..... 86
hypertrophy of..... 79
inflammation of..... 76
melanosis of..... 84
malformations of..... 86
morbid condition of..... 75
normal size of..... 80
ossification of arteries of.. 85
rupture of walls of..... 87
stenosis of..... 79
tumors in..... 84
transposition of..... 88
valves of..... 77
Heart clots, causes of..... 91
color of..... 89
consistency of..... 89
time of formation of. 90
position of..... 89
Hepatitis..... 168
Hernia..... 154
Hydrarthrosis..... 268
Hydrothorax..... 104
Hydrocele..... 222
congenital..... 222
diffused..... 223
encysted..... 222
simple..... 222
Hypospadias.....212, 215
Hydrocyanic acid, poisoning by.. 298

Instruments..... 21
disinfectants for..... 24
Intestines, cancer of..... 158
contraction of..... 153
dilatation of..... 153
displacement of..... 154
examination of..... 149
inflammation of..... 150
incarceration of..... 155
malformations of..... 149
obstructions of....155, 156
parasites in..... 159
rupture of..... 157
tubercles in..... 158
tumors in..... 158
ulceration of..... 152
wounds of..... 157
Intussusception..... 156

Joints, bursæ of, morbid conditions of..... 269
Joints, cartilage of, morbid conditions of..... 270
inflammation of synovial membrane..... 268
malformations of..... 268
rheumatic inflammation of..... 271
scrofulous inflammation of..... 271

Kidneys, anomalies of..... 194
abscesses of..... 196
Bright's disease of..... 197
congestion of..... 194
cancer of..... 204
cysts in..... 204
dislocation of..... 203
examination of..... 193
fatty degeneration of... 202
hæmorrhage of..... 195
inflammation of..... 195
inflammation of capsule of..... 197
parasites in..... 205
removal of..... 129
size and weight of..... 193
tubercles in..... 203

Larynx, abscesses of..... 71
examination of.....64, 65, 69
false membranes in..... 71
inflammation of..... 69
necrosis of cartilages of. 70
œdema of..... 70
tumors of..... 71
ulceration of..... 70
Liver, abscess of.....169, 171
atrophy of..... 174
blood-vessels of..... 182
congestion of..... 166
cancer of..... 177
degenerations of..... 171
examination of.....130, 165
effusion hæmorrhagic of... 167
fatty..... 172
hypertrophy of..... 177
inflammation of..... 168
parasites in.....183, 186
removal of..... 130
size of..... 165
tubercles in..... 181
tumors in..... 182
Lungs, appearance in health..... 107
appearance, post-mortem 118, 120
abscess of..... 111
apoplexy of..... 115
congestion of..... 107
cancer of..... 120
examination of.....67, 106
emphysema of..... 116

Lungs, gangrene of..... 112
hepatization of..... 108
hæmorrhage of..... 114
hydatids in..... 122
inflammation of.....107, 109
melanosis of..... 121
suppuration of..... 110
tubercles in..... 117
tubercular cavities in..... 119
tumors in..... 122

Mammæ, anomalies of..... 252
atrophy of..... 252
abscesses of..... 253
cancer of.....256, 257
examination of..... 252
inflammation of..... 253
tumors in 254
ulcers in 254
Medico-legal questions..... 304
external inspection of body..... 305
internal examination... 306
Mediastinum, abscess of..... 126
cancerous growths in 126
inflammation of... 126
tumors of..... 126
Medulla, spinalis..... 62
oblongata, effusions in 43
of bone, disease of..... 267
Membranes of the brain.
appearance of, in meningitis 39
examination of..... 36
morbid changes of, in insanity..... 40
removal of..... 28
serous effusion into.. 40
sanguineous effusion into..... 41
Membranes, spinal, tuberculous deposits in..... 61
tumors in..... 61
Meningitis..... 39
cerebro spinal..... 61
tubercular..... 38
Metritis.....237, 242
Metrophlebitis..... 243
Morbus Brightii..... 197
Mouth, catarrhal or croupous inflammation of..... 72
examination of..... 64
Myelitis 62
Müller's fluid..... 329

Neck, examination of..... 64
Nephritis..... 195
Nitric acid, poisoning by..... 295
Nux vomica, poisoning by..... 299

Œsophagus, cancer of 73
dilatation of..... 73
examination of..... 72
inflammation of..... 72
stricture of 72
tumors in..... 73
ulceration of..... 72
Opium, poisoning by..... 300
Orchitis..... 221
Osseous growths..... 263
Osteomalacia..... 262
Osteophytes 263
Ovaries, abscesses in 247
cysts in..... 248
dropsy of..... 248
examination of..... 247
inflammation of..... 247
malignant disease of..... 250
tumors, tubercles, etc., of..... 251
Oxalic acid, poisoning by..... 295

Palate, examination of 65
Pacchionian bodies..... 39
atrophy of..... 161
Pancreas, anomalies of..... 160
cancer of 161
dilatation of ducts..... 161
examination of..... 160
fatty degeneration of.. 161
hypertrophy of..... 161
inflammation of..... 161
removal of..... 129
Parasites in bladder..... 212
in brain 57
in heart 86
in intestines 159
in kidneys..... 205
in liver.....183, 186
in lungs..... 122
in spinal cord..... 63
Pelvic viscera, removal of..... 130
Penis, anomalies of..... 215
atrophy of 215
balanitis of..... 216
chancres on..... 216
cancer of..... 217
examination of..... 215
fracture of..... 216
hypertrophy of..... 215
herpes of..... 216
paraphymosis of..... 216
psoriasis of prepuce..... 216
tumors of..... 218
warts on..... 217
Pericardium, adhesions in..... 74
blood in..... 74
examination of..... 73
inflammation of.... 73
morbid growths in 75

Peritoneum, blood in result of violence..... 135
congestion of..... 133
cancer of..... 136
dropsical accumulation in..... 135
exudation, fibrinous, on..... 134
examination of..... 133
gangrene of..... 135
inflammation of..... 133
suppuration of..... 135
tubercular deposits in..... 136
tumors of..... 136
Peritonitis..... 133
puerperal..... 243
Peribepatitis..... 167
Peripractitis..... 151
Perityphlitis..... 151
Pharynx, examination of.....65, 72
inflammation of..... 72
tumors in..... 73
ulceration of..... 72
Phosphorus, poisoning by..... 296
Pia mater, examination of..... 38
inflammation of, in spotted fever..... 61
Pleura, adhesions in..... 103
examination of..... 103
effusions into..... 103
inflammation of..... 103
Pleurisy..... 103
Pneumonia, catarrhal..... 109
croupous..... 110
double..... 109
lobular..... 110
single..... 109
Pneumothorax..... 105
Poisoning, death from..... 294
Post-mortem examinations..... 24
preliminary preparations for... 24
in medico-legal cases..... 304
Pregnancy, abdominal..... 244
extra uterine..... 244
tubal..... 245
utero-tubal..... 245
Preparation of bones..... 329
by boiling..... 329
by maceration..... 329
bleaching of..... 330
Preservation of specimens of morbid anatomy..... 326
process of Dr. Brunetti..... 328
Prolapsus of rectum..... 157
Prostate gland, anomalies of..... 227
atrophy of..... 228
cancer of..... 228
cysts in..... 228
Prostate gland, concretions in.... 229
examination of..... 226
hypertrophy of..... 227
tubercles in..... 228
tumors in..... 228
anomalies of..... 230
Pudenda, examination of..... 230
elephantiasis of..... 232
hypertrophy of..... 230
inflammation of..... 231
tubercles in..... 232
tumors in..... 232
warty excrescences on. 231
Putrefaction, process of..... 314
Pyelitis..... 196
Pyelonephritis..... 196

Questions relating to new-born children..... 307
was the child mature? 307
was it born alive?..... 308
how long did it live?.. 310
what was the cause of death?..... 311

Rachitis..... 261
Rectum, prolapsus of..... 157
removal of..... 128

Sclerosis of spinal cord..... 62
Scrotum, cancer of..... 219
examination of..... 218
elephantiasis of..... 218
hypertrophy of..... 218
inflammation of..... 219
Seminal vesicles, anomalies of.... 226
examination of..... 226
inflammation of..... 226
tubercles in..... 227
Signs of death..... 312
Skull, caries of bones of..... 35
examination of..... 34
fracture of..... 34
thinning of bones of..... 35
thickening of bones of..... 35
Spinal cord, atrophy of..... 63
examination of..... 60
inflammation of membranes of..... 60
morbid growths in..... 63
parasites in..... 63
preservation of specimens of..... 33
removal of..... 33
softening of..... 62
Spinal column, disease of..... 272
Spinal canal, serous effusions in.. 61
Spina bifida..... 61
Spleen, anomalies of..... 162
atrophy of..... 162
cysts in..... 165

Spleen, cancer of..... 165
displacements of..... 163
degeneration of..... 164
examination of..... 162
hypertrophy of..... 162
inflammation of..... 163
removal of..... 129
rupture of..... 163
size of, normal and abnormal..... 162
thickening of capsules of..... 164
tubercles in..... 164
Spotted fever, inflammation of pia mater in..... 61
Stomach, atrophy of..... 145
Beaumont's experiments on..... 140
cirrhosis of..... 144
cancer of..... 146
cancer in, results of..... 148
dilatation of..... 145
examination of..... 137
erosions, hæmorrhagic, of..... 143
inflammation of..... 140
post-mortem changes in..... 137
poisons in, and their effects..... 142
softening of..... 143
tumors in..... 148
ulcers in..... 142
Strangling, death from..... 301
Strychnia, poisoning by..... 299
Suffocation, death from..... 300
Sulphuric acid, poisoning by..... 294
Suprarenal capsules..... 207
cancer of..... 208
cysts in..... 208
hæmorrhage of..... 208
inflammation of..... 207
tubercles in..... 208

Testicles, atrophy of..... 220
anomalies of..... 219
cancer of..... 224
cystic disease of..... 225
dropsy of..... 222
examination of..... 219
hæmatocele of..... 223
hypertrophy of..... 220
inflammation of..... 221
tubercles in..... 225
tumors in..... 226
varicocele of..... 223
Teeth, examination of..... 65
Throttling, death from..... 301
Thrombi in sinuses of dura mater..... 37
Tongue, cancer of..... 68
Tongue, examination of..... 68
hypertrophy of..... 69
ranula of..... 68
syphilitic ulcers of..... 68
tubercles of..... 68
tumors of..... 68
Tonsils, catarrhal or croupous inflammation of..... 72
examination of..... 65
Tubercular disease of lungs..... 117
tubercular cavities in..... 119
meningitis..... 38
Tumors, adenoid..... 285
benign..... 274
in brain..... 54
in bones..... 263
in bladder..... 211
classification of..... 274
cystic..... 274
cartilaginous..... 280
carcinomatous..... 288
in dura mater..... 38
fatty..... 279
fibrous..... 279
in Fallopian tubes..... 251
in gall-bladder and ducts..... 188
hydatid..... 277
in heart..... 84
in intestines..... 158
lipomatous..... 279
lymphatic..... 285
in larynx..... 71
in lungs..... 122
in liver..... 182
myxomatous..... 278
myomatous..... 284
malignant..... 286
in mediastinum..... 126
in mammæ..... 254
neuromatous..... 284
osseous..... 281
in œsophagus..... 73
in ovaries..... 251
papillary..... 282
polypoid..... 283
in pharynx..... 73
in pericardium..... 75
in peritoneum..... 136
in pudenda..... 232
in prostate gland..... 228
in penis..... 218
sarcomatous..... 286
in spinal cord..... 63
in stomach..... 148
in tongue..... 68
in testicles..... 226
in uterus..... 238
in vagina..... 234
vascular..... 284

Ureters, cancer of..... 206
cysts in..... 207
defects of..... 205
dilatation of..... 206
inflammation of..... 206
tubercles in..... 207
Urethra, contraction of..... 213
cancer of..... 214
dilatation of..... 213
inflammation of..... 212
malformations of..... 212
rupture of..... 213
stricture of..... 213
tubercles in..... 214
warty growths in..... 213
Uterus, anomalies of..... 235
atrophy of..... 236
cysts in..... 240
cancer in..... 240
examination of..... 235
excrescences, cauliflower, etc..... 241
hæmatometra..... 236
hypertrophy of..... 236
hydrometra..... 236
hæmorrhages of..... 237
inflammation of, 237, 242, 243
malpositions of..... 236
removal of..... 132
rupture of..... 241
tubercles in..... 240
tumors in..... 230
ulcerations of..... 238

Vagina, anomalies of..... 232
dilatation of..... 232
examination of..... 230
gangrene of..... 234
inflammation of..... 233
laxity of..... 232
laceration of..... 232
rigidity of..... 232
rupture of..... 233
stricture of..... 232
tumors of..... 234
Valves of heart, aneurism of..... 79
atrophy of..... 78
calcification of..... 78
contraction of..... 79
thickening of..... 77
Volvulus..... 156
Vulva. (See *Pudenda*).

White swelling..... 271
Wounds, death from..... 317
contused, appearance of..... 317
post-mortem distinguished from ante-mortem..... 317

Zinc, preparation of, for embalming..... 322
quantity of, required..... 322

ERRATA.

On page 21, last line, for "culvarium," read calvarium.

" 25, fifteenth line, for "collodian," read collodion.

" 79, last line, for "that organ," read those organs.

" 93, thirteenth line, for "affords," read afford.

LANE MEDICAL LIBRARY

To avoid fine, this book should be returned on or before the date last stamped below.

AUG 26 1940

JUN 2 1966

J57
T454
1873

Thomas, A. R.
A practical guide for making post-mortem examinations... 5614

NAME | DATE DUE

SEP -2 1940

JUN 2 1966

LANE MEDICAL LIBRARY
300 PASTEUR DRIVE
PALO ALTO, CALIF. 94304